



Diagnostic Radiology Original Research

The Effectiveness of Gelfoam as the Sole and Primary Embolization Agent in the Management of Hemoptysis: A Retrospective Study from a Tertiary Care Center

Abhinandan Ruge¹, Nidhi Kumar¹, Clyde Menezes¹

¹Department of Radio Diagnosis, St. John's Medical College Hospital, Bengaluru, Karnataka, India.



***Corresponding author:**

Abhinandan Ruge,
Department of Radio
Diagnosis, St. John's Medical
College Hospital, Bengaluru,
Karnataka, India.

abhiruge@yahoo.com

Received : 09 September 2020

Accepted : 30 January 2021

Published : 25 February 2021

DOI

10.25259/JCIS_160_2020

Quick Response Code:



ABSTRACT

Objectives: The objective of this study was to evaluate the role of Gelfoam as an effective embolizing agent in patients with hemoptysis presenting to a tertiary care center in developing nations.

Material and Methods: A retrospective analysis of data from 30 patients treated by Interventional radiologist at St. John's Medical College, Bangalore, India, was performed. The study included 22 males (73.3%) and 8 (26.65%) female patients. Gelfoam was used as the sole embolizing agent and arteries with features of abnormal blush and hypertrophy were targeted. Analysis of the etiology, immediate, and short-term outcome and complications, when present, was performed. The median follow-up period was 45 days following an embolization procedure at this center.

Results: A high short-term efficacy was noted following embolization procedures with Gelfoam as the sole agent. Twenty-eight out of 30 procedures were deemed successful, and post-tubercular changes were noted to be the cause for hemoptysis in 23 patients. The high short-term efficacy (93.3%), evidenced by a complete stoppage of hemoptysis, along with a relatively low rate of complications (spinal cord ischemia in only 2.3%), strengthens the position of Gelfoam as the sole embolizing agent in a resource-limited setting.

Conclusion: In an economically constrained setting, Gelfoam proves to be a useful first choice single embolization agent, while polyvinyl alcohol particles coupled with microcatheter systems remain within reach of only those who can afford them.

Keywords: Gelfoam, Embolization, Radiological intervention and microcatheter

INTRODUCTION

Coughing up of blood is a dramatic symptom of lung disease when present clinically, its seriousness compounded by the nature of the underlying pathology causing it. Hemoptysis is the expectoration of blood from the airways or lung parenchyma below the level of the glottis.^[1,2] While several disease conditions have been listed as being capable of causing hemoptysis – pneumonia, inflammation in the lower respiratory system, chronic obstructive pulmonary disease, bronchiectasis, cystic fibrosis and neoplasia in the respiratory tree, and tuberculosis and its sequelae emerge as the leading cause for hemoptysis in resource-limited settings like India.^[1-4] Percutaneous transthoracic needle biopsies of lung masses have also been associated with hemoptysis as a procedure-related complication.^[5] In a case report, pulmonary

This is an open-access article distributed under the terms of the Creative Commons Attribution-Non Commercial-Share Alike 4.0 License, which allows others to remix, tweak, and build upon the work non-commercially, as long as the author is credited and the new creations are licensed under the identical terms.

©2020 Published by Scientific Scholar on behalf of Journal of Clinical Imaging Science

actinomycosis has been documented as a cause for recurrent hemoptysis,^[6] while fistulous communication between the aorta and tracheobronchial tree can also result in large volume, life-threatening hemoptysis.^[7] Hemoptysis is termed life-threatening when the volume of blood is clinically large enough to bring about respiratory compromise. An 80% mortality rate is associated with life-threatening hemoptysis related mainly to asphyxiation.^[8]

Diagnosing the source of bleeding

Hemoptysis most commonly occurs from the bronchial artery and its branches with non-bronchial systemic (NBS) arteries being involved mainly by tubercular etiology.^[9,10] Multidetector computed tomography (CT) enabled CT angiography is the imaging modality preferred for the diagnosis of hemoptysis. It enables relatively accurate localization of the source of hemorrhage – bronchial or NBS vessels, provides information about the number and origin of the arteries, and also allows evaluation of the etiology of hemoptysis.^[11,12]

Embolization and embolizing agents

Bronchial or NBS vessel embolization has become a safe and effective method in tackling potentially catastrophic hemorrhage in addition to negotiating the morbidity associated with open surgical procedures to check hemorrhage.^[11-14] The embolization of the bleeding vessel is carried out by first obtaining access into the arterial system through the femoral artery. Usually, 5 Fr sheath is commonly used through which either Cobra or Simmons catheters were used. The bronchial arteries are cannulated, and a selective arteriogram (ideally digital subtraction angiography) is then performed.^[15] Low to iso-osmolar non-ionic contrast agents are preferred as ionic agents are associated with a higher incidence of transverse myelitis.^[14]

Vascular hypertrophy and tortuosity, hypervascularity, aneurysm formation, neovascularity, and shunting (bronchial artery to the pulmonary vein or bronchial artery to pulmonary artery) seen on initial arteriography indicate the source of bleeding. These initial angiographic runs can be used as roadmaps during definitive embolization later. It is essential to identify the artery of Adamkiewicz (with its typical hairpin configuration), when present, as accidental blockage of the artery results in catastrophic neurological deficits.^[14,15]

A variety of embolization agents are available – polyvinyl alcohol (PVA) (PVA particle with diameters ranging from 250 to 500 microns), microspheres (500–700 microns), n-butyl-2-cyanoacrylate, ethylene vinyl alcohol polymer, Gelfoam, and Gelfoam in combination with micro coils.^[14-19] Superselective embolization is carried out using microcatheters passed into the larger catheter in a coaxial fashion.

MATERIAL AND METHODS

Embolization using Gelfoam-experiences at this center

A trained interventional radiologist performed all embolization procedures in the hospital catheterization laboratory. Arterial access was gained through a femoral puncture. Preliminary descending thoracic aortogram provided useful information regarding bronchial artery origins and anatomy. The cobra-type curved catheters/Simmons catheters were used for selective catheterization of the bronchial artery.

Once the bronchial artery was selectively catheterized, an angiogram was performed, which enabled the detection of the bleeding vessel and localization of the artery of Adamkiewicz. Digital subtraction images were obtained after the injection of iodinated contrast. Abnormal vascularity was identified in the form of the presence of hypertrophied vessels, abnormal vascular blush, areas of arteriovenous shunting, and foci of active extravasation.

Gelfoam powder was mixed with dilute iodinated contrast and injected as a slurry without the need for a microcatheter. The commonly embolized arteries included the bronchial arteries, intercostal arteries, and lateral thoracic artery branches. Embolization was discontinued with early signs of reflux or stasis. All the patients were then observed in a surgical or respiratory care unit for a minimum period of 24–48 h for immediate control of the bleeding post-procedure and recurrence or any complication.

RESULTS

On immediate follow-up (within 48 h post-procedure), total cessation of hemoptysis was achieved in 27 patients. Partial response with regression in hemoptysis was noted in 3 patients, which slowly improved with medical management [Table 1]. A single major complication was noted, where a patient developed paraparesis following the interventional procedure due to spinal cord ischemia. Care had been taken to avoid the artery Adamkiewicz and the other spinal arteries; however, spinal ischemia could have been caused by the opening of the spinal collateral during the process of embolization. The weakness, however, was transient, and the patient gradually improved with physiotherapy and medical management and regained Grade 4 power around 3 weeks after the procedure. Other minor complications noted were chest discomfort (12) and puncture site hematoma (1).

Repeat bronchial artery embolization (BAE) was required in one patient due to the opening of a prominent feeder, leading to recurrence of significant hemoptysis (this occurred 2 weeks following the procedure) [Figure 1]. It was necessary to

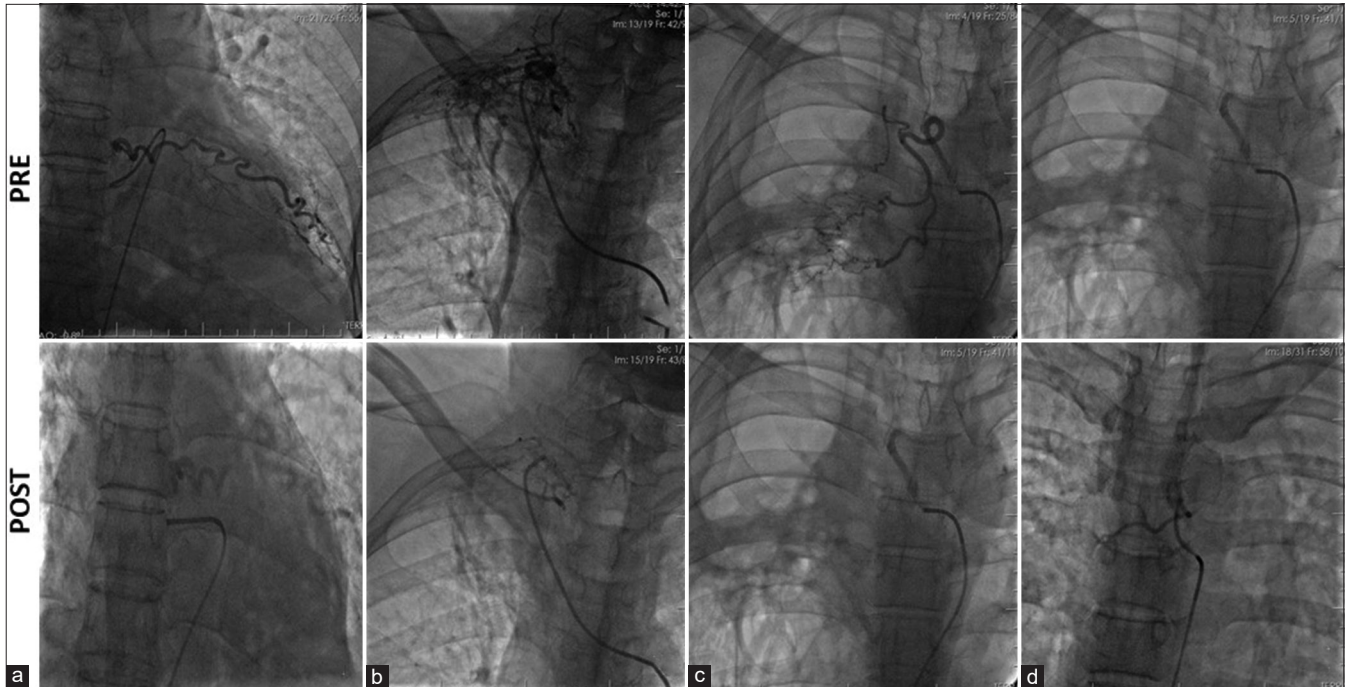


Figure 1: (a-d) Selective bronchial artery angiograms showing a dilated right bronchial artery with abnormal hypervascularity and tortuosity.

Table 1: Clinical outcomes of our study in comparison to previous studies.

Year	Study	Number of patients	Immediate control (%)
1977	Remy <i>et al.</i> ^[18]	104	84
1996	Ramakantan <i>et al.</i> ^[19]	140	73
1999	Mohan <i>et al.</i> ^[20]	45	97.7
2018	Study of our centre	30	90

undertake a second embolization procedure for the patient; embolization was carried out using PVA particles with no further episodes of bleeding following the second procedure.

DISCUSSION

Near-complete control of hemoptysis was achieved in 27 patients (90%) following BAE. We compared our data with other prominently cited published literature regarding the BAE with gel foam that focused on the immediate bleeding control rate. The immediate success rates were lower up to the year 2000 (generally <90%). Higher success rates following this could be attributed to newer advances in medical therapy and the availability of better catheter and the cath-lab systems.

The complication rates, as seen in these studies, have generally shown a declining trend over the years.^[20-22] Our study had one major complication in the form of spinal cord ischemia leading to transient paraparesis. Other minor complications

were chest discomfort and puncture site hematoma. Repeat BAE was required in a patient due to the opening up of a prominent feeder, leading to recurrence of significant bleed 2 weeks following the procedure. Overall, these results show an excellent safety profile of the procedure with a low incidence of clinically significant complications.

Limitations

The present study was a retrospective one from a single center with follow-up carried out for a maximum period of only 3 months.

CONCLUSION

The study reiterates BAE to be an effective technique to control acute, life-threatening hemoptysis. Previous studies have concluded that PVA is preferred over Gelfoam, with Gelfoam even being recommended as a supplementary agent following embolization with PVA due to its temporary occlusive effect. It is imperative still to note that the requirement of a microcatheter system for use with PVA particles coupled with the higher cost of the particles itself raises the financial burden of an embolization procedure. Considering the majority of patients with hemoptysis due to tuberculosis belong to lower strata of society, and expensive embolization procedures may not be within reach of those in greatest need. With a high percentage of complete occlusion of target vessels following initial embolization and low risk of major complications resulting from non-target embolization,

as noted in this study, Gelfoam may even be considered as a sole and primary embolization agent in developing nations like India where embolization with PVA particles or embospheres is still reserved for the privileged.

REFERENCES

1. Prutsky G, Domecq JP, Salazar CA, Accinelli R. Antifibrinolytic therapy to reduce haemoptysis from any cause. *Cochrane Database Syst Rev* 2016;11:CD008711.
2. Earwood JS, Thompson TD. Hemoptysis: Evaluation and management. *Am Fam Physician* 2015;91:243-9.
3. Cordovilla R, de Miguel EB, Ares AN, Povedano FJ, Ortega IH, Merchán RJ. Diagnosis and treatment of hemoptysis. *Arch Bronconeumol* 2016;52:368-77.
4. Mishra A, Mathur A, Pathak K, Katoch CD, Khera A. Bronchial artery embolization in treatment of hemoptysis: Treatment efficacy and complications at a tertiary care chest centre. *Med J Armed Forces India* 2018;74:352-7.
5. Kim H, Kwon D, Yoon SH, Kim H, Park CM, Goo JM, *et al.* Bronchovascular injury associated with clinically significant hemoptysis after CT-guided core biopsy of the lung: Radiologic and histopathologic analysis. *PLoS One* 2018;13:e0204064.
6. Suzuki M, Araki K, Matsubayashi S, Kobayashi K, Morino E, Takasaki J, *et al.* A case of recurrent hemoptysis caused by pulmonary actinomycosis diagnosed using transbronchial lung biopsy after bronchial artery embolism and a brief review of the literature. *Ann Transl Med* 2019;7:108.
7. MacIntosh EL, Parrott JC, Unruh HW. Fistulas between the aorta and tracheobronchial tree. *Ann Thorac Surg* 1991;51:515-9.
8. Ponnuswamy I, Sankaravadevelu ST, Maduraimuthu P, Natarajan K, Sathyanathan BP, Sadras S. 64-detector row CT evaluation of bronchial and non-bronchial systemic arteries in life-threatening haemoptysis. *Br J Radiol* 2012;85:e666-72.
9. Martínez IM, Rodrigo AJ, Sánchez MJ, Pérez AB, Tascón AD, Cabrero TH, De Gracia MM. Are there Predictors of Embolization in Patients with Hemoptysis? *European Congress of Radiology*; 2019.
10. Lee JH, Kwon SY, Yoon HI, Yoon CJ, Lee KW, Kang SG, *et al.* Haemoptysis due to chronic tuberculosis vs. bronchiectasis: Comparison of long-term outcome of arterial embolisation. *Int J Tuberc Lung Dis* 2007;11:781-7.
11. Itrich H, Klose H, Adam G. Radiologic management of haemoptysis: Diagnostic and interventional bronchial arterial embolisation. *Rofo* 2015;187:248-59.
12. Le HY, Pham NH, Phung AT, Nguyen TT, Do Q. Value of multidetector computed tomography angiography before bronchial artery embolization in hemoptysis management and early recurrence prediction: A prospective study. *BMC Pulm Med* 2020;20:1-0.
13. Miyano Y, Kanzaki M, Onuki T. Bronchial artery embolization: First-line option for managing massive hemoptysis. *Asian Cardiovasc Thorac Ann* 2017;25:618-22.
14. Sopko DR, Smith TP. Bronchial artery embolization for hemoptysis. *Semin Intervent Radiol* 2011;28:48-62.
15. Burke CT, Mauro MA. Bronchial artery embolization. *Semin Intervent Radiol* 2004;21:43-8.
16. Han K, Yoon KW, Kim JH, Kim GM. Bronchial artery embolization for hemoptysis in primary lung cancer: A retrospective review of 84 patients. *J Vasc Interv Radiol* 2019;30:428-34.
17. White RI Jr. Bronchial artery embolotherapy for control of acute hemoptysis: Analysis of outcome. *Chest* 1999;115:912-5.
18. Rémy J, Arnaud A, Fardou H, Giraud R, Voisin C. Treatment of hemoptysis by embolization of bronchial arteries. *Radiology* 1977;122:33-7.
19. Ramakantan R, Bandekar VG, Gandhi MS, Aulakh BG, Deshmukh HL. Massive hemoptysis due to pulmonary tuberculosis: Control with bronchial artery embolization. *Radiology* 1996;200:691-4.
20. Mohan C, Sangameswaran KV, Prasad B, Sabhikhi GS, D'Souza J. Bronchial arteriography and transcatheter embolization in management of severe haemoptysis. *Med J Armed Forces India* 1999;55:189-92.
21. Hahn S, Kim YJ, Kwon W, Cha SW, Lee WY. Comparison of the effectiveness of embolic agents for bronchial artery embolization: Gelfoam versus polyvinyl alcohol. *Korean J Radiol* 2010;11:542-6.
22. Yoon W. Embolic agents used for bronchial artery embolisation in massive haemoptysis. *Expert Opin Pharmacother* 2004;5:361-7.

How to cite this article: Ruge A, Kumar N, Menezes C. The effectiveness of Gelfoam as the sole and primary embolization agent in the management of hemoptysis: A retrospective study from a Tertiary Care Center. *J Clin Imaging Sci* 2021;11:10.