



Review Article *Vascular and Interventional Radiology*

## Transjugular intrahepatic portosystemic shunt for pediatric portal hypertension: A meta-analysis

Driss Raissi<sup>1</sup>, Sneh Brahmhatt<sup>1</sup>, Qian Yu<sup>1</sup>, Lan Jiang<sup>2</sup>, Chenyu Liu<sup>3</sup>

<sup>1</sup>Department of Radiology, Medicine and Obstetrics and Gynecology, University of Kentucky, College of Medicine, Lexington, <sup>2</sup>Department of Pediatrics, The Children's Hospital at Montefiore, Bronx, New York, <sup>3</sup>School of Medicine, George Washington University, Washington, United States.



**\*Corresponding author:**

Driss Raissi,  
Department of Radiology,  
Medicine and Obstetrics and  
Gynecology, University of  
Kentucky, College of Medicine,  
Lexington, United States.

driss.raissi@uky.edu

Received : 04 April 2023

Accepted : 08 June 2023

Published : 26 June 2023

**DOI**

10.25259/JCIS\_36\_2023

**Quick Response Code:**



### ABSTRACT

To evaluate the feasibility of transjugular intrahepatic portosystemic shunt (TIPS) in children with portal hypertensive complications, PubMed and Cochrane Library were queried to identify clinical studies evaluating TIPS in patients <18 years old. Baseline clinical characteristics, laboratory values, and clinical outcomes were extracted. Eleven observational studies totaling 198 subjects were included in the study. The pooled technical success rate and hemodynamic success rate were 94% (95% confidence interval [CI]: 86–99%) and 91% (95% CI: 82–97%), respectively; ongoing variceal bleeding resolved in 99.5% (95% CI: 97–100%); refractory ascites was improved in 96% (95% CI: 69–100%); post-TIPS bleeding rate was 14% (95% CI: 1–33%); 88% of patients were alive or successfully received liver transplant (95% CI: 79–96%); and shunt dysfunction rate was 27% (95% CI: 17–38%). Hepatic encephalopathy occurred in 10.6% (21/198), though 85.7% (18/21) resolved with medical management only. In conclusion, based on moderate levels of evidence, TIPS is a safe and effective intervention that should be considered in pediatric patients with portal hypertensive complications. Future comparative studies are warranted.

**Keywords:** Children, Interventional radiology, Stent, Variceal bleed, Ascites

### INTRODUCTION

Transjugular intrahepatic portosystemic shunt (TIPS) is a well-established procedure to treat gastrointestinal bleeding (GIB) and refractory ascites in adults with portal hypertension (pHTN) secondary to cirrhosis.<sup>[1,2]</sup> However, evidence supporting the use of TIPS in the pediatric population remains scarce. Surgical shunt is often used in treating medically refractory pHTN in the pediatric population, with pre-hepatic etiology treated with the creation of meso-Rex shunt and intrahepatic etiology treated with surgical portosystemic shunts.<sup>[3,4]</sup> However, compared to TIPS, surgery is a more invasive option in the setting of acute variceal GIB and cannot be applied to every patient due to anatomical and technical limitations.<sup>[5]</sup> TIPS can serve as a bridge to transplant or simply be a palliative treatment if the latter is not an option.

The purpose of this study was to review and characterize the safety and effectiveness of TIPS in the pediatric population by conducting a meta-analysis.

### METHODS

The Cochrane Database and PubMed were queried from the establishment to October 2020 with the following keywords: “Transjugular intrahepatic portosystemic shunt” AND (“child” OR

This is an open-access article distributed under the terms of the Creative Commons Attribution-Non Commercial-Share Alike 4.0 License, which allows others to remix, transform, and build upon the work non-commercially, as long as the author is credited and the new creations are licensed under the identical terms.

©2023 Published by Scientific Scholar on behalf of Journal of Clinical Imaging Science

“pediatric”). The following criteria were adopted: (1) Patients <18 years old received TIPS; (2) sample size  $\geq 5$ ; (3) free full-text available; and (4) studies with original data. The following data were extracted by two researchers: study name, year of publication, region, patient number, sex, age, indication of TIPS, pHTN etiology, TIPS stent type, laboratory values, technical success, hemodynamic success, immediate clinical success, post-TIPS bleeding rate, survival/mortality, shunt patency, and complications. Any disagreement was resolved through discussion. The following terms are defined:

- Technical success: successful placement of TIPS
- Hemodynamic success: reduction of portosystemic gradient (PSG) <12 mmHg
- Immediate clinical success: resolution of ongoing-GIB or improvement of existing ascites
- Post-TIPS bleeding: recurrence of or *de novo* GIB after successful TIPS placement
- Survival: successful bridging to transplant or alive with native liver at follow-up
- Shunt-dysfunction: shunt stenosis or thrombosis requiring intervention to maintain patency.

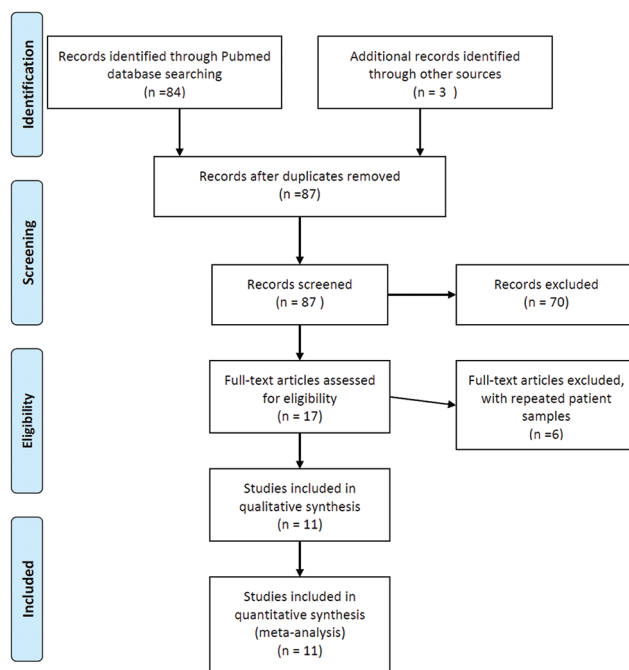
Statistical analysis was performed with STATA 15.1 (STATA Corp., College Station, TX). Pooled analysis was conducted with the `metaprop_one` function. A random-effects model was used. Technical success, hemodynamic success, immediate clinical success, post-TIPS bleeding rate, survival, and shunt dysfunction were reported with a 95% confidence interval (CI).

## RESULTS

Among the initial 236 search results, 11 unique studies published from 1997 to 2019 were included in the meta-analysis.<sup>[6-16]</sup> [Figure 1] Of note, for studies with repeated patient samples, the most recent study was included in the study; Slowik *et al.* have included instead of Bertino *et al.*, because the latter did not report outcomes of the pediatric subgroup (age<18) separately.<sup>[6,17]</sup> The majority of published studies were conducted in the US and Europe; only two studies were from Asia [Table 1].

A total of 198 pediatric patients underwent the TIPS procedure, and 49.1% were female in reported studies (79/161). The median age of included patients was 10.3 years, ranging from 0.5 years to 17.9 years and the median weight was 30 kg, ranging from 6.4 kg to 90.6 kg. The patient characteristics of individual study are reported in [Table 1].

Biliary atresia is the most common etiology 21% (Table 2, 42/198). TIPS placement was technically successful in 94% of cases (Figure 2a, 95% confidence interval [CI]: 86–99%). The mean PSG before TIPS was 20.9 mmHg and the mean post-PSG was 9.7 mmHg with each study listed in [Table 2]. In 91% of all cases, PSG was successfully reduced to <12 mmHg



**Figure 1:** Literature search and screening process.

(Figure 2b, 95% CI: 82–97%). Ongoing GIB resolved in 99.5% of patients after TIPS (Figure 2c, 95% CI: 97–100%), whereas refractory ascites improved in 96% of patients (Figure 2c, 95% CI: 69–100%). GIB occurred in 1 of 4% patients after TIPS placement (Figure 2d, 95% CI: 1–33%). With a mean/median follow-up ranging from 135 days to 12.5 years, the survival rate was 88% (Figure 2e, 95% CI: 79–96%). Among a total of 148 patients that survived, 32.4% ( $n = 48$ ) underwent liver transplant, with the rest of the patients surviving with their native liver. Shunt dysfunction occurred in 27% of the cases (Figure 2f, 95% CI: 17–38%) with a median time to reintervention of 14 months for non-acute shunt dysfunction (ranges 24 days to 10 years).<sup>[7-10,12,15,16]</sup> The reported rate of acute shunt dysfunction occurring within the first 48 h is 3.8% (3/78).

Whereas earlier studies only used bare metal stents, both covered and non-covered stents were used in more recent studies. Viatorr (Gore, USA/UK) and Wallstent (Boston Scientific, USA/Schneider, UK) were the most commonly used stents [Table 2]. In terms of complications, hepatic encephalopathy (HE) was the most frequent, observed in 10.6% of patients ( $n = 21$ ). The majority of patients ( $n = 18$ ) with HE were treated successfully with medical management. Two HE patients reported in Johansen *et al.* were refractory to medical treatment, and one of them required staged closure of TIPS to relieve symptoms. Other etiologies included hemoperitoneum ( $n = 2$ ), capsular hematoma ( $n = 2$ ), bile leak ( $n = 1$ ), arteriovenous fistula ( $n = 1$ ), and endotipisitis ( $n = 1$ ). Platelet count, spleen size, albumin, blood ammonia,

**Table 1:** Included studies and patient characteristics.

No. Study	Study/Year	Region	Pt No. (F:M)	Average age in years (range)	Average weight in kg (range)
1	Zurera <i>et al.</i> 2015	Spain	12 (3:9)	9 (2–16)	30 (11–60)
2	Sharma <i>et al.</i> 2016	India	14 (6:8)	5.4 (0.5–17.8)	N/A
3	Lv <i>et al.</i> 2015	China	17 (7:10)	12.3 (7.1–17.9)	33 (19–55)
4	Johansen <i>et al.</i> 2018	UK	40 (20:20)	10.7 (0.6–17.2)	38.3 (6.4–77.9)
5	Hackworth <i>et al.</i> 1997	USA	12 (6:6)	9.5 (2.4–16.8)	34.14 (13.9–80.9)
6	Ghannam <i>et al.</i> 2018	USA	21 (9:12)	12.1 (2–17)	N/A
7	Di Giorgio <i>et al.</i> 2019	Italy	27	10.3	36.7
8	Slowik <i>et al.</i> 2019	USA	31 (20:11)	11.5 (1–17)	39.4 (11.8–90.6)
9	Huppert <i>et al.</i> 2002	Germany	9	8.1 (2.8–12.6)	NA
10	Heyman <i>et al.</i> 1997	USA	9 (5:4)	9.4 (5–15)	31.2 (16–70)
11	Verbeeck <i>et al.</i> 2018	Belgium	5 (3:2)	9.2 (4.7–14.3)	33.3 (16–77.4)

N/R: Not reported, Pt: Patient number, No.: Number

and total bilirubin were also reported by selected studies [Table 3].

## DISCUSSION

### What is known

- TIPSs are a well-established procedure commonly used in adults with pHTN to treat variceal GIB and refractory ascites
- TIPS has been shown to be feasible in children in small retrospective cohort studies.

### What is new

- Our study demonstrates that TIPS is effective in achieving immediate clinical success and preventing future variceal bleeding in children
- The risk of medically refractory HE is minimal
- Our study shows the need for high-quality comparative studies of TIPS versus surgical bypass in the pediatric population.

Complications of pHTN can range from variceal bleeding, ascites to hepatorenal syndrome and thrombocytopenia.<sup>[2]</sup> There are two main categories behind the etiology of pHTN, intrahepatic and extrahepatic, with the former being the most common type in children.<sup>[3]</sup> The present meta-analysis covered a variety of primary diagnoses, such as biliary atresia, cystic fibrosis, congenital hepatic fibrosis, and Budd-Chiari syndrome [Table 1]. TIPS is a well-validated percutaneous intervention that can alleviate pHTN-related complications through the creation of a decompressive shunt between the portal venous and systemic venous systems.<sup>[2]</sup> Despite TIPS being standard-of-care in selected adult patients, there is limited evidence supporting its use in pediatric patients. Based on 11 retrospective cohorts, the present meta-analysis showed that TIPS is technically feasible and effective for managing pHTN in children.

Similar to the adult population, the most commonly encountered indications in the present meta-analysis were variceal bleeding and refractory ascites [Table 1]. All included patients with ongoing or recurrent variceal bleeding had already failed conservative medical and endoscopic management. In the acute setting, TIPS achieved nearly 100% immediate hemostatic success rate [Figure 2c]. Among the two patients who had continued variceal bleeding and hemoperitoneum post-TIPS, one patient was a 6-year-old female with biliary atresia who received a liver transplant on post-TIPS day 3, while the other patient was a 15-year-old male with Child-Pugh C cryptogenic cirrhosis with concurrent pulmonary and renal disease who succumbed to multisystem organ failure.<sup>[6,10]</sup> Recurrent or *de novo* GIB occurred in 14% of patients, most secondary to shunt stenosis or thrombosis [Figure 2d]. The cumulative TIPS dysfunction rate was 27%. The primary patency rate was 71–83% and 60–64% at 1 and 2 years, respectively, consistent with reported rates in both pediatric and adult demographic.<sup>[18,19]</sup> The adopted follow-up and surveillance algorithms mirrored those of the adult population: Doppler ultrasound at 1 week and every 3–6 months within the 1<sup>st</sup> year post-TIPS. All reported dysfunctions were successfully managed through standard shunt maintenance without reported complications. While the use of covered versus non-covered stents can affect shunt patency, study-level subgroup analysis of such matter was not possible, as most individual studies included both types of stents.

According to Trebicka *et al.*, the effectiveness of an 8 mm stent surpasses that of a fully or under dilated 10 mm stent, with no difference in shunt dysfunction rates and significantly lower HE complication rates.<sup>[20,21]</sup> Nonetheless, in younger children, dilating to 8 mm may still be too wide for successful treatment. Several retrospective studies have revealed positive outcomes resulting from under dilation of PTFE stents measuring up to 8 mm diameter with no accompanying elevations in complication risks.<sup>[22,23]</sup> While

**Table 2:** Baseline characteristics of included studies.

Study	Indication (n)	Stent	Etiology (n)	Stent width, (mm)	Stent dilation, (mm)	Pre PSG (mean±SD)	Post PSG (mean±SD)	Follow-up (Months/ Years)
Zurera et al. 2015	GIB (12)	Viatorr (W.L. Gore and Associates, Flagstaff, AZ)	Biliary atresia (3) Cystic fibrosis (2) Congenital hepatic fibrosis (1) Caroli disease (1) Ductopenia (1) Cirrhosis of unknown origin (1) Liver transplant (1) Thrombosis and cavernomatosis (2)	10	6–10	15.5±5.4	7.5±3.3	Mean: 22 months
Sharma et al. 2016	N/A	N/A	Budd-Chari (14)	NR	NR	23.7±5.5	3.3±1.3	Median: 44 months
Ly et al. 2015	N/A	Fluency Bard, (Karlsruhe, Germany) Smart Cordis, (Miami, FL); Protégé GPS EV3, (Plymouth, MN)	Extrahepatic portal venous obstruction (17)	8–10	8–10	26.4±4.5	10.9±4.3	Median: 36 months
Johansen et al. 2018	GIB (35) Ascites (4) HSP (1)	Viatorr (WL Gore, UK) Wallstent (Schneider, UK)	Biliary atresia (12) Cystic fibrosis (8) Intestinal failure associated liver disease (4) Budd Chiari (3) Autoimmune (3) Drug induced liver injury (2) Cryptogenic (2) Progressive familial intrahepatic cholestasis (2) Others (4)	7–10	6–10	27.7±8.1	19.3±6.7	Mean: 6.2 years
Hackworth et al. 1997	GIB (12) Ascites (2)	Wallstent (Schneider, Minnetonka, Minn).	Congenital hepatic fibrosis biliary atresia Autoimmune hepatitis Post-transplant hepatitis C Chronic allograft rejection Portal angiodysplasia Langerhans cell histiocytosis Alpha-antitrypsin deficiency	5–12	6–12	N/A	N/A	N/A

(Contd...)

**Table 2:** (Continued).

Study	Indication (n)	Stent	Etiology (n)	Stent width, (mm)	Stent dilation, (mm)	Pre PSG (mean±SD)	Post PSG (mean±SD)	Follow-up (Months/ Years)
Ghannam et al. 2018	GIB 20 Ascites (1)	Viatorr (W.L. Gore and Associates, Newark, DE) Wallstent (Boston Scientific, Marlborough, MA) Express (Boston Scientific, Marlborough, MA) iCast (Atrium Medical, Hudson, NH)	Biliary atresia (5) Cryptogenic cirrhosis (4) Porta/hepatic vein thrombosis (4) Polycystic kidney disease (3) Primary sclerosing cholangitis (2) Other (3)	5–12	6–10	18.5±10.7	7.1±3.9	Mean: 65 months (without liver transplant); Mean: 15.9 months (from TIPS placement to liver transplant)
Di Giorgio et al. 2019	GIB (17) Ascites (11)	Viator (W.L. Gore, Flagstaff, AZ) Memotherm (Bard Angiomed Ltd, Crawley, UK)	Biliary atresia (3) Cystic fibrosis (3) Intestinal failure associated liver disease (2) Primary sclerosing cholangitis (1) Intrahepatic cholestasis (1) Liver Transplant (2) Budd Chiari (8) Portal vein thrombosis (5) Ductal plate malformation (3) Hepatoportal sclerosis (1)	8–10	7–8	19.5±6	8±2.5	Median: 12.5 years
Slowik et al. 2019	GIB (26) Ascites (2) Thrombosis (2) Splenic sequestration (1)	N/A	Cavernous transformation (6) Congenital fibrosis (4) Biliary atresia (5) Cystic Fibrosis (3) Nodular regenerative hyperplasia (1) Zellweger syndrome (1) Autoimmune hepatitis (2) Primary sclerosing cholangitis (1) Fibrotic liver disease of unknown etiology (1) Veno-occlusive (1) Berardinelli-Seip syndrome (1) Chronic rejection of liver transplant (1)	6–10	6–10	14.5±4.9	4.3±2.7	Mean: 24 months

(Contd...)

**Table 2:** (Continued).

Study	Indication (n)	Stent	Etiology (n)	Stent width, (mm)	Stent dilation, (mm)	Pre PSG (mean±SD)	Post PSG (mean±SD)	Follow-up (Months/ Years)
Huppert et al. 2002	GIB (9 one also has ascites)	Wallstent (Schneider, UK) Palmaz Cragg (MinTec, Freeport, Bahamas)	Splanchnic thrombosis of portal venous system (1) Glycogen storage 1b (1) Parenteral nutrition related liver disease (1) Hepatoportal sclerosis (1) Biliary atresia (9)	6–9	NR	17.4±4.6	9.4±2.2	Mean: 69.6 months
Heyman et al. 1997	GIB (7) Hypersplenism (2, with one also has ascites)	Wallstent (Scheider, USA)	Cryptogenic cirrhosis (2) Biliary Atresia (4) Congenital hepatic fibrosis (1) Primary sclerosing cholangitis (1) Coach syndrome (1)	6–8	6–10	N/A	N/A	Mean: 4.5 months
Verbeeck et al. 2018	GIB (5)	Wallstent (Boston Scientific, Natick, MA, USA) Viatorr (WL Goreand Associates, Flagstaff, AZ, USA)	Polycystic kidney disease related liver fibrosis (5)	8	8	17.6±4.4	6±2.9	Mean: 7.2 years


N/R: Not reported, N/A: Not available, GIB: Gastrointestinal bleed, HSP: Henoch-Schonlein purpura, PSG: Porto-systemic gradient, SD: Standard deviation

self-expandable stents can expand spontaneously and progressively which is beneficial especially for pediatric patients due to their rapid growth rate.<sup>[21,23,24]</sup> Schepis et al. indicated that this expansion effect does not occur when an 8 mm PTFE stent is under dilated. Hence, the optimal approach toward mitigating complications associated with these interventions would entail using “controlled-expansion” adjustable-diameter devices that lack inherent post-deployment expansion ability.<sup>[25,26]</sup> It is important to note that selection of stent depends on various other factors and data is not robust concerning the most appropriate diameter for a TIPS stent in a pediatric population.

Refractory ascites was the second most frequent indication among patients of the present study. Whereas 96% of ascites improved after TIPS placement, two patients had persistent

mild symptoms controlled with diuretics. Less commonly, TIPS was performed in four cases to treat hypersplenism, a sequelae of pHTN associated with thrombocytopenia [Table 2]. An increase in platelet count and decreased splenic size was noted in several studies, though it was not consistently statistically significant [Table 3]. Other indications of TIPS, such as hydrothorax and hepatorenal syndrome, were not observed in the present study.

TIPS placement was technically successful in 94% of cases (Figure 2a, 95% CI: 86–99%) which are similar to that reported in adult population.<sup>[27,28]</sup> From a technical perspective, the creation of TIPS in children can be more technically challenging. On the one hand, these pediatric patients have a higher prevalence of hepatic vascular anomalies such as portal venous cavernous transformation and Budd-Chiari



**Figure 2:** Meta-analysis results: (a) technical success, (b) hemodynamic success, (c) immediate clinical success, (d) post-tips gastrointestinal bleeding, (e) post-tips survival, and (f) shunt dysfunction rate.

occlusive venous sequelae.<sup>[9,12]</sup> On the other hand, tools such as the standard TIPS kit were initially designed for adults. The size of the needle used in shunt creation can be rather large for younger and smaller children, leading to

a high risk of iatrogenic trauma (i.e., hemoperitoneum). Tableside modifications of available tools and intravascular ultrasound have been used to increase technical success and minimize risks.<sup>[7,17]</sup> With careful manipulation, TIPS can be

**Table 3:** Laboratory values and complications.

Study/Year	Platelet ( $\times 10^9/L$ )		Spleen size (cm)		Albumin (g/dl)		Ammonia ( $\mu\text{mol/L}$ )		Bilirubin (mg/dL)		Complications (n)
	Pre	Post	Pre	Post	Pre	Post	Pre	Post	Pre	Post	
Zurera et al. 2015	-	-	-	-	-	-	-	-	-	-	Mild HE (1) (resolved with lactulose) – 8.3%
Sharma et al. 2016	-	-	-	-	-	-	-	-	-	-	Hemopericardium with nephropathy (1) Capsular hematoma (1) AV fistula with haemobilia (1) Capsular hematoma (1)
Ly et al. 2015	59.5	75	17.5	19	-	-	-	-	-	-	Capsular hematoma (1)
Johansen et al. 2018	98.3	133.5	16.4	14.6	-	-	50.8	114.6	-	-	HA thrombosis/liver infarction/sepsis, (1) Pseudoaneurysm of HA (1) Bile leak, (1) HE (3) (2 refractory to medical management) – 7.5%
Hackworth et al. 1997	96.4	98.7	-	-	3.4	3.3	-	-	5.1	10.0	HE (1)–managed with lactulose (8.3%) Pulmonary edema resolved with diuretic (1) Access site minor hematoma (1) HE (10)–successfully treated with medication. (47.6%)
Ghannam et al. 2018	-	-	-	-	-	-	-	-	Increased at 2 mo and decreased at 1 year		HE (10)–successfully treated with medication. (47.6%)
Di Giorgio et al. 2019	133	146	16.2	15.5	3.6	3.5	46	69	1.2	2.2	No HE
Slowik et al. 2019	No difference		-	-	No difference		Weak increase		-	-	HE (5)–managed medically (16.1%)
Huppert et al. 2002	81.7	84.4	14	14.8	-	-	91.1	96.9	2.1	3.1	HE (1)–persisted until transplant (11.1%)
Heyman et al. 1997	-	-	-	-	-	-	-	-	-	-	No HE.
Verbeeck et al. 2018	100	154	18.1	15.1	-	-	35	48	-	-	Hemoperitoneum (1) No HE.

HE: Hepatic encephalopathy, AV: Arteriovenous, HA: Hepatic artery

successfully deployed in patients weighing as low as 11 kg.<sup>[7]</sup> An additional consideration is a growth, although this patient population is notorious for predicted growth delay secondary to underlying liver disease. For patients with a predicted TIPS for longer than a year, an under-dilated endoprosthesis can be placed initially (i.e., using an 8 mm balloon to dilate a 10 mm endoprosthesis); based on physiological surveillance, future percutaneous adjustment can then be performed if needed.<sup>[12,15]</sup> Furthermore, because venous thrombosis can be more common in the pediatric population, preprocedural recanalization of the portal vein demands additional technical consideration before TIPS creation.<sup>[7,13]</sup> A variety of techniques may be needed for successful TIPS placement: secondary percutaneous access such as trans-splenic and transhepatic routes may be necessary and direct intrahepatic

portosystemic shunt.<sup>[13]</sup> Nevertheless, operators should be cognizant of underlying pre-procedural hepatic vascular anatomy.

Despite the aforementioned technical challenges, TIPS is a safe procedure in the pediatric population with bleeding-related complications occurring in 2.7% (5/187) of pooled data, which is consistent with reported literature in the adult population.<sup>[29]</sup> In terms of long-term side effects, pediatric patients with pHTN are less likely to develop HE as compared to their adult counterparts (Incidence varies from 15% to 48%), this can be explained by the greater proportion of non-cirrhotic etiologies in children.<sup>[28]</sup> Although the blood ammonia level increased after TIPS placement in multiple studies, only 10.6% (21/198) developed HE. The majority (85.7%, 18/21) resolved with medical management alone.



The present study should be interpreted with caution. First, 10/11 studies are single-arm cohort and case series, which is considered level IV evidence and subject to selection bias. Comparative analyses between TIPS and other options, such as surgery or transplantation, were not performed, whereas its comparison with no TIPS could be difficult to perform for refractory GIB, as precluding a patient from receiving a life-saving intervention would be ethically challenging. Second, the patient population was rather heterogeneous, with a significant variety of primary diagnoses included in the study. Diseases such as Budd-Chiari syndrome are associated with a higher risk of thrombotic events, leading to an increased risk of future shunt dysfunction.<sup>[30]</sup> Yet, subgroup analysis based on each etiology was not possible due to the low quality of available patient-level data. Further, clinical outcomes were rarely reported based on time intervals. For example, TIPS patency and risk of HE likely increases as the follow-up interval increases, but only a few studies analyzed outcomes using Kaplan–Meier curves. In addition, the survival was poorly reported because many studies had a wide range of follow-up duration and did not include the specifics for individual patients. Noteworthy is the fact that the relationship between final PSG and clinical outcomes was not identified. In adults, a post-TIPS final PSG <12 mmHg or <10 mmHg is the recommended endpoint in the treatment of variceal bleeding and an even lower PSG may be needed for ascites management. By contrast, post-TIPS final PSG values remain generally undefined in children. Slowik *et al.* have shown that pediatric patients are still at risk of developing variceal bleeding, using adult PSG standard, while Bertino *et al.* demonstrated that a PSG <12 mmHg may be associated with promising clinical outcomes in the pediatric population.<sup>[6,17]</sup>

## CONCLUSION

TIPS is technically feasible and effective in the treatment of refractory variceal bleeding and ascites in pediatric patients with pHTN, considering its nearly 100% early clinical success rate. In the long term, it is effective in the prevention of variceal bleeding recurrence with minimal risk of developing medically refractory HE. It is an accepted option for bridging to transplant and/or serving as a long-term management strategy for some pHTN complications such as ascites. In addition to comparative study designs of TIPS versus surgical bypass and given the significant underlying heterogeneity in this patient population, future multicenter studies are needed to increase sample size and obtain higher-level evidence in the pediatric population.

## Acknowledgment

The authors' would like special thanks to Chenyu Liu and Lan Jiang for their contribution to our project.

## Declaration of patient consent

Patient's consent not required as patients identity is not disclosed or compromised.

## Financial support and sponsorship

Nil.

## Conflicts of interest

There are no conflicts of interest.

## REFERENCES

- Bai M, Qi X, Yang Z, Yin Z, Nie Y, Yuan S, *et al.* Predictors of hepatic encephalopathy after transjugular intrahepatic portosystemic shunt in cirrhotic patients: A systematic review. *J Gastroenterol Hepatol* 2011;26:943-51.
- Boyer TD, Haskal ZJ; American Association for the Study of Liver Diseases. The role of transjugular intrahepatic portosystemic shunt in the management of portal hypertension. *Hepatology* 2005;41:386-400.
- Young V, Rajeswaran S. Management of portal hypertension in the pediatric population: A primer for the interventional radiologist. *Semin Intervent Radiol* 2018;35:160-4.
- Cortez AR, Kassam AF, Jenkins TM, Nathan CJ, Nathan JD, Alonso MH, *et al.* The role of surgical shunts in the treatment of pediatric portal hypertension. *Surgery* 2019;166:907-13.
- Chiu B, Pillai SB, Sandler AD, Superina RA. Experience with alternate sources of venous inflow in the meso-Rex bypass operation: The coronary and splenic veins. *J Pediatr Surg* 2007;42:1199-202.
- Slowik V, Monroe EJ, Friedman SD, Hsu EK, Horslen S. Pressure gradients, laboratory changes, and outcomes with transjugular intrahepatic portosystemic shunts in pediatric portal hypertension. *Pediatr Transplant* 2019;23:e13387.
- Zurera LJ, Espejo JJ, Lombardo S, Gilbert JJ, Canis M, Ruiz C. Safety and efficacy of expanded polytetrafluoroethylene-covered transjugular intrahepatic portosystemic shunts in children with acute or recurring upper gastrointestinal bleeding. *Pediatr Radiol* 2015;45:422-9.
- Sharma VK, Ranade PR, Marar S, Nabi F, Nagral A. Long-term clinical outcome of Budd-Chiari syndrome in children after radiological intervention. *Eur J Gastroenterol Hepatol* 2016;28:567-75.
- Lv Y, He C, Guo W, Yin Z, Wang J, Zhang B, *et al.* Transjugular intrahepatic portosystemic shunt for extrahepatic portal venous obstruction in children. *J Pediatr Gastroenterol Nutr* 2016;62:233-41.
- Heyman MB, LaBerge JM, Somberg KA, Rosenthal P, Mudge C, Ring EJ, *et al.* Transjugular intrahepatic portosystemic shunts (TIPS) in children. *J Pediatr* 1997;131:914-9.
- Johansen LC, McKiernan PJ, Sharif K, McGuirk SP. Transjugular intrahepatic portosystemic shunt insertion for the management of portal hypertension in children. *J Pediatr Gastroenterol Nutr* 2018;67:173-9.
- Hackworth CA, Leef JA, Rosenblum JD, Whittington PE,

- Millis JM, Alonso EM. Transjugular intrahepatic portosystemic shunt creation in children: Initial clinical experience. *Radiology* 1998;206:109-14.
13. Ghannam JS, Cline MR, Hage AN, Chick JF, Srinivasa RN, Dasika NL, *et al.* Technical success and outcomes in pediatric patients undergoing transjugular intrahepatic portosystemic shunt placement: A 20-year experience. *Pediatr Radiol* 2019;49:128-35.
  14. Di Giorgio A, Nicastro E, Agazzi R, Colusso M, D'Antiga L. Long-term outcome of transjugular intrahepatic portosystemic shunt in children with portal hypertension. *J Pediatr Gastroenterol Nutr* 2020;70:615-22.
  15. Huppert PE, Goffette P, Astfalk W, Sokal EM, Brambs HJ, Schott U, *et al.* Transjugular intrahepatic portosystemic shunts in children with biliary atresia. *Cardiovasc Intervent Radiol* 2002;25:484-93.
  16. Verbeeck S, Mekhali D, Cassiman D, Maleux G, Witters P. Long-term outcome of transjugular intrahepatic portosystemic shunt for portal hypertension in autosomal recessive polycystic kidney disease. *Dig Liver Dis* 2018;50:707-12.
  17. Bertino F, Hawkins CM, Shivaram G, Gill AE, Lungren MP, Reposar A, *et al.* Technical feasibility and clinical effectiveness of transjugular intrahepatic portosystemic shunt creation in pediatric and adolescent patients. *J Vasc Interv Radiol* 2019;30:178-86.e5.
  18. Ling SC. TIPS for kids: Are we at the tipping point? *J Pediatr Gastroenterol Nutr* 2020;70:539.
  19. Bureau C, Pagan JC, Layrargues GP, Metivier S, Bellot P, Perreault P, *et al.* Patency of stents covered with polytetrafluoroethylene in patients treated by transjugular intrahepatic portosystemic shunts: Long-term results of a randomized multicentre study. *Liver Int* 2007;27:742-7.
  20. Wang Q, Lv Y, Bai M, Wang Z, Liu H, He C, *et al.* Eight millimetre covered TIPS does not compromise shunt function but reduces hepatic encephalopathy in preventing variceal re-bleeding. *J Hepatol* 2017;67:508-16.
  21. Trebicka J, Bastgen D, Byrtus J, Praktiknjo M, Terstiegen S, Meyer C, *et al.* Smaller-diameter covered transjugular intrahepatic portosystemic shunt stents are associated with increased survival. *Clin Gastroenterol Hepatol* 2019;17:2793-9.e1.
  22. Liu J, Ma J, Zhou C, Yang C, Huang S, Shi Q, *et al.* Potential benefits of underdilation of 8-mm covered stent in transjugular intrahepatic portosystemic shunt creation. *Clin Transl Gastroenterol* 2021;12:e00376.
  23. Schepis F, Vizzutti F, Garcia-Tsao G, Marzocchi G, Rega L, De Maria N, *et al.* Under-dilated TIPS associate with efficacy and reduced encephalopathy in a prospective, non-randomized study of patients with cirrhosis. *Clin Gastroenterol Hepatol* 2018;16:1153-62.e7.
  24. Pieper CC, Jansen C, Meyer C, Nadal J, Lehmann J, Schild HH, *et al.* Prospective evaluation of passive expansion of partially dilated transjugular intrahepatic portosystemic shunt stent grafts-a three-dimensional sonography study. *J Vasc Interv Radiol* 2017;28:117-25.
  25. Miraglia R, Maruzzelli L, Di Piazza A, Mamone G, Caruso S, Gentile G, *et al.* Transjugular intrahepatic portosystemic shunt using the new gore viatorr controlled expansion endoprosthesis: Prospective, single-center, preliminary experience. *Cardiovasc Intervent Radiol* 2019;42:78-86.
  26. Srinivasa RN, Srinivasa RN, Chick JF, Hage A, Saad WA. Transjugular intrahepatic portosystemic shunt reduction using the GORE VIATORR controlled expansion endoprosthesis: Hemodynamics of reducing an established 10-mm TIPS to 8-mm in diameter. *Cardiovasc Intervent Radiol* 2018;41:518-21.
  27. Ferral H, Bjarnason H, Wegryn SA, Rengel GJ, Nazarian GK, Rank JM, *et al.* Refractory ascites: Early experience in treatment with transjugular intrahepatic portosystemic shunt. *Radiology* 1993;189:795-801.
  28. Rössle M. TIPS: 25 years later. *J Hepatol* 2013;59:1081-93.
  29. Ripamonti R, Ferral H, Alonzo M, Patel NH. Transjugular intrahepatic portosystemic shunt-related complications and practical solutions. *Semin Intervent Radiol* 2006;23:165-76.
  30. Ganger DR, Klapman JB, McDonald V, Matalon TA, Kaur S, Rosenblate H, *et al.* Transjugular intrahepatic portosystemic shunt (TIPS) for Budd-Chiari syndrome or portal vein thrombosis: Review of indications and problems. *Am J Gastroenterol* 1999;94:603-8.

**How to cite this article:** Raissi D, Brahmhatt S, Yu Q, Jiang L, Liu C. Transjugular intrahepatic portosystemic shunt for pediatric portal hypertension: A meta-analysis. *J Clin Imaging Sci* 2023;13:18.