




Case Report

Lipoma of the Larynx and Other Differential Diagnoses

Lela Okromelidze, Erik H. Middlebrooks, Alok A. Bhatt

Department of Radiology, Mayo Clinic, Jacksonville, Florida, United States.



***Corresponding author:**

Alok A. Bhatt,
Mayo Clinic, 4500 San Pablo
Road, Jacksonville,
Florida 32224, United States.

bhatt.alok@mayo.edu

Received : 08 October 19

Accepted : 09 October 19

Published : 18 November 19

DOI

10.25259/JCIS_123_2019

Quick Response Code:



ABSTRACT

Fatty lesions in the head and neck region are uncommon but can present in any subsite, including rarely the larynx. Most commonly, the fatty lesion is a benign lipoma and an incidental finding as in this case. However, the lesion must be differentiated from other fatty lesions such as liposarcoma, lipoblastoma, and hibernoma. Accurate diagnosis on imaging can prevent unnecessary biopsy and more importantly worry for the patient. We report a case of an incidental lipoma within the vocal folds of the larynx.

Keywords: Lipoma, Larynx, Vocal folds

INTRODUCTION

Lipomas of the head and neck are uncommon, and can present in any subsite. Laryngeal lipomas are extremely rare and most often an incidental finding. The purpose of the article is to review the characteristic findings for the diagnosis of laryngeal lipoma on imaging, as well as other differential diagnoses. Accurate diagnosis on imaging can prevent additional invasive tests such as biopsy, and unnecessary worry for the patient.

CASE REPORT

A 51-year-old male presented to the emergency room after bronchoscopy for biopsy of a lymph node with a single episode of hemoptysis and sore throat. Computed tomography (CT) of the neck demonstrated a fat-attenuating lesion (approximately - 95 Hounsfield units) measuring approximately 10 mm×9 mm within the larynx, deep to the mucosal layer of the left vocal folds, resulting in some medial deviation of the cords [Figure 1]. Otherwise, CT examination was normal, and no cause for hemoptysis was found on imaging. The hemoptysis was transient and thought to be post-procedural. Since there were no additional episodes of hemoptysis and vitals were stable, the patient was discharged from the emergency room without further complication. The laryngeal lipoma was presumed to be a completely incidental finding with no further work-up necessary.

DISCUSSION

The overall imaging and clinical findings are compatible with an incidental lipoma of the left vocal folds. Lipomas are the most common benign mesenchymal tumors, presenting at any age, but predominantly during the 4th-6th decades of life due to gradually increasing size.^[1,2] Even though lipomas in the head and neck region are uncommon (<15% of all lipomas), they can manifest in any subsite, including the tonsils, tongue, parotid gland, palate, and larynx.^[1,3]

This is an open-access article distributed under the terms of the Creative Commons Attribution-Non Commercial-Share Alike 4.0 License, which allows others to remix, tweak, and build upon the work non-commercially, as long as the author is credited and the new creations are licensed under the identical terms.

©2019 Published by Scientific Scholar on behalf of Journal of Clinical Imaging Science

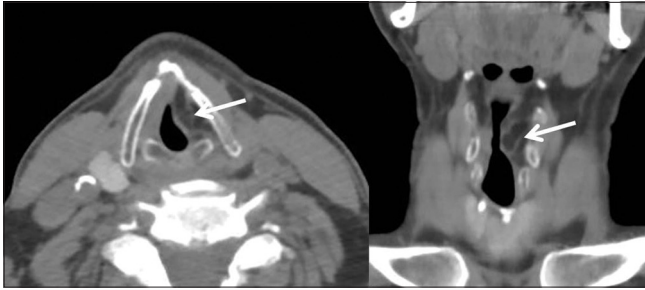


Figure 1: A 51-year-old male with an incidental lipoma of the left vocal folds. Non-contrast axial (left) and coronal (right) computed tomography images through the level of the larynx demonstrate a fat-attenuating lesion similar to adjacent subcutaneous fat (arrows) within the submucosal left vocal folds, which causes mild local mass effect. There is a thin septation within the lesion, but no nodularity.

Laryngeal lipomas, which represent only 1% of all lipomas, are classified into extrinsic and intrinsic tumors.^[4] Extrinsic lesions are located in the posterior aspect of the larynx, pyriform sinus, and lingual surface of the epiglottis, while intrinsic tumors are located in the false vocal cord, laryngeal surface, aryepiglottic folds, and subglottic larynx.^[5]

Laryngeal lipomas may often be an incidental finding as in this case but can also be hard to diagnose due to the symptoms being non-specific.^[1] Dyspnea, sleep apnea/snoring, paroxysmal coughing, dysphagia, and airway obstruction are among the clinical manifestations of this entity.^[2,6]

Imaging provides a key role in diagnosis. On CT, lipomas appear as homogeneous lesions that are low in attenuation, mirroring that of adjacent subcutaneous fat. Magnetic resonance imaging is preferred due to more accurate soft tissue delineation, allowing for better visualization of a pedicle if present, and its anatomical relationship with surrounding structures.^[7] Adipose tissue is visualized as bright on T1-weighted imaging (T1WI) and will suppress on fat-saturated sequences.^[2]

Surgical approach for laryngeal lipoma depends on size, with endoscopic approach favored in small tumors, and external surgical approach preferred in tumors >2 cm in maximum diameter.^[7] Rapid recovery of laryngeal/pharyngeal function with few immediate or late complications is expected following the excision of the tumor. A recurrence of lipoma is rare and may be due to one of two reasons; the lesion is a well-differentiated liposarcoma and not a classic lipoma or due to incomplete resection of the lesion.^[1]

There are four main differential diagnoses when evaluating fatty lesions of the larynx: Lipoma, liposarcoma, lipoblastoma, and hibernoma. Differentiating liposarcomas and lipomas on imaging can be challenging due to subtle findings that may favor a liposarcoma.^[6] Hemorrhage and necrosis are suggestive of liposarcoma, while complete fat suppression, lack of septations, and no enhancement favor the diagnosis

of lipoma.^[6,7] Angiography might aid in differentiation due to hypervascularity in liposarcomas.^[7] Definitive diagnosis is based on histopathology. Adipocytes of varying sizes as well as macrophages are suggestive of benign lipomas, while lack of macrophages and variation of adipocytes suggest liposarcoma over lipoma.^[6]

A lipoblastoma is a rare, benign tumor that arises from embryonic white fat but can look like liposarcoma on imaging; the lesion typically presents in infancy and early childhood, and most often occurs in the trunk and extremities.

A hibernoma is a lipomatous lesion seen in middle-aged patients, consisting of brown fat. On T1WI, a hibernoma is hypointense in comparison to subcutaneous adipose tissue and does not suppress on fat-saturated sequences.^[8,9] On CT, hibernomas are well-circumscribed lesions with attenuation between skeletal muscle and fat.^[9] Significant difference between these lesions is observed on positron emission tomography/CT imaging due to brown fat's intense glucose metabolism and, therefore, avid fluorodeoxyglucose uptake. Under the microscope, hibernoma is described as multivacuolated fat cells of lobular pattern with prominent vascular supply.^[8]

CONCLUSION

Our case highlights the point that laryngeal lipomas may be an incidental finding on imaging performed for other reasons; the lesion in our case did not require further follow-up. Even though the lipoma is the most common fatty lesion within the head and neck, one must also consider liposarcoma, lipoblastoma, and hibernoma.

Declaration of patient consent

The authors certify that they have obtained all appropriate patient consent forms.

Financial support and sponsorship

Nil.

Conflicts of interest

There are no conflicts of interest.

REFERENCES

1. Nader S, Nikakhlagh S, Rahim F, Fatehizade P. Endolaryngeal lipoma: Case report and literature review. *Ear Nose Throat J* 2012;91:E18-21.
2. Burkes JN, Campos L, Williams FC, Kim RY. Laryngeal spindle cell/pleomorphic lipoma: A case report. An in-depth review of the adipocytic tumors. *J Oral Maxillofac Surg* 2019;77:1401-10.

3. Khorsandi Ashtiani MT, Yazdani N, Saeedi M, Amali A. Large lipoma of the larynx: A case report. *Acta Med Iran* 2010;48:353-6.
4. El-Monem MH, Gaafar AH, Magdy EA. Lipomas of the head and neck: Presentation variability and diagnostic work-up. *J Laryngol Otol* 2006;120:47-55.
5. Zakrzewski A. Subglottic lipoma of the larynx. (Case report and literature review). *J Laryngol Otol* 1965;79:1039-48.
6. Kodyan J, Rudman JR, Rosow DE, Thomas GR. Lipoma and liposarcoma of the larynx: Case reports and literature review. *Am J Otolaryngol* 2015;36:611-5.
7. De Vincentiis M, Greco A, Mascelli A, Soldo P, Zambetti G. Lipoma of the larynx: A case report. *Acta Otorhinolaryngol Ital* 2010;30:58-63.
8. Burt AM, Huang BK. Imaging review of lipomatous musculoskeletal lesions. *SICOT J* 2017;3:34.
9. Greenbaum A, Coffman B, Rajput A. Hibernoma: Diagnostic and surgical considerations of a rare benign tumour. *BMJ Case Rep* 2016;2016:bcr2016217625.

How to cite this article: Okromelidze L, Middlebrooks EH, Bhatt AA. Lipoma of the larynx and other differential diagnoses. *J Clin Imaging Sci* 2019;9:51.