



Neuroradiology/Head and Neck Imaging Pictorial Essay

## Lipemia Retinalis in a Patient with Familial Hypertriglyceridemia

Patrick Wang<sup>1</sup>, Eric K. Chin<sup>2</sup>, David R. P. Almeida<sup>3</sup>

<sup>1</sup>Department of Ophthalmology, Queen's University, Ontario, Canada, <sup>2</sup>Department of Ophthalmology, Retina Consultants of Southern California, Redlands, California, <sup>3</sup>Department of Ophthalmology, Erie Retinal Surgery, Pennsylvania, United States.



**\*Corresponding author:**

David R. P. Almeida,  
Department of Ophthalmology,  
Erie Retinal Surgery, Erie,  
Pennsylvania, United States.

drpa27@yahoo.ca

Received : 30 August 2020

Accepted : 02 October 2020

Published : 17 October 2020

**DOI**

10.25259/JCIS\_154\_2020

**Quick Response Code:**



### ABSTRACT

A 45-year-old female with a history of hypertension presented with complaints of intermittent vision loss and blurred vision. Clinical examination revealed diffuse retinal whitening in the peripapillary area with multiple visible emboli in the first- and second-order arteries. The patient's retinal findings were keeping within features of lipemia retinalis, and serum lipids were ordered which returned a triglyceride level of 1504 mg/dL. The patient was referred to primary care for vascular risk factor management and potential genetic testing. Ocular signs of hypertriglyceridemia manifest as lipemia retinalis, characterized by white vascular lesions and retinal lipid infiltration. The high comorbidity of hypertriglyceridemia and hypertension may warrant close monitoring hypertensive complications such as hypertensive retinopathy.

**Keywords:** Retina, Lipemia retinalis, Hypertriglyceridemia

### INTRODUCTION

Lipemia retinalis is a rare ocular finding associated with hypertriglyceridemia first described by Heyl in 1880.<sup>[1]</sup> Retinal changes, characterized by variation in retinal vasculature ranging from salmon pink to creamy white, are commonly found. Early discoloration of the retinal vessels typically begins in the retinal periphery.<sup>[2]</sup> Familial hypertriglyceridemia (FHTG) is an autosomal dominant disease consisting of elevated triglycerides with normal or mildly increased total cholesterol levels.<sup>[3]</sup> In severe hypertriglyceridemia, hypertension is associated in 31.3% of cases.<sup>[4]</sup>

Here, we describe a patient with lipemia retinalis presenting with intermittent vision loss. While patients with lipemia retinalis do not typically present with decreased visual acuity, our case of lipemia retinalis is complicated by hypertensive retinopathy and a positive family history in context consistent with FHTG.

### CASE PRESENTATION

A 45-year-old female presented with complaints of intermittent vision loss and blurred vision OS>OD for 3 months. Previous medical history was significant for systemic hypertension, thyroid disease, bipolar disorder, post-traumatic stress disorder, endometriosis, hyperlipidemia, and hypertriglyceridemia. The patient had been taking a statin, fibrate, and fish oil supplement for control

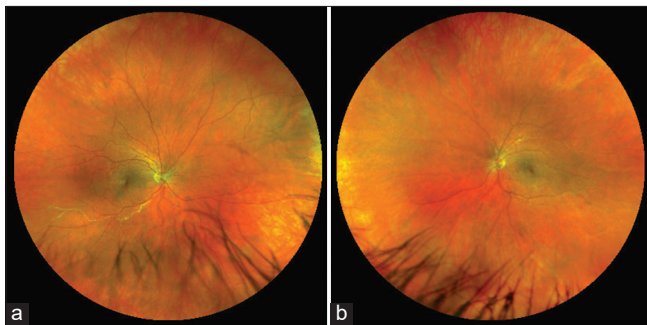
This is an open-access article distributed under the terms of the Creative Commons Attribution-Non Commercial-Share Alike 4.0 License, which allows others to remix, tweak, and build upon the work non-commercially, as long as the author is credited and the new creations are licensed under the identical terms.

©2020 Published by Scientific Scholar on behalf of Journal of Clinical Imaging Science

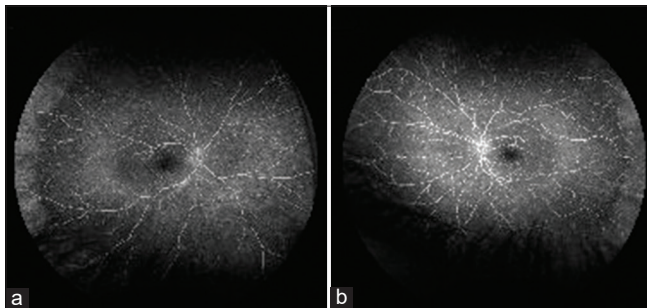
of her hyperlipidemia and a beta-blocker for her hypertension for the past 5 years. There was a positive family history of elevated serum lipids in her brother and father suggestive of FHTG but genetic testing had not been performed.

Anterior segment examination was unremarkable OU. Posterior segment examination and color fundus photography revealed diffuse retinal whitening with multiple visible emboli in the first- and second-order arteries, especially prominent in the peripapillary area. Signs of arterial venous nicking were observed as well [Figure 1]. Widefield intravenous fluorescein angiography demonstrated arterial filling delay and a pattern of hypofluorescence consistent with capillary non-perfusion OU [Figure 2].

Given the patient's history and vascular risk factors, serum lipids were ordered which returned a triglyceride level of 1504 mg/dL. The patient was referred to her primary care provider for ongoing vascular risk factor management. Moreover, given the positive family history suggestive of FHTG, the patient was counseled on the role of genetic testing.



**Figure 1:** A 45-year-old woman with familial hypertriglyceridemia. (a) Widefield color fundus of the right eye illustrates diffuse retinal whitening with multiple visible emboli in the first- and second-order arteries. (b) Widefield color fundus of the left eye demonstrates similar peripheral retinal whitening with multiple visible emboli as well as arterial venous nicking.



**Figure 2:** A 45-year-old woman with familial hypertriglyceridemia. (a) Widefield intravenous fluorescein angiography of the right eye demonstrates arterial filling delay and pattern of hypofluorescence consistent with capillary non-perfusion. (b) Widefield intravenous fluorescein angiography of the left eye displays similar arterial filling delay and hypofluorescence pattern.

## DISCUSSION

Ocular signs of hypertriglyceridemia (xanthomas, xanthelasma, and corneal arcus) may begin to present as early as serum levels reach over 1000 mg/dL.<sup>[5]</sup> Lipemia retinalis is often not observed until triglyceride levels reach >1500 mg/dL.<sup>[2]</sup> The level of serum triglyceride is often correlated with the severity of lipemia retinalis and at levels of 5000 mg/dL, the fundus may begin to appear salmon colored with creamy arteries and veins that can be distinguished by caliber only.<sup>[2]</sup>

Typically, lipemia retinalis is not a sight-threatening condition; in these patients, appropriate referrals to endocrinology and cardiology are critical for controlling vascular risk factors and close follow-up of hyperlipidemia is indicated.<sup>[6]</sup> While there have been no reports of lipemia retinalis directly affecting visual acuity, Lu *et al.* described changes on electroretinography, namely, decreased a and b waves in both cone and rod responses.<sup>[7]</sup> Changes to the electroretinography and retinal vasculature were reversed with proper dietary control.<sup>[8]</sup> In addition, Nagra *et al.* reported a case of lipemia associated with a branch vein occlusion.<sup>[9]</sup>

According to the National Health and Nutrition Examination Survey, the prevalence of hypertension and hypercholesteremia (>240 mg/dL) in the presence of severe hTG (500–2000 mg/dL) is 31.3% and 66.7%, respectively.<sup>[4]</sup> While the vascular effects of elevated hypertriglyceridemia are controversial, high cholesterol is a known risk factor for developing atherosclerosis and hypertension. The chronic effects of hypertension on the retina caused by atherosclerosis predispose patients to visual loss from retinal ischemia.<sup>[10]</sup>

## CONCLUSION

Our case presents a unique presentation of lipemia retinalis with intermittent visual loss likely due to hypertensive retinopathy. While in this case, the patient had presented with symptomatic retinal ischemia, the presence of lipemia retinalis and its high prevalence of comorbidities such as hypertension may hold clinical relevance in such patients. While more epidemiological studies are needed, patients with hypertriglyceridemia and associated hypercholesterolemia may warrant closer monitoring and prevention of hypertension and hypertensive complications. A thorough history aids stratification of patient's risk for other conditions such as retinal vein or artery occlusions and hypertensive retinopathy and is prudent in these cases.

## Declaration of patient consent

The authors certify that they have obtained all appropriate patient consent.

### Financial support and sponsorship

Nil.

### Conflicts of interest

There are no conflicts of interest.

### REFERENCES

1. Heyl AG. Intra-ocular lipaemia. *Trans Am Ophthalmol Soc* 1880;3:54-66.
2. Alexander LJ. Ocular signs and symptoms of altered blood lipids. *J Am Optom Assoc* 1983;54:123-6.
3. Yuan G, Al-Shali KZ, Hegele RA. Hypertriglyceridemia: Its etiology, effects and treatment. *CMAJ* 2007;176:1113-20.
4. Christian JB, Bourgeois N, Snipes R, Lowe KA. Prevalence of severe (500 to 2,000 mg/dl) hypertriglyceridemia in United States adults. *Am J Cardiol* 2011;107:891-7.
5. Leaf DA. Chylomicronemia and the chylomicronemia syndrome: A practical approach to management. *Am J Med* 2008;121:10-2.
6. Schaefer EW, Leung A, Kravarusic J, Stone NJ. Management of severe hypertriglyceridemia in the hospital: A review. *J Hosp Med* 2012;7:431-8.
7. Lu CK, Chen SJ, Niu DM, Tsai CC, Lee FL, Hsu WM. Electrophysiological changes in lipaemia retinalis. *Am J Ophthalmol* 2005;139:1142-5.
8. Ram J, Pandav SS, Jain S, Arora S, Gupta A, Sharma A. Reversal of lipaemia retinalis with dietary control. *Eye (Lond)* 1993;7:763-5.
9. Nagra PK, Ho AC, Dugan JD Jr. Lipemia retinalis associated with branch retinal vein occlusion. *Am J Ophthalmol* 2003;135:539-42.
10. Tso MO, Jampol LM. Pathophysiology of hypertensive retinopathy. *Ophthalmology* 1982;89:1132-45.

**How to cite this article:** Wang P, Chin EK, Almeida DR. Lipemia Retinalis in a Patient with Familial Hypertriglyceridemia. *J Clin Imaging Sci* 2020;10:64.