



Ultrasound Case Report

Isolated congenital absence of bilateral femur: A rare case report with antenatal diagnosis and postnatal follow-up

Aakriti Kapoor¹, Tushar Kapoor¹, Aakaar Kapoor¹, Apurva Kapoor¹, Ravi Kapoor¹, Veronica Arora², Deepak Mehar¹

¹Department of Radiology, City X-Ray and Scan Clinic Pvt. Ltd., New Delhi, Delhi, India, ²Sir Gangaram Hospital, New Delhi, Delhi, India.



*Corresponding author:

Tushar Kapoor,
Department of Radiology, City
X-Ray and Scan Clinic Pvt.
Ltd., New Delhi, Delhi, India.

tusharkapoor2307@gmail.com

Received : 08 December 2021

Accepted : 03 March 2022

Published : 02 May 2022

DOI

10.25259/JCIS_219_2021

Quick Response Code:



ABSTRACT

We report a rare case of isolated congenital absence of the bilateral femur diagnosed antenatally in an 18–19 weeks fetus on a level II scan. The bilateral femur bones were not visualized with normal bilateral tibia and fibula. The fetus was followed with a routine growth scan at 32–33 weeks along with a fetal MRI, which showed similar findings. The antenatal findings were confirmed clinically as well as with a postnatal follow-up X-Ray (infantogram) of the baby. Trio whole-exome sequencing was performed for the child as well as both the parents, which did not reveal any clinically significant variant that could explain the patient's phenotype.

Keywords: Antenatal, Femur, Congenital.

INTRODUCTION

Fetal growth and development of the lower extremities are guided by a multitude of growth factors. These are expressed in a particular sequence and at various concentrations during embryo development. Embryogenesis of the extremities occurs between 4 and 8 weeks in utero. Most limb deficiencies occur in this period of time.^[1,2] Congenital defects of the femur vary from simple hypoplasia of the bone to near-complete or complete absence. The clinical distinction between the various types of femoral defect is important as a guide to the prognosis of limb development as well as further management of the patient.^[3]

CASE REPORT

A 41-year-old multigravida patient was referred for a level II scan at 18–20 weeks. There was no history of consanguinity in the parents. No congenital abnormality was detected in the previous pregnancy of the patient or in any of the family members before. There was no history of any known teratogenic exposure. The scan revealed nonvisualization of the bilateral femur bones [Figure 1]. The bilateral tibia and fibula were within normal limits as per gestational age [Figure 2]. 3D and 4D ultrasounds also clearly demonstrated the same abnormality [Figure 3]. Associated club foot was seen on the right side. There were no other cranio-spinal or cardiovascular abnormalities. The patient was followed up at 32–33 weeks of gestation. Bilateral femur bones were still not seen. Also, the rest of the long bones were 5–6 weeks shorter than the gestational age. Fetal MRI was performed, which also showed similar findings [Figure 4]. The baby (female) was delivered by

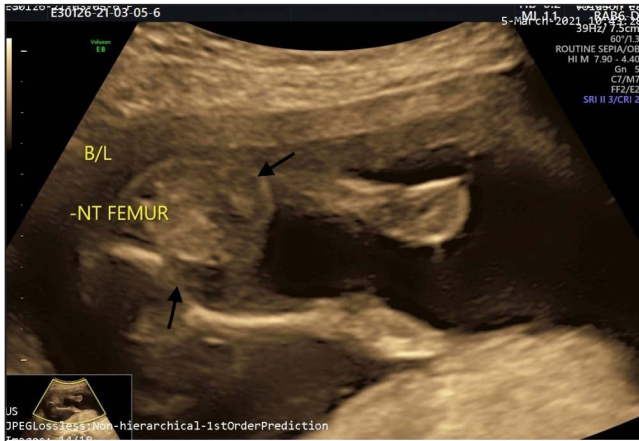


Figure 1: Antenatal ultrasound scan of the fetus at 18–20 weeks at the level of the lower abdomen and pelvis shows nonvisualization of bilateral femur bones.

cesarean section at 38 weeks of gestation. The APGAR score was 7. The height of the baby was 37 cm (<1st percentile), weight was 2.35 kg (<3rd percentile), OFC was 32 cm. The antenatal findings were confirmed postnatally both clinically [Figure 5] as well as with an X-ray infantogram [Figure 6]. The X-ray showed absent bilateral femur bones. The bilateral tibia was forming a pseudoarthrosis with the acetabulum. The acetabulum itself appeared shallow and dysplastic with a vertical orientation. The right fibula was visualized but the left fibula was not seen clearly (likely non-ossified). A routine transcranial and whole abdominal ultrasound were performed after birth, which was within normal limits.

Trio whole-exome sequencing (WES) was performed for the child and both the parents using blood as the tissue. No clinically significant variant was identified that can explain the patient's phenotype: short long bone, aplasia/hypoplasia involving the skeletal musculature, abnormality of femur

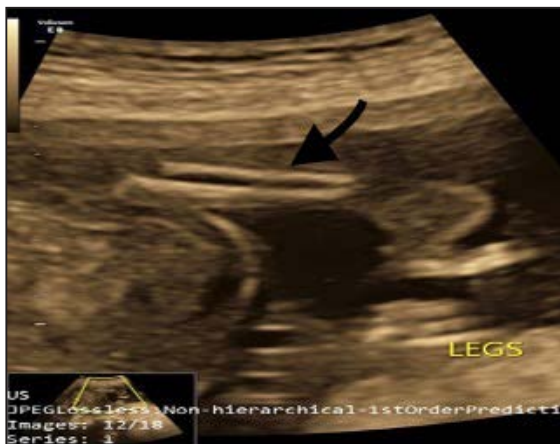

Figure 2a: Antenatal ultrasound at 18–20 weeks at the level of the legs shows normal-appearing bilateral tibia and fibula of the right side (arrow).

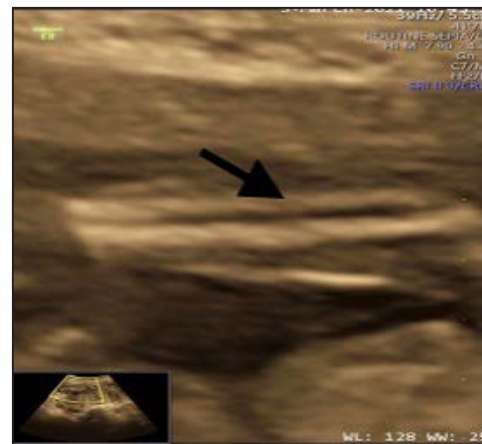

Figure 2b: Antenatal ultrasound at 18–20 weeks at the level of the legs shows a normal-appearing bilateral tibia and fibula of the left side (arrow).

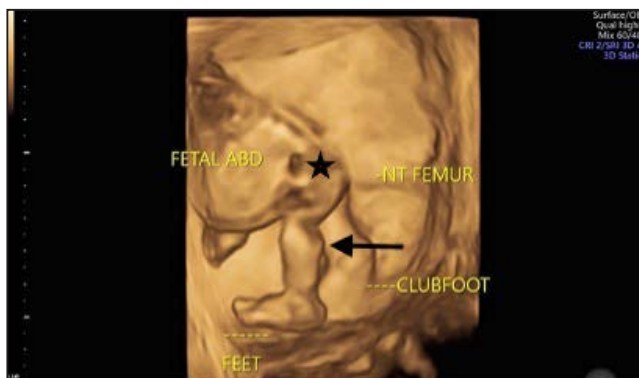

Figure 3a: 3D ultrasound image at the level of lower limbs clearly demonstrates nonvisualized thigh (asterisk) with a normally developed leg (arrow).

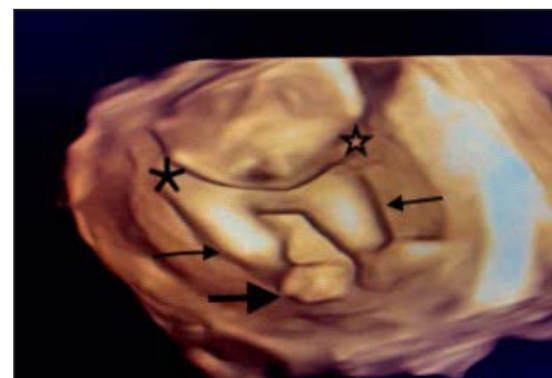


Figure 3b: Another 3D ultrasound image at the level of lower limbs demonstrates normally developed both legs (tibia and fibula, denoted by thin arrows) directly articulating with the pelvis (asterisks) with nonvisualization of bilateral thighs (femurs). Note is made of right-sided club foot (bold arrow).

morphology, abnormality of the skeletal system. Microarray or karyotyping could not be performed; however, copy number variation in the WES data was looked for.

DISCUSSION

Bilateral absence of femur is a rare congenital anomaly and is at the extreme end of the congenital femur deficiency spectrum. These anomalies can occur isolated or in association with other anomalies, e.g., fibular hemimelia (most common), clubfoot, foot array abnormality, and acetabular dysplasia.^[1] In our case, the acetabulum was shallow and dysplastic as well as there was a right-sided club foot. No other associated abnormality was seen. The exact cause of congenital femoral deficiencies or absence is not

known in most cases. Some of the abnormalities may be caused by a genetic base while others may be caused by an indirect effect of teratogen.^[4,5] The classification by Aitken for femoral deficiency has been widely used for many years. This classification is based on the severity of the hip and femur deficiency on radiographic findings. There are four classes in Aitken classification: class A– the presence of femoral head with varus deformity; class B– the presence of femoral head but with delayed ossification; varus, mild acetabular dysplasia, and pseudoarthrosis may occur; class C– the absence of femoral head as well as acetabular dysplasia and shortening of femur; and class D– the absence of femoral head with severe dysplastic and severely shortened femur.

The case presented here does not fit into any of the classifications above. There is a complete absence of femur and tibia-fibula complex that appear to be connected to the acetabulum. The proximal part of the tibia appears femur-like in shape.

Trio WES did not reveal any variant which could explain the phenotype. Several variants have been prioritized according to the EVIDENCE, a software that calculates comprehensive scores for phenotypic similarity to the disease and pathogenicity of the variants based on the American College of Medical Genetics guideline.^[6] We did not detect any variants associated with the patient's phenotype, although we paid special attention to all detected variants to select relevant variants to the patient's clinical information. However, the possibility of missed detection of the pathogenic variants cannot be excluded, because the coverage of the exons may not be complete due to the technical limitations of the method (nondetection of uniparental disomy, low-level mosaicism, copy number variations, and intronic variants). Further

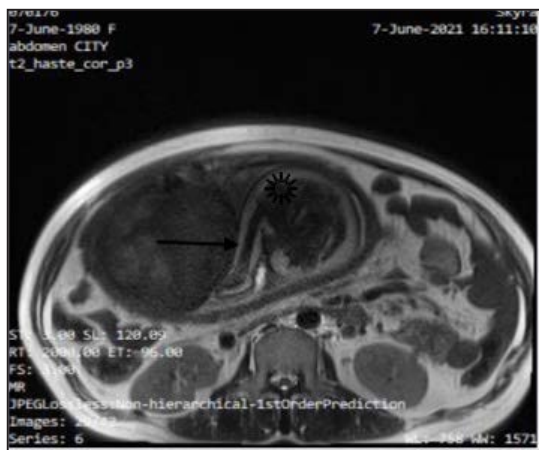

Figure 4: Fetal MRI has done at 32–33 weeks at the level of the fetal pelvis, shows nonvisualization of femur with the tibia and fibula (arrow) in close proximity with the acetabulum (asterisk).

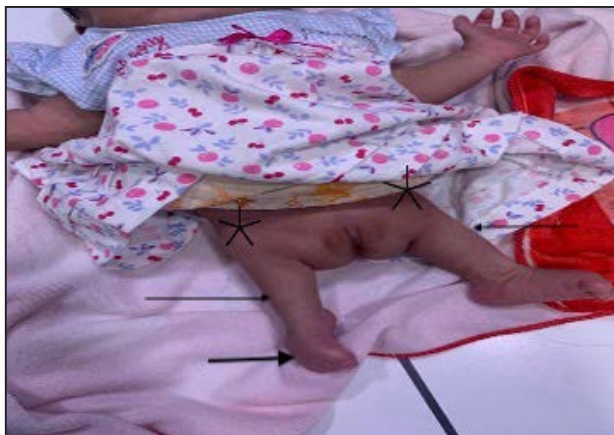

Figure 5: Postnatal clinical photograph of the baby demonstrates bilateral absent thighs with a right-sided club foot. This photograph is exactly the same as shown in the antenatal 3D ultrasound images shown in Figure 3b.

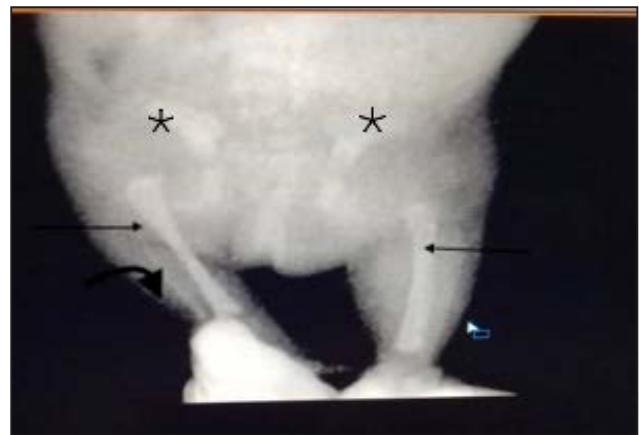

Figure 6: Postnatal X-ray infantogram confirms the prenatal observations. Bilateral femur bones are not seen. Bilateral proximal tibia (arrows) appears femur-like in shape and tibia is seen forming pseudoarthrosis with the acetabulum (asterisks). The acetabulum appears shallow and dysplastic (asterisks). The right fibula is visualized (bold arrow) but the left fibula is not seen clearly (likely non-ossified).

whole-genome sequencing may be worthwhile to look for novel genes.

CONCLUSION

Bilateral complete absence of femur is a very rare anomaly. To the best of our knowledge, it is the first reported antenatal case with postnatal follow-up in the world literature. This case is interesting as it does not fit in any category of the femoral deficiency classification which was given by Aitken, and is the most commonly used classification in clinical practice to guide patient management. More cases like these might need a newer classification, which covers this abnormality and to guide better management for these patients.

Declaration of patient consent

Patient's consent not required as patient's identity is not disclosed or compromised.

Financial support and sponsorship

Nil.

Conflicts of interest

There are no conflicts of interest.

REFERENCES

1. Paley D, Guardo F. Congenital femoral deficiency reconstruction and lengthening surgery. In: Sabharwal S, editor. *Pediatric Lower Limb Deformities*. Switzerland: Springer International Publishing; 2016. p. 361–425.
2. Herring JA. Limb deficiencies. In: Herring JA, editor. *Tachdjian's Pediatric Orthopaedics*. 5th ed. Vol. 1. Philadelphia, PA: WB. Saunders; 2014. p. 951–74.
3. Ring PA. Congenital abnormalities of the femur. *Arch Dis Child* 1961;36:410–7.
4. Ukkali SB, Mahvish K, Jeergal N. Congenital femoral deficiency: A rare case report. *Int J Contemp Pediatr* 2017;4:1118–21.
5. Bowen RE, Otsuka NY, Evans EL, Smith NR. The child with a limb deficiency. In: Weinstein SL, Flynn JM, editors. *Lovell and Winter's Pediatric Orthopaedics*. 7th ed., Vol. 2. Philadelphia, PA: Lippincott Williams and Wilkins; 2014. p. 1526–95.
6. Richards S, Aziz N, Bale S, Bick D, Das S, Gastier-Foster J, *et al.* Standards and guidelines for the interpretation of sequence variants: A joint consensus recommendation of the American College of Medical Genetics and Genomics and the Association for Molecular Pathology. *Genet Med* 2015;17:405–24.

How to cite this article: Kapoor A, Kapoor T, Kapoor A, Kapoor A, Kapoor R, Arora V, *et al.* Isolated congenital absence of bilateral femur: A rare case report with antenatal diagnosis and postnatal follow-up. *Journal of Clinical Imaging Science* 2022;12:23.