



## Imaging Science Original Research

# Pixel-based analysis of pulmonary changes on CT lung images due to COVID-19 pneumonia

Elif Soya<sup>1</sup>, Nur Ekenel<sup>1</sup>, Recep Savas<sup>2</sup>, Tugce Toprak<sup>3</sup>, James Bewes<sup>4</sup>, Ozkan Doganay<sup>1</sup>

<sup>1</sup>Department of Basic Oncology, Institute of Health Sciences, Ege University, Izmir, Turkey, <sup>2</sup>Department of Radiology, Faculty of Medicine, Ege University, Izmir, Turkey, <sup>3</sup>Department of Electrical and Electronics Engineering, Institute of Natural and Applied Sciences, Dokuz Eylul University, Izmir, Turkey, <sup>4</sup>South East Radiology, New South Wales, Australia.



### \*Corresponding author:

Ozkan Doganay,  
Department of Basic Oncology,  
Institute of Health Sciences,  
Ege University, Izmir, Turkey.

ozkandoganay@gmail.com

Received : 06 September 2021

Accepted : 28 January 2022

Published : 19 February 2022

### DOI

10.25259/JCIS\_172\_2021

### Quick Response Code:



## ABSTRACT

**Objectives:** Computed tomography (CT) plays a complementary role in the diagnosis of the pneumonia-burden of COVID-19 disease. However, the low contrast of areas of inflammation on CT images, areas of infection are difficult to identify. The purpose of this study is to develop a post-image-processing method for quantitative analysis of COVID-19 pneumonia-related changes in CT attenuation values using a pixel-based analysis rather than more commonly used clustered focal pneumonia volumes. The COVID-19 pneumonia burden is determined by experienced radiologists in the clinic. Previous AI software was developed for the measurement of COVID-19 lesions based on the extraction of local pneumonia features. In this respect, changes in the pixel levels beyond the clusters may be overlooked by deep learning algorithms. The proposed technique focuses on the quantitative measurement of COVID-19 related pneumonia over the entire lung in pixel-by-pixel fashion rather than only clustered focal pneumonia volumes.

**Material and Methods:** Fifty COVID-19 and 50 age-matched negative control patients were analyzed using the proposed technique and commercially available artificial intelligence (AI) software. The %pneumonia was calculated using the relative volume of parenchymal pixels within an empirically defined CT density range, excluding pulmonary airways, vessels, and fissures. One-way ANOVA analysis was used to investigate the statistical difference between lobar and whole lung %pneumonia in the negative control and COVID-19 cohorts.

**Results:** The threshold of high-and-low CT attenuation values related to pneumonia caused by COVID-19 were found to be between -642.4 HU and 143 HU. The %pneumonia of the whole lung, left upper, and lower lobes were  $8.1 \pm 4.4\%$ ,  $6.1 \pm 4.5$ , and  $11.3 \pm 7.3\%$  for the COVID-19 cohort, respectively, and statistically different ( $P < 0.01$ ). Additionally, the pixel-based methods correlate well with existing AI methods and are approximately four times more sensitive to pneumonia particularly at the upper lobes compared with commercial software in COVID-19 patients ( $P < 0.01$ ).

**Conclusion:** Pixel-by-pixel analysis can accurately assess pneumonia in COVID-19 patients with CT. Pixel-based techniques produce more sensitive results than AI techniques. Using the proposed novel technique, %pneumonia could be quantitatively calculated not only in the clusters but also in the whole lung with an improved sensitivity by a factor of four compared to AI-based analysis. More significantly, pixel-by-pixel analysis was more sensitive to the upper lobe pneumonia, while AI-based analysis overlooked the upper lung pneumonia region. In the future, this technique can be used to investigate the efficiency of vaccines and drugs and post COVID-19 effects.

**Keywords:** Computed Tomography (CT), COVID-19, Pneumonia, Ground glass opacity (GGO), CT attenuation

## INTRODUCTION

As of March 11<sup>th</sup>, 2020, WHO assessed that COVID-19 can be characterized as a pandemic since it is highly contagious and may lead to acute respiratory distress.<sup>[1-3]</sup> Real-time reverse transcription-polymerase chain reaction (RT-PCR) is widely used for the diagnosis

of COVID-19 with an accuracy of 30–70% due to the sampling errors and a lack of sufficient virus load.<sup>[4,5]</sup> In some healthcare systems, computed tomography (CT) plays a complementary role in both early diagnosis and quantitative analysis of pneumonia burden.<sup>[6-8]</sup> However, areas of infection on chest CT scans are difficult to identify because of the low contrast of areas of inflammation on CT images and vary for each patient.<sup>[9]</sup> Therefore, to analyze CT images, validate the PCR technique, and minimize the margin of error, deep learning algorithms have been developed and tested for the detection of radiological findings of COVID-19 disease.<sup>[3,9-11]</sup>

Approximately 90% of COVID-19 patients have abnormal findings on chest CT, with pneumonia typified by ground-glass opacity, consolidation, crazy-paving pattern, linear opacities, reversed halo sign, etc.<sup>[12-17]</sup> Ground-glass opacities (GGO) are usually present with consolidation in the peripheral lungs and characterized by increased CT image attenuation related to alveolar collapse, interstitial thickening, and partial filling of air spaces with fluid, cells, and debris. There is usually preservation of bronchial and vascular structures.<sup>[18-23]</sup>

A recent study focused on qualifications of COVID-19 pneumonia volumes using the CT attenuation classification with three types: (a) pure GGO lesion is less than  $-300$  Hounsfield unit (HU), (b) subsolid lesion is between  $-300$  HU and  $50$  HU, (c) solid lesion is greater than  $50$  HU, however, precise CT attenuation values associated to COVID-19 pneumonia have not been investigated yet.<sup>[11,13,24]</sup> Nonetheless, radiologists are very sensitive and well trained to CT pneumonia related to COVID-19, the quantitative evaluation of an entire CT image that consist of approximately a hundred thousand pixel requires to use of computer programs. To this end, AI algorithms were developed for the quantification of COVID-19 pneumonia clusters only.<sup>[25-28]</sup> However, AI algorithms focus on cluster analysis of COVID-19 pneumonia volumes, potentially overlooking pixel-wise CT attenuation changes over the whole lungs particularly in the upper lobes. Additionally, CT attenuation values can significantly vary in healthy lungs due to anatomical variation in vessels, airways, blood plasma, and pulmonary tissue.<sup>[29]</sup> To eliminate the effect of main airways and vessels on pneumonia calculations of soft tissues, they should be segmented and removed from the chest CT images.

The purpose of this study is to develop a technique for quantitative measurement of COVID-19 related pneumonia in CT attenuation values over the entire lung in pixel-by-pixel bases rather than only clustered focal pneumonia volumes excluding main airways and vessels. To investigate the feasibility of the technique, lobar lung pneumonia was calculated for patients with COVID-19 in comparison to an age-matched negative control cohort.

## MATERIAL AND METHODS

**Patients:** The medical ethics committee approved this study. All patients gave informed consent. We retrospectively analyzed patients who underwent RT-PCR sampling between March 2020 and May 2020, who presented with a positive RT-PCR test result and were diagnosed with definitive COVID-19 pneumonia with GGO. CT scans were acquired on the same day as the positive RT-PCR test. The exclusion criteria for COVID-19 patients are the presence of structures on the lung CT image occurring from pulmonary diseases other than COVID-19 such as lung cancer or emphysema and CT artifacts due to patient movement. Inclusion criteria for negative control subjects were negative COVID-19 RT-PCR test. The exclusion criteria for negative control subjects are age  $<18$  years, previous medical record of lung disease, and presence of known pulmonary disorders such as lesion or nodule in the CT images and CT artifacts due to patient movement.

**CT examination:** All CT scans were acquired with a 160-slice CT scanner (Aquilion Prime, Toshiba Canon Medical Systems, Japan) in axial plane craniocaudally at shallow inspiration and included the body part from the thoracic inlet to the end of the diaphragm. Images were taken at high-resolution CT protocol with  $120$  kVp,  $100$ – $200$  mA,  $80 \times 0.5$  mm collimation, and reconstructed at  $0.5$  mm slice thickness with a sharp reconstruction kernel.

**Analysis of COVID-19 pneumonia and lung content:** CT images from the negative-control and COVID-19 patient cohorts were assessed by a radiologist who has 30 years of experience in lung diseases. To identify the CT attenuation threshold values associated with pneumonia, the attenuation values of  $50$  COVID-19 patients were determined by selecting 10 pixels on CT images of each patient where pneumonia focal increased density in the lung with the highest five values and the lowest five values. The threshold<sub>low</sub> and threshold<sub>high</sub> were calculated as the lower and upper critical values for the confidence interval of 95% of the minimum and maximum CT distribution of pneumonia among 500-pixel CT attenuation values. The pulmonary airways, vessels, and lung lobes were segmented using an open-access software (PTK: Pulmonary Toolkit, version 3) library as shown in [Figure 1 (a)]: shows representative CT images of a COVID-19 patient (24-year-old, male), (b) Segmented airways of lung, (c) Segmented pulmonary vessels, and (d) A map of COVID-19 pneumonia for CT attenuation threshold values between  $-642.4$  HU and  $143$  HU. All the lobar segmentations were checked and/or corrected manually if automatic segmentation was not sufficient by an experienced radiologist.<sup>[30]</sup> Knowing the threshold<sub>low</sub> and threshold<sub>high</sub> window levels, the percentage pneumonia

volume in each lung lobes were then calculated excluding airways and vessels as follows:

$$\% \text{pneumonia} = \left[ \frac{n_{\text{pixel}}(\text{pneumonia})}{n_{\text{pixel}}(\text{lobe})} \right] \times 100 \text{ Eq. (1)}$$

Where  $n_{\text{pixel}}(\text{pneumonia})$  represents the number of pixels between  $\text{threshold}_{\text{low}}$  and  $\text{threshold}_{\text{high}}$ , and  $n_{\text{pixel}}(\text{lobe})$  is the number of total pixels within the corresponding lobe. Similarly, the percentage lung contents, %LC, was calculated using Eq. (1) from the age-matched negative control group for estimation of misleading (contribution of artefactual increased attenuation from normal bronchovascular structures) %pneumonia that was categorized to be %LC.

Additionally, the total opacity volume over the whole lung volume of 50 COVID-19 patients was calculated using commercially available software (v1.2.2.0 MEDIP COVID-19, Seoul, Korea) for comparison to the %pneumonia volume.

**Statistical analysis:** Significant differences in age and whole lung volumes between the negative control and COVID-19 groups were tested using SPSS (version 25.0, IBM SPSS Statistics)<sup>[31]</sup> with an unpaired *t*-test. All data are expressed as mean  $\pm$  standard deviation (SD). To compare the two groups of COVID-19 and negative control cohort, Kolmogorov–Smirnov test was used to assess data distribution. The correlation between pixel-by-pixel %pneumonia and AI-based opacity volume was investigated using linear correlation analysis. Inter-lobe comparison of %pneumonia and %LC for negative control and COVID-19 patients was performed using a one-way ANOVA analysis with Tukey adjustments. Statistical significance was considered  $P < 0.05$  for all measures.

## RESULTS

The average age of COVID-19 patients was  $52.02 \pm 14.80$  years, ranging from 20 to 79 years old, and the average age of negative control patients was  $46.40 \pm 14.09$  years, ranging from 18 to 72 years old. [Table 1] shows a summary of patient demographic of 100 subjects including 50 patients (males 34, females 16) with confirmed COVID-19 and 50 negative control subjects (males 24, females 26). Negative control and COVID-19 groups were age-matched on the overall mean ( $P = 0.078$ ). COVID-19 patients were diagnosed with the most common symptoms including, malaise or fatigue ( $n = 10$ ), cough ( $n = 8$ ), sore throat ( $n = 7$ ), and fever ( $n = 6$ ).

A representative CT image from a COVID-19 patient and how the calculation of %pneumonia are shown in [Figure 1]. The %pneumonia (**d**) was calculated by subtracting the segmented airways (**b**) and segmented pulmonary vessels (**c**) from lung CT image (**a**). The corresponding %pneumonia of the COVID-19 subject was found to be 2.72% of whole lungs.

[Figure 2]: shows representative CT images of a negative control and a COVID-19 patient in (**a-c**) and the corresponding lobar segmentation in (**b-d**), respectively. %LC can be seen in a negative control subject in (**a**) as well as %pneumonia in a COVID-19 patient in (**c**) within a CT attenuation window between  $-600$  HU and  $1600$  HU.

For calculation of  $\text{threshold}_{\text{low}}$  and  $\text{threshold}_{\text{high}}$ , the distribution of minimum and maximum CT attenuation values of 50 COVID-19 subjects are shown in [Figure 3]. The bounds of the 95% confidence interval for lung attenuation were  $\text{threshold}_{\text{low}} -642.4$  HU and  $\text{threshold}_{\text{high}} 143$  HU.

%LC and %pneumonia of the whole lung from negative control and COVID-19 cohorts were  $1.4 \pm 0.62\%$  and  $8.13 \pm 4.39\%$  and statistically different with  $P < 0.001$  as shown in [Figure 4].

[Figure 5]: shows linear correlation analysis between %pneumonia obtained in pixel-by-pixel analysis method and opacity volume obtained from a commercially available AI-based algorithm from whole lungs for 50 COVID-19 cases. The correlation between %pneumonia and MEDIP was  $r = 0.604$  with slope =  $0.293$  and  $P < 0.001$ .

The lobar %LC values of negative control subjects and %pneumonia values of COVID-19 patients and the *P*-values between the lobes are shown in [Figures 6 and 7], respectively. There was no statistical difference in %pneumonia values between RUL, RML, and LUL ( $P > 0.05$ ) however RLL and LLL were statistically different from RUL, RML, and LUL with  $P < 0.05$ .

## DISCUSSION

Since COVID-19 disease is rapidly spreading, it is crucial to identify affected individuals in its early stages. Therefore, integrating computer programs into radiologists' workflow would have the potential to improve diagnostic outcomes related to COVID-19 pneumonia as well as quantification of pneumonia volumes for investigating the progression of the disease. In this study, the lobar measurement of %pneumonia in COVID-19 and %LC in negative control cohorts were investigated over the entire lungs using a CT attenuation windowing approach in an age-matched group, rather than the more common approach of using focal pneumonia clusters. The CT attenuation values associated with COVID-19 pneumonia were calculated to be  $\text{threshold}_{\text{low}} = -642$  HU and  $\text{threshold}_{\text{high}} = 143$  HU. Lobar analysis in our study showed a lower lobe predominance of disease, consistent with prior literature. Interestingly, our technique demonstrated that the %pneumonia difference between the lower and upper lobes was greater by a factor of two with the pixel CT attenuation analysis than clustered AI analysis in the literature.<sup>[13,24]</sup> These new

**Table 1:** Clinical characteristics of the patients (n =100).

	PARAMETER	VALUE	
		Negative Control	COVID-19
SEX	Male	n=24	n=34
	Female	n=26	n=16
AGE	Age Mean	46.40	52.02
	Age Standard Deviation	14.09	14.80
	Age Range	18– 72	20 – 79
SYMPTOMS	Fever		6
	Malaise & Fatigue		10
	Headache		1
	Cough		8
	Shortness of breath		1
	Nausea & Vomiting		1
	Sore throat		7
	Exposed (No Obvious Symptoms)		16

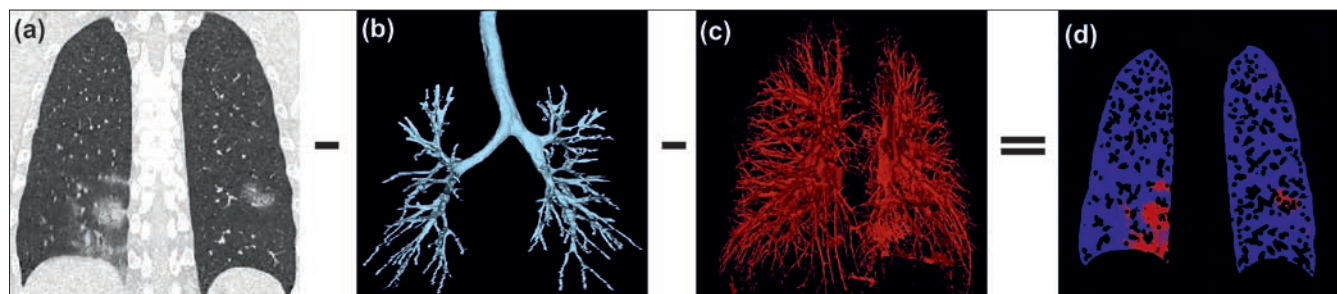
findings suggest that the pixel variations in CT attenuation may provide additional information for the assessment of COVID-19 pneumonia in addition to the deep learning analysis that focuses on the volumetric measurement of focal pneumonia clusters.

Although COVID-19 lesions have been studied with qualitative radiological and AI-based algorithms, the exact CT attenuation threshold values have not been reported previously. Previous analyses of COVID-19 related

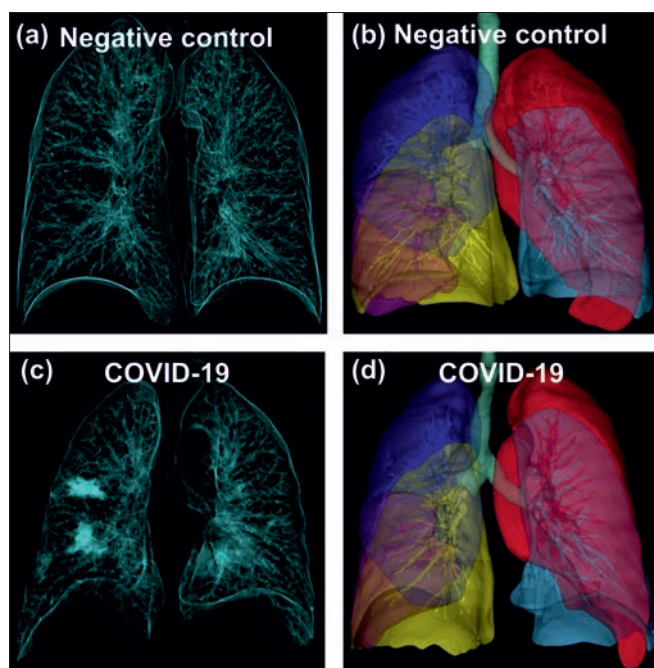
pneumonia have been performed using arbitrarily selected CT attenuation values. In our study, we performed a statistical analysis of 500 pixels selected from CT images and calculated the CT attenuation window to be between  $-642$  HU and  $143$  HU which may be considered as a standard threshold for the quantitative analysis of pneumonia.

Calculated pneumonia volume was similar between pixel-by-pixel analysis and existing AI techniques ( $r = 0.604$ ,  $P < 0.001$ ). This supports the reliability of pixel-by-pixel





**Figure 1:** (a) shows representative CT images of a COVID-19 patient (24-year-old, male), (b) Segmented airways of lung, (c) Segmented pulmonary vessels (d) A map of COVID-19 pneumonia for CT attenuation threshold values between  $-642.4$  HU and  $143$  HU.



**Figure 2:** (a) Forty-two-years old female within negative control cohort, (b) and lobar segmentation. (c) Sixty-five-years old male with a COVID-19, (d) and lobar segmentation.

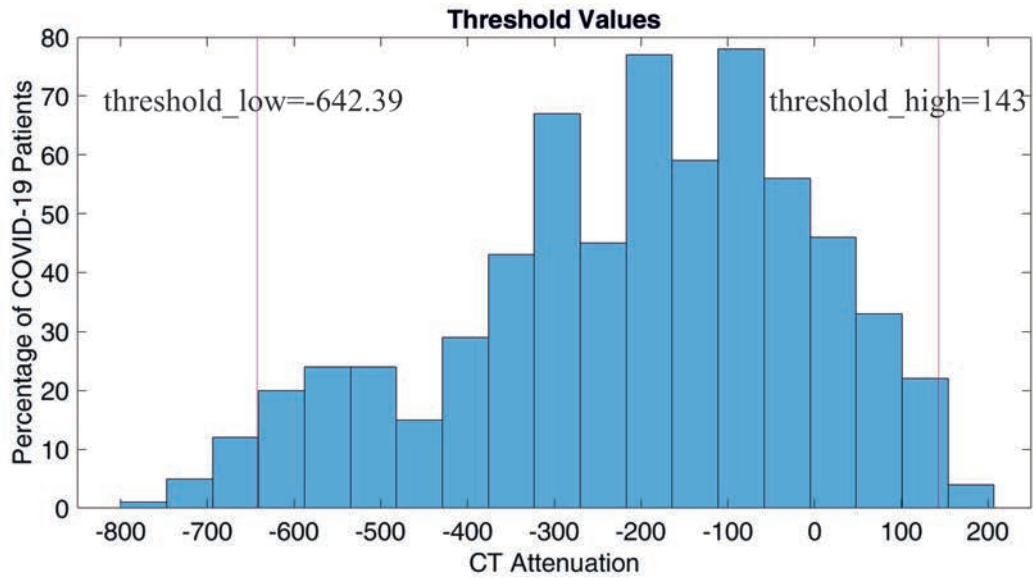
%pneumonia analysis. AI software was developed for the localization and measurement of COVID-19 lesions based on the extraction of local pneumonia features, such as patchy lesions and clustered GGO on CT images.<sup>[11,18,24,30]</sup> While the AI-based algorithms are reliable for the diagnosis of typical local image features, they may lead to a subjective assessment of only local pneumonia clusters, excluding the rest of the lung other than clusters. Changes in the pixel levels where the clusters did not develop may be overlooked by deep learning algorithms. Apart from the focal pneumonia cluster, we investigated lung infection in each pixel describing the %pneumonia condition as explained in Eq. (1). The %pneumonia analysis agreed with the previous studies suggesting that the lower lobes showed greater pneumonia. More interestingly, we found that the pixel-by-pixel analysis showed that the CT attenuation values, thereby, %pneumonia in the upper lobes was much greater than the deep learning

analysis. Specifically, the COVID-19 related pneumonia of RLL was greater than RUL by a factor of two suggesting that pixel changes may also need to be considered in the assessment of COVID pneumonia besides the focal CT features.

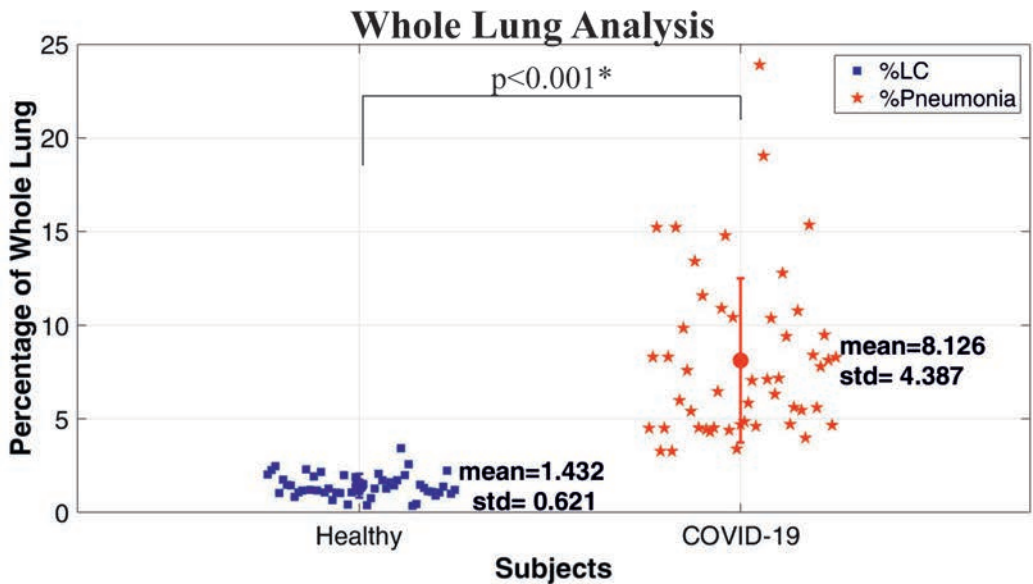
The proposed pixel-based technique showed that the incidence of COVID-19 related pneumonia was approximately a factor of two greater in the lower lobes than upper lobes. The quantitative methods used in this study produced an unexpectedly large estimate of lower lobe disease in COVID-19 patients in comparison with prior studies. Guan *et al.* reported a relatively higher incidence of pneumonia of the right lower lobe in the order of 72.34%, which was greater than the right upper lobe 61.7%, suggesting the difference is only 11% among 53 cases with COVID-19 however, 79% of COVID-19 patient is not considered.<sup>[13]</sup>

The proposed pixel-based pneumonia analysis in our study focused on the absolute volumetric measurement of %pneumonia rather than the incidence of focal pneumonia. In pixel-based analysis; airways, vessels, and soft tissues in the computed tomography images were excluded from the analysis to eliminate their impact on pneumonia calculations and to eliminate the difference and age factor between patients, the %LC was also calculated on an age-matched negative control cohort for the measurement of absolute changes in %pneumonia. Knowing the %LC values of the negative control cohort, the absolute COVID-19 pneumonia was quantified in this study rather than incidence over a COVID-19 patient cohort.

The reason for COVID-19 pneumonia has been examined in CT scans with lesions being more present in the lower lobes is thought that the right and left lower lobar bronchus being more straight resulting in the lower lobes more likely being infected. Since the COVID-19 is expected to cause diffusive alveolar damage based on the pathological findings the increased pneumonia in the lower lobe would be due to the extended parenchymal structures in the lower lobes.<sup>[31]</sup> Thought that the lower lobes are more likely to be infected due to higher ventilation capacity. Apart from focal cluster assessment of COVID-19 pneumonia, the CT



**Figure 3:** The distribution of CT attenuation values from the COVID-19 patient groups is how for finding the minimum and maximum threshold values.

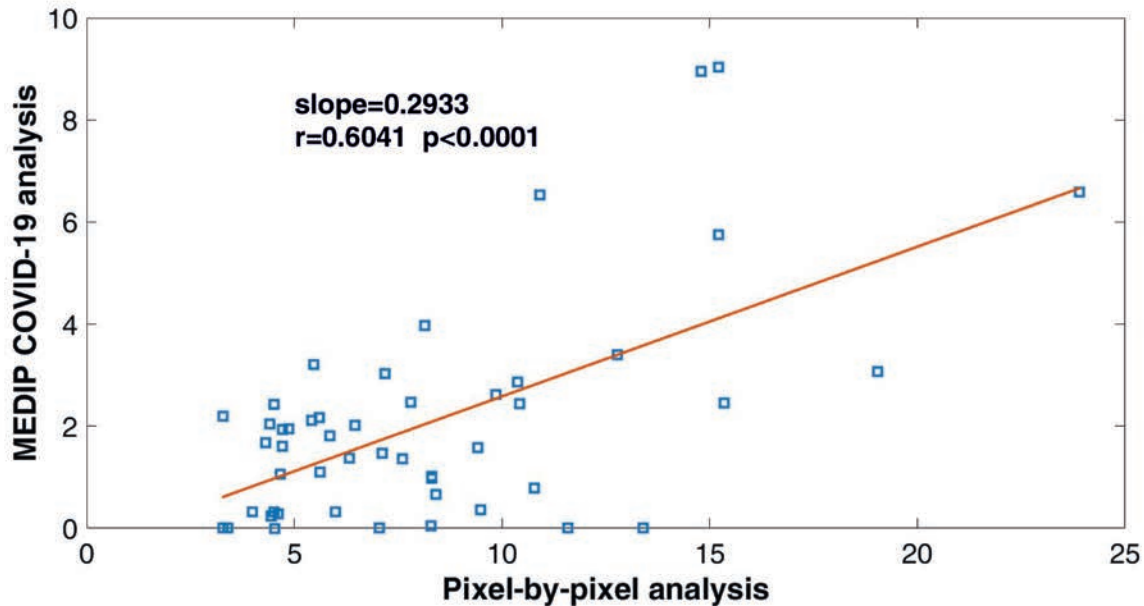


**Figure 4:** Lung Content (LC) and pneumonia in the whole lung from a negative control cohort n = 50 and COVID-19 cohort n = 50, respectively (\* statistically significant).

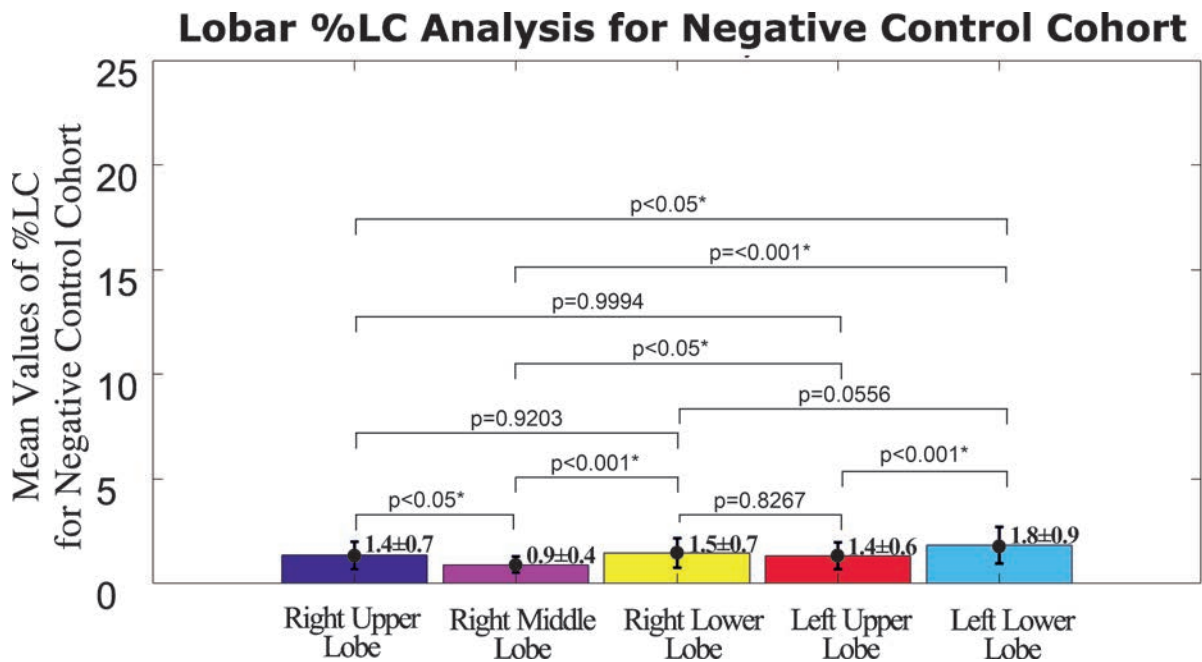
attenuation variations in pixels evaluation are expected to be associated with pathological changes in the alveolar levels, however, it is very difficult to correlate the pixel variation in millimeter resolution with alveolar changes due to COVID-19 pneumonia. Understanding of the chest CT radiological findings and correlation with bilateral diffuse alveolar damage requires further work that can be explained through numerical modeling<sup>[32]</sup> as well as pathological and histological findings are expected to the door to a new simulation platform and provide fundamental insight into COVID-19 pneumonia. In this respect, functional imaging

techniques including magnetic resonance hyperpolarized gas exchange and ventilation imaging in combination with the high-resolution CT and modeling are expected to reveal more information about the underlying mechanism of COVID-19 pneumonia in the future.<sup>[33,34]</sup>

This study has some limitations. COVID-19 is caused by a virus called coronavirus and may have some CT similarity to pneumonia caused by other viruses because GGO is usually defined as non-specific finding that is found in many types of pulmonary disease. However, in this study etiology for each



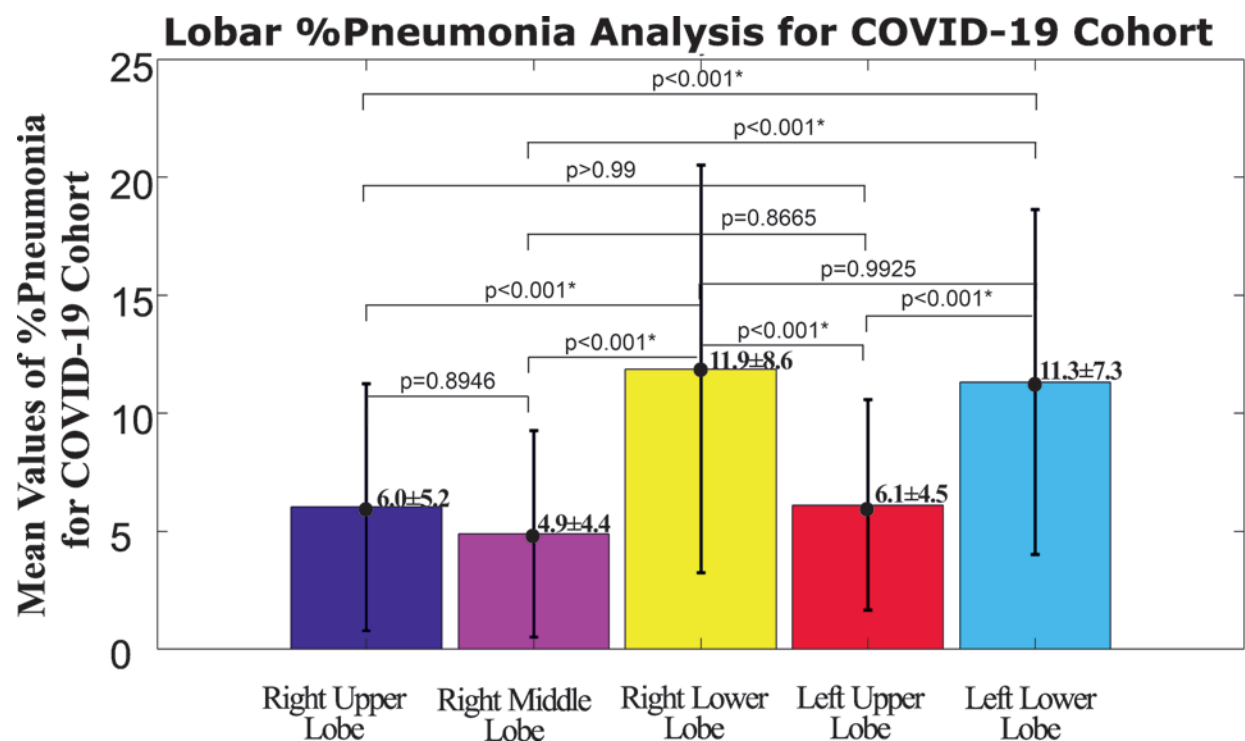
**Figure 5:** The linear regression of the whole lung scores between the %pneumonia pixel-by-pixel analysis and %pneumonia burden MEDIP COVID-19 analysis.



**Figure 6:** Lobar lung contents of the entire negative control cohort and ANOVA P-values for comparison between lobar lung content measurements are shown (\* statistically significant).

of these cases were selected as a positive RT-PCR test from March 2020 to May 2020. It should be also noted as another limitation that our model training could have benefited from a larger cohort size. In the future, we intend to increase our cohort with a longitudinal study of COVID-19 patients. Most of the studies worked with computer programs can

only detect the later stages of disease development. Our study presents a quantitative measurement of pneumonia percentage in every stage. The future application might also include a comparison of pixel-by-pixel analysis for other pulmonary diseases which cause pneumonia and data interpretation is needed.



**Figure 7:** Lobar pneumonia for COVID-19 cohort and ANOVA P-values for comparison between lobar pneumonia measurements are shown (\* statistically significant).

## CONCLUSION

Pixel-by-pixel analysis techniques that assess COVID-19 pulmonary disease burden are in agreement with AI-based algorithms. CT attenuation windows associated with COVID-19 related pneumonia typically range between  $-642.4$  HU and  $143$  HU. Pixel-by-pixel analysis may have improved sensitivity for the detection of upper lobe pneumonia in comparison to AI techniques.

Pixel-by-pixel analyses can accurately assess pneumonia in COVID-19 patients with CT. Pixel-based techniques produce more sensitive results than AI techniques. Using the proposed novel technique, %pneumonia could be quantitatively calculated not only in the clusters but also in the whole lung with an improved sensitivity by a factor of four compared to AI-based analysis. More significantly, pixel-by-pixel analysis was more sensitive to the upper lobe pneumonia, while AI-based analysis overlooked upper lung pneumonia regions.

So far, the quantitative analysis of COVID-19 pneumonia has been limited by the measurement of pneumonia cluster volumes with AI-based algorithms. The proposed study showed that the upper lobes may be more affected by pneumonia than those calculated by the AI algorithm. Therefore, the quantitative analysis of COVID-19 pneumonia will benefit from pixel-by-pixel analysis helping with the management of COVID-19 disease.

## ABBREVIATIONS

AI:	Artificial Intelligence
CT:	Computed Tomography
COVID-19:	Coronavirus Disease 2019
DICOM:	Digital Imaging and Communications in Medicine
GGO:	Ground Glass Opacity
HU:	Hounsfield Unit
LC:	Lung Content
RT-PCR:	Real-time-transcription-polymerase-chain-reaction
RUL:	Right Upper Lobe
RML:	Right Middle Lobe
RLL:	Right Lower Lobe
LUL:	Left Upper Lobe
LLL:	Left Lower Lobe
WHO:	World Health Organization

## Declaration of patient consent

Patient consent is not required as patient's identity is not disclosed or compromised.

## Financial support and sponsorship

This work was supported by TUBITAK 118C189.



**Conflict of interest**

There are no conflicts of interest.

**REFERENCES**

- Ding X, Xu J, Zhou J, Long Q. Chest CT findings of COVID-19 pneumonia by duration of symptoms. *Eur J Radiol* 2020;127:109009.
- Zhu N, Zhang D, Wang W, Li X, Yang B, Song J, *et al.* A novel coronavirus from patients with pneumonia in China, 2019. *N Engl J Med* 2020;382:727–33.
- Bai HX, Wang R, Xiong Z, Hsieh B, Chang K, Halsey K, *et al.* Artificial intelligence augmentation of radiologist performance in distinguishing COVID-19 from pneumonia of other origin at chest CT. *Radiology* 2020;296:E156–E65.
- Jin YH, Cai L, Cheng ZS, Cheng H, Deng T, Fan YP, *et al.* A rapid advice guideline for the diagnosis and treatment of 2019 novel coronavirus (2019-nCoV) infected pneumonia (standard version). *Mil Med Res* 2020;7:4.
- Palmisano A, Scotti GM, Ippolito D, Morelli MJ, Vignale D, Gandola D, *et al.* Chest CT in the emergency department for suspected COVID-19 pneumonia. *Radiol Med* 2020;126:498–502.
- Hani C, Trieu NH, Saab I, Dangeard S, Bennani S, Chassagnon G, *et al.* COVID-19 pneumonia: A review of typical CT findings and differential diagnosis. *Diagn Interv Imaging* 2020;101:263–8.
- Xie X, Zhong Z, Zhao W, Zheng C, Wang F, Liu J. Chest CT for Typical Coronavirus Disease 2019 (COVID-19) Pneumonia: Relationship to Negative RT-PCR Testing. *Radiology* 2020;296:E41–E5.
- Revel MP, Parkar AP, Prosch H, Silva M, Sverzellati N, Gleeson F, *et al.* COVID-19 patients and the radiology department - advice from the European Society of Radiology (ESR) and the European Society of Thoracic Imaging (ESTI). *Eur Radiol* 2020;30:4903–9.
- Li L, Qin L, Xu Z, Yin Y, Wang X, Kong B, *et al.* Using artificial intelligence to detect COVID-19 and community-acquired pneumonia based on pulmonary CT: Evaluation of the diagnostic accuracy. *Radiology* 2020;296:E65–E71.
- Wang S, Kang B, Ma J, Zeng X, Xiao M, Guo J, *et al.* A deep learning algorithm using CT images to screen for Corona Virus Disease (COVID-19). *Eur Radiol* 2021;31:6096–6104.
- Harmon SA, Sanford TH, Xu S, Turkbey EB, Roth H, Xu Z, *et al.* Artificial intelligence for the detection of COVID-19 pneumonia on chest CT using multinational datasets. *Nat Comm* 2020;11:4080.
- Huang C, Wang Y, Li X, Ren L, Zhao J, Hu Y, *et al.* Clinical features of patients infected with 2019 novel coronavirus in Wuhan, China. *Lancet* 2020;395:497–506.
- Guan CS, Lv ZB, Yan S, Du YN, Chen H, Wei LG, *et al.* Imaging features of Coronavirus disease 2019 (COVID-19): Evaluation on thin-section CT. *Acad Radiol* 2020;27:609–13.
- Ai T, Yang Z, Hou H, Zhan C, Chen C, Lv W, *et al.* Correlation of chest CT and RT-PCR testing for Coronavirus disease 2019 (COVID-19) in China: A report of 1014 cases. *Radiology* 2020;296:E32–E40.
- Cellina M, Orsi M, Pittino CV, Toluian T, Oliva G. Chest computed tomography findings of COVID-19 pneumonia: Pictorial essay with literature review. *Jpn J Radiol* 2020;38:1012–9.
- Cellina M, Martinenghi C, Marino P, Oliva G. COVID-19 pneumonia-ultrasound, radiographic, and computed tomography findings: A comprehensive pictorial essay. *Emerg Radiol* 2021;28:519–26.
- Malguria N, Yen LH, Lin T, Hussein A, Fishman EK. Role of chest CT in COVID-19. *J Clin Imag Sci* 2021;11:30
- Choi H, Qi X, Yoon SH, Park SJ, Lee KH, Kim JY, *et al.* Extension of Coronavirus disease 2019 on chest CT and implications for chest radiographic interpretation. *Radiology Cardiothoracic Imaging* 2020;2:e200107.
- Sergiacomi G, Ciccio C, Boi L, Velari L, Crusco S, Orlacchio A, *et al.* Ground-glass opacity: High-resolution computed tomography and 64-multi-slice computed tomography findings comparison. *Eur J Radiol* 2010;74:479–83.
- Austin JH, Muller NL, Friedman PJ, Hansell DM, Naidich DP, Remy-Jardin M, *et al.* Glossary of terms for CT of the lungs: recommendations of the Nomenclature Committee of the Fleischner Society. *Radiology* 1996;200:327–31.
- Yu H, Liu S, Zhang C, Li S, Ren J, Zhang J, *et al.* Computed tomography and pathology evaluation of lung ground-glass opacity. *Exp Ther Med* 2018;16:5305–9.
- Ridge CA, Bankier AA, Eisenberg RL. Mosaic attenuation. *AJR Am J Roentgenol* 2011;197:W970–7.
- Pedersen JH, Saghir Z, Wille MM, Thomsen LH, Skov BG, Ashraf H. Ground-glass opacity lung nodules in the era of lung cancer CT screening: radiology, pathology, and clinical management. *Oncology (Williston Park)* 2016;30:266–74.
- Zhang HT, Zhang JS, Zhang HH, Nan YD, Zhao Y, Fu EQ, *et al.* Automated detection and quantification of COVID-19 pneumonia: CT imaging analysis by a deep learning-based software. *Eur J Nucl Med Mol Imaging* 2020;47:2525–32.
- Shi H, Han X, Jiang N, Cao Y, Alwalid O, Gu J, *et al.* Radiological findings from 81 patients with COVID-19 pneumonia in Wuhan, China: A descriptive study. *Lancet Infect Dis* 2020;20:425–34.
- Chen J, See KC. Artificial intelligence for COVID-19: Rapid review. *J Med Internet Res* 2020;22:e21476.
- Naudé W. Artificial intelligence vs COVID-19: Limitations, constraints and pitfalls. *AI Soc* 2020;28:1–5.
- Alsharif W, Qurashi A. Effectiveness of COVID-19 diagnosis and management tools: A review. *Radiography (Lond)* 2021;27:682–7.
- Zach JA, Newell Jr JD, Schroeder J, Murphy JR, Curran-Everett D, Hoffman EA, *et al.* Quantitative computed tomography of the lungs and airways in healthy nonsmoking adults. *Invest Radiol* 2012;47:596–602.
- Grodecki K, Lin A, Cadet S, McElhinney PA, Razipour A, Chan C, *et al.* Quantitative burden of COVID-19 pneumonia on chest CT predicts adverse outcomes: A Post-Hoc Analysis of a Prospective International Registry. *Radiology Cardiothoracic Imaging* 2020;2:e200389.
- Haseli S, Khalili N, Bakhshayeshkaram M, Sanei Taheri M, Moharramzad Y. Lobar distribution of COVID-19

- pneumonia based on chest computed tomography findings; A retrospective study. *Arch Acad Emerg Med* 2020;8:e55.
32. Yoon SH, Kim M. Anterior pulmonary ventilation abnormalities in COVID-19. *Radiology* 2020;297:E276–E7.
  33. Doganay O, Matin T, Chen M, Kim M, McIntyre A, McGowan DR, *et al.* Time-series hyperpolarized xenon-129 MRI of lobar lung ventilation of COPD in comparison to V/Q-SPECT/CT and CT. *Eur Radiol* 2019;29:4058–67.
  34. Kim M, Doganay O, Matin TN, Povey T, Gleeson FV. CT-based airway flow model to assess ventilation in chronic obstructive pulmonary disease: a pilot study. *Radiology* 2019;293:666–73.

**How to cite this article:** Soya E, Ekenel N, Savas R, Toprak T, Bewes J, Doganay O. Pixel-based analysis of pulmonary changes on CT lung images due to COVID-19 pneumonia. *J Clin Imaging Sci* 2022;12:6.