



Musculoskeletal Imaging Pictorial Essay

# Hybrid Magnetic Resonance Imaging with Single Photon Emission Computed Tomography/Computed Tomography Bone Scan for Diagnosis Of Avascular Necrosis of Femoral Head

Fung Him Ng<sup>1</sup>, Terence Kin Bong Lai<sup>1</sup>, Sun Yu Lam<sup>1</sup>, Nin Yuan Pan<sup>1</sup>, Wing Hang Luk<sup>1</sup>

<sup>1</sup>Department of Radiology, Princess Margaret Hospital, Hong Kong.



**\*Correspondence author:**

Fung Him Ng,  
Department of Radiology,  
Princess Margaret Hospital,  
Hong Kong.

[ngphonehim@gmail.com](mailto:ngphonehim@gmail.com)

Received : 10 November 2020  
Accepted : 29 December 2020  
Published : 12 January 2021

DOI  
10.25259/JCIS\_205\_2020

Quick Response Code:



## ABSTRACT

Magnetic resonance imaging (MRI) is a commonly used imaging modality to detect early avascular necrosis (AVN). When MRI is inconclusive, bone scan is helpful in detecting AVN during early phase of the disease. As newer nuclear medicine equipment, such as single photon emission computed tomography/computed tomography (SPECT/CT) and positron emission tomography, are emerging in medical science, the role of these imaging modalities in AVN of femoral head is re-evaluated.

**Keywords:** Avascular necrosis, Bone scan, Hybrid, Magnetic resonance imaging, Single photon emission computed tomography/computed tomography

## INTRODUCTION

Avascular necrosis (AVN) or osteonecrosis is caused by inadequate blood supply leading to bone death, which results in the collapse of the architectural bony structure. AVN can be due to interruption of the vascular supply as a result of local trauma or non-traumatic systemic conditions, generally from corticosteroid use, trauma, pancreatitis, alcoholism, radiation, sickle cell disease, infiltrative diseases (e.g., Gaucher's disease), and Caisson disease.<sup>[1,2]</sup> Femoral head is the most common site involved and could be bilateral.<sup>[1]</sup> In the femoral head, site of necrosis is immediately below the weight bearing articular surface of the bone, that is, the anterolateral aspect of the femoral head.

Magnetic resonance imaging (MRI) is a commonly used imaging modality to detect early AVN.<sup>[3,4]</sup> When MRI is inconclusive, bone scan is helpful in detecting AVN during early phase of the disease. As newer nuclear medicine equipment, such as single photon emission computed tomography/computed tomography (SPECT/CT) and positron emission tomography (PET), are emerging in medical science, the role of these imaging modalities in AVN of femoral head is re-evaluated.

## TECHNIQUE

At our center, we performed SPECT/CT and MRI at the same session, with a single-photon emission CT imaging system (GE Healthcare, Discovery NM/CT 670) and Siemens MRI 1.5T.

This is an open-access article distributed under the terms of the Creative Commons Attribution-Non Commercial-Share Alike 4.0 License, which allows others to remix, tweak, and build upon the work non-commercially, as long as the author is credited and the new creations are licensed under the identical terms.

©2020 Published by Scientific Scholar on behalf of Journal of Clinical Imaging Science

20–25 mCi<sup>99m</sup>Tc methylene diphosphonate by intravenous injection for bone scintigraphy. Anterior planar images of the hips were obtained immediately after the injection for 1 min (perfusion phase with 1 s per film) and another 1 min (blood pooling) by SPECT/CT. Static-phase scan was performed in 3 h after injection with SPECT (rotation angle: 3° per step, at 15 s per frame, total 180° by dual detector, and acquired during rotation in noncircular orbit). The images were acquired into a 128 × 128 matrix and reconstructed using two-dimensional ordered-subset expectation maximization iterative technique and Gaussian three-dimensional post-filter. Low-dose CT scan was performed for the corresponding region for further correlation (1 mm collimation with reconstruction to 1.25 mm slice thickness, pitch 1.6, bone algorithm: 25 mAs, 130 kVp). Pinhole scan would be acquired with internal and external rotation view. Software with image fusion function was used for image analysis. Non-contrast MRI with metal signal reduction using two sequence – the coronal T1 and T2 with fat saturation in 3 mm slice thickness was then performed. The estimated time of scanning is 4–5 h.

## CASE PRESENTATION

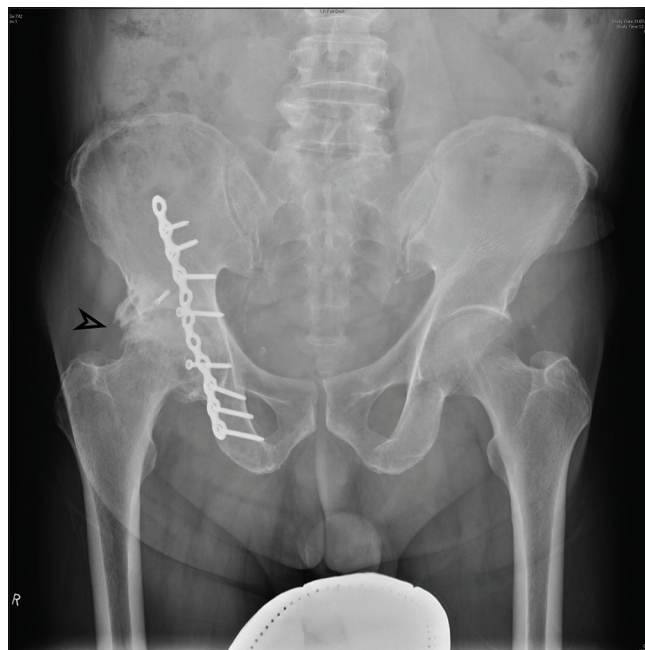In this manuscript, we present the role of hybrid MRI with SPECT/CT bone scan to diagnose AVN of the femoral head.

### Case 1

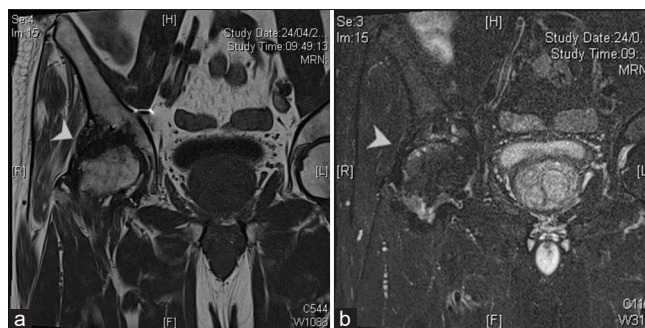
A 74-year-old gentleman with history of trauma with internal fixation of right posterior wall of acetabulum with predominately degenerative changes as shown in the radiograph [Figure 1] MRI right hip showed T1 hypointense signal and T2 hyperintense signal over the superior aspect of the femoral head and the hip joint, suggestive of degenerative and reactive changes. No definite T1 and T2 hypointense area to suggest AVN [Figure 2a and b]. Subchondral cysts over the acetabulum and femoral head [Figure 2b], it was doubtful that the subchondral cyst may be early subchondral collapse of the femoral head. Bone scan showed significant increase tracer uptake over the right hip joint particular the posterosuperolateral aspect [Figure 3]. Corresponding SPECT/CT showed marked degenerative changes with joint space narrowing, osteophytosis, and subchondral cyst formation. Bone remodeling with mild flattening of the femoral head surface likely related to the degeneration [Figures 4 and 5]. No definite photopenic area detected. Combining the scintigraphic, CT and MRI findings, it is confident to make the diagnosis of no vascular necrosis of femoral head with moderate hip degeneration.

### Case 2

A 71-year-old lady presented with history of trauma with cannulated screws for fracture right neck of femur. The femoral neck fracture healed with no definite femoral head

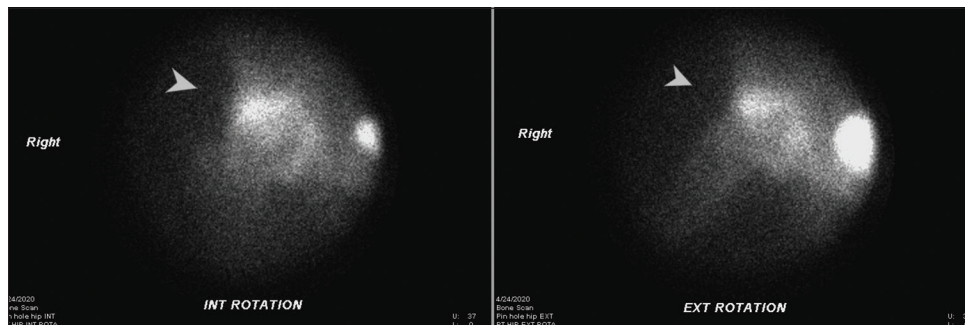


**Figure 1:** A 74-year-old man with trauma history presented with persistent hip pain. Pelvic radiograph showed evidence of internal fixation of right ilium with moderate hip degenerative changes. (arrow) It is equivocal to diagnose avascular necrosis of femoral head.

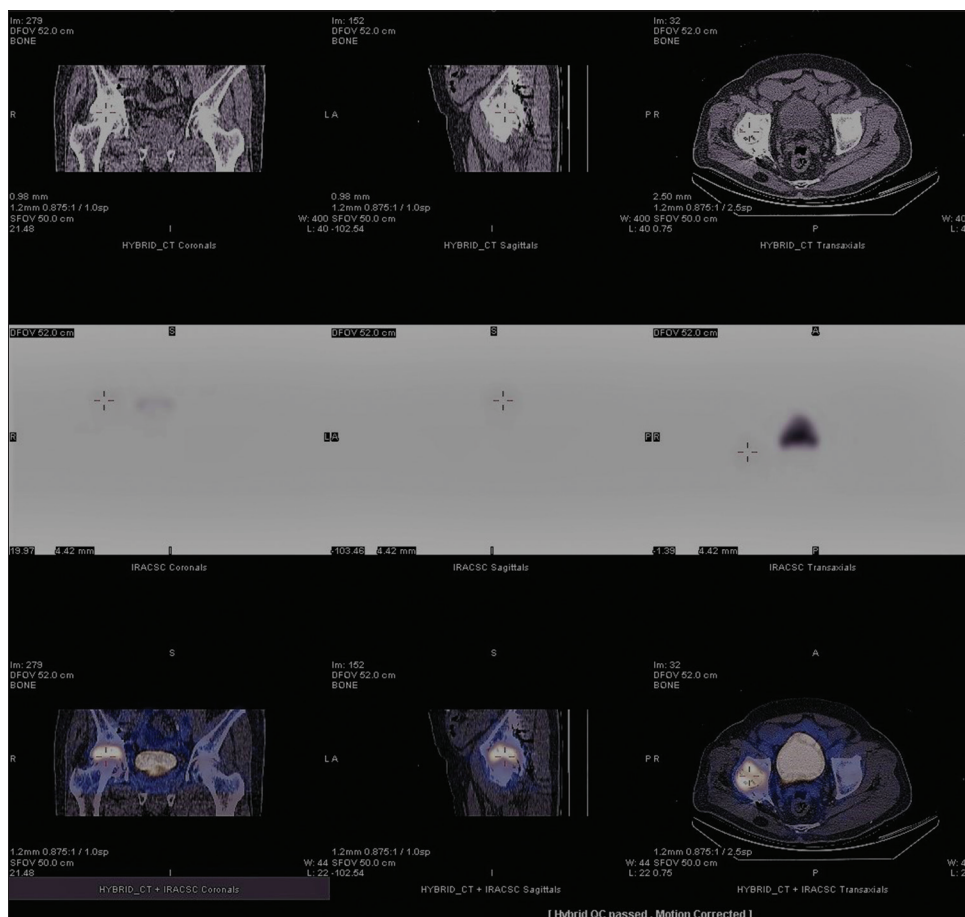


**Figure 2:** (a) A 74-year-old man with trauma history presented with persistent hip pain. MRI right hip showed T1 hypointense signal and T2 hyperintense signal over the superior aspect of the femoral head and the hip joint, suggestive of degenerative and reactive changes. (arrow) No definite T1 and T2 hypointense area to suggest avascular necrosis. (b) No definite T1 and T2 hypointense area to suggest avascular necrosis. Subchondral cysts over the acetabulum and femoral head.

collapse detected in the radiograph [Figure 6]. Bone scan showed moderate increase tracer uptake over the femoral head [Figure 7]. Corresponding SPECT/CT showed mild degenerative changes with joint space narrowing and osteophytosis, likely related to the degenerative and reactive changes. There is a tiny faint photopenic area in the right femoral head. Corresponding CT showed a small area of subchondral lucency surrounded with bone sclerosis [Figure 8].



**Figure 3:** A 74-year-old man with trauma history presented with persistent hip pain. Bone scan (pinhole) showed significant increase tracer uptake over the right hip joint particular the posterior superolateral aspect (arrow).



**Figure 4:** A 74-year-old man with trauma history presented with persistent hip pain. SPECT/CT showed marked degenerative changes with joint space narrowing, osteophytosis, and subchondral cyst formation. Bone remodeling with mild flattening of the femoral head surface likely related to the degeneration. No definite photopenic area detected (pointer).

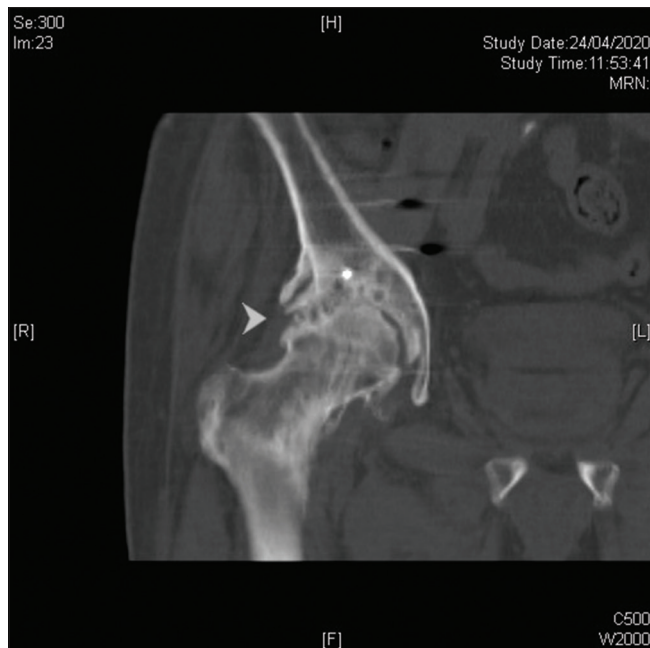It is inconclusive to make a confident diagnosis as sometimes subchondral cyst related to degenerative may give rise to similar appearance. MRI hip showed a 1.2 cm hypointense signal on T1 with double line sign on T2 over the superior aspect of right femoral head features are suspicious of early AVN. The femoral head contour is smooth with no significant collapse of the femoral head [Figure 9a and b]. Combining the scintigraphic,

CT and MRI findings, it is confident to make the diagnosis of early vascular necrosis of femoral head.

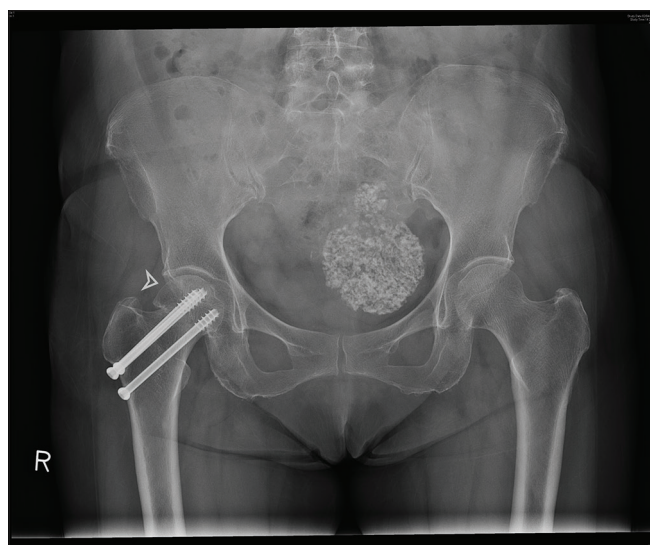## DISCUSSION

AVN or osteonecrosis is caused by inadequate blood supply leading to bone death, which results in the collapse of the

architectural bony structure. AVN can be due to interruption of the vascular supply as a result of local trauma or non-traumatic systemic conditions,<sup>[1]</sup> generally from corticosteroid use, trauma, pancreatitis, alcoholism, radiation, sickle cell disease,



**Figure 5:** A 74-year-old man with trauma history presented with persistent hip pain. CT showed marked degenerative changes with joint space narrowing, osteophytosis and subchondral cyst formation. Bone remodeling with mild flattening of the femoral head surface likely related to the degeneration (arrow).



**Figure 6:** A 71-year-old lady with trauma history presented with persistent hip pain. Pelvic radiograph showed cannulated screws for fracture right neck of femur, with mild hip degenerative changes (arrow). It is equivocal to diagnose avascular necrosis of femoral head.

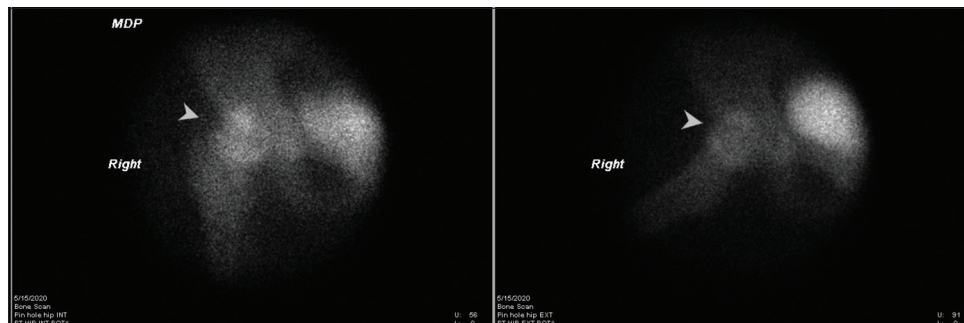
infiltrative diseases (e.g., Gaucher's disease), and Caisson disease.<sup>[1,2]</sup> Femoral head is the most common site involved and could be bilateral.<sup>[1]</sup> In the femoral head, site of necrosis is immediately below the weight bearing articular surface of the bone, that is, the anterolateral aspect of the femoral head.

In the literature, there have been more than ten different classifications described for AVN, most of them based on MRI and radiographs. The disease classification allows determining a prognosis and gives an orientation in the treatment options. The most commonly used classification is Steinberg's classification.<sup>[5]</sup> The Steinberg's classification, developed in the early 1980s, identified seven distinct stages, incorporated both technetium scans and MRI, and included a specific measurement of lesion size in both early and late stages [Table 1]. It was the first to use MRI as a specific modality for determining stage and incorporate a method for measuring lesion size as an integral part of the system. Lesion dimensions on plain radiographs and MRIs in the same hips were compared and found to be similar. It included the symptomatology especially in terms of worsening or persistent pain, which may be used to differentiate the pre-collapse from post-collapse lesion. The majority of the lesions were in the weight-bearing region. Therefore, there was no separate category for location of the lesion.

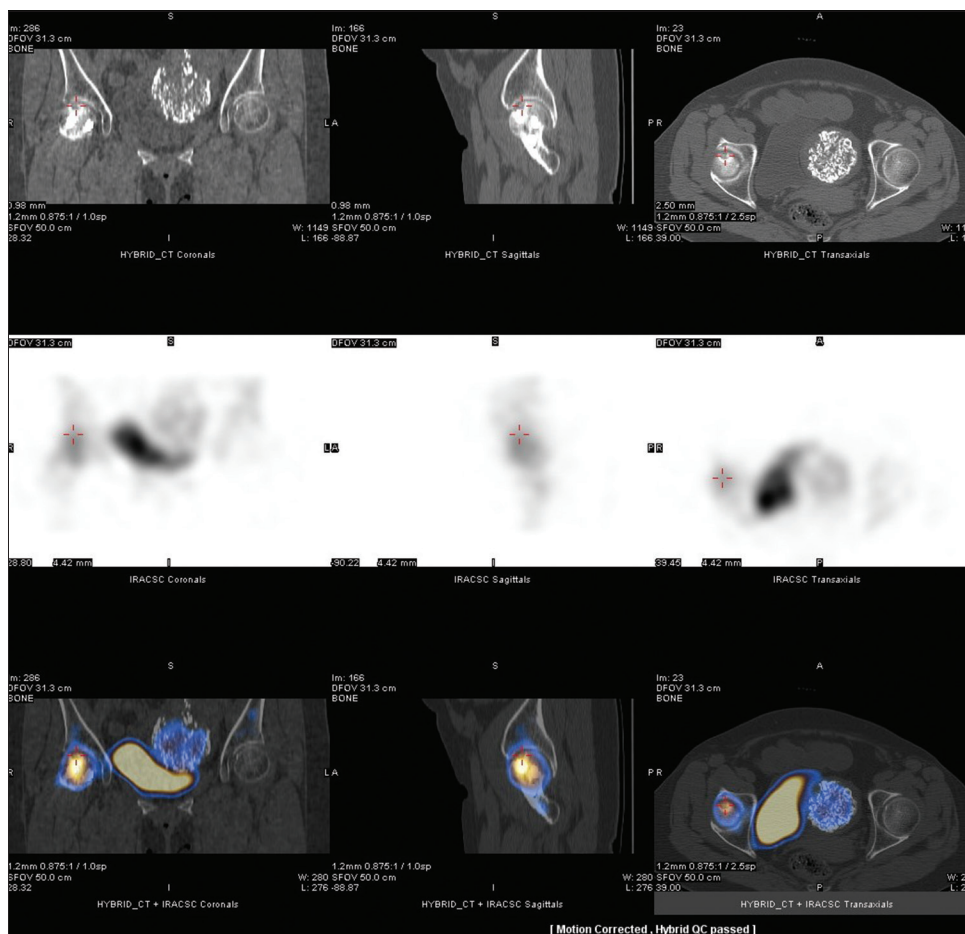
Early diagnosis and treatment remains the key for hip preservation in AVN. Till date, MRI is considered as the gold standard diagnostic modality for AVN.<sup>[6]</sup> However, with the improvement in nuclear imaging technique, the disease can be diagnosed even at a very early stage. Available literature suggests that SPECT/CT bone scan and 18F-fluoride photon emission CT/CT have similar or better results in comparison to MRI in AVN of the femoral head.<sup>[7-9]</sup> Nuclear imaging also provides both morphological and metabolic information in the disease part and hence can indicate whether the disease is active or healed.<sup>[10]</sup>

**Table 1:** Steinberg Classification System for femoral head avascular necrosis.

| Stage | Findings  |
|-------|---|
| 0     | No symptoms<br>Normal radiograph<br>MRI non-specific<br>Mild pain in the affected hip. or pain with internal rotation |
| 1     | Normal radiograph<br>MRI diagnostic<br>Worsening or persistent pain   |
| 2     | Increased sclerosis or cysts in the femoral head  |
| 3     | Subchondral collapse (crescent sign)<br>Flattening of the femoral head  |
| 4     | Normal joint space  |
| 5     | Narrowing of the joint space with/without femoral head involvement  |
| 6     | Advanced degenerative changes   |



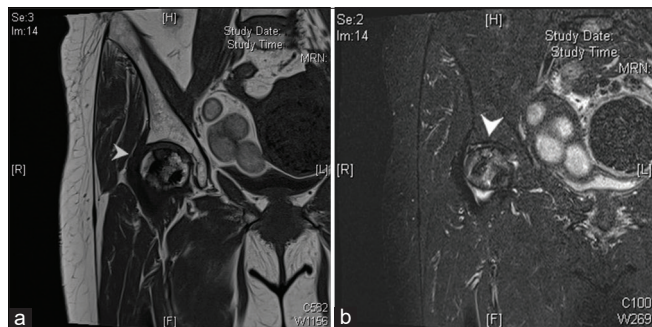
**Figure 7:** A 71-year-old lady with trauma history presented with persistent hip pain. Bone scan (pinpole) showed moderate increase tracer uptake over the femoral head (arrow).



**Figure 8:** A 71-year-old lady with trauma history presented with persistent hip pain. SPECT/CT showed mild degenerative changes with joint space narrowing and osteophytosis, likely related to the degenerative and reactive changes. There is a tiny faint photopenic area in the right femoral head. Corresponding CT showed a small area of subchondral lucency surrounded with bone sclerosis (pointer).

SPECT images reflect vascular integrity. SPECT scans may demonstrate an avascular focus early in the disease; such findings are often missed with MRI. Collier found a sensitivity of 85% for SPECT.<sup>[11]</sup> With triple-head high-resolution SPECT, Lee *et al.* reported a sensitivity of 97%.<sup>[12]</sup> A cold spot (photon-deficient region) within the femoral head is highly specific for AVN and is the earliest

scintigraphic evidence of AVN. This usually is seen 7–10 days after the ischemic event. Over a period of weeks to months, increased uptake representing revascularization and repair surrounds and eventually replaces the region of photopenia. The central region of photopenia with surrounding zone of increased uptake is termed the doughnut sign.



**Figure 9:** (a and b) A 71-year-old lady with trauma history presented with persistent hip pain. MRI hip showed a 1.2 cm hypointense signal on T1 with double line sign on T2 over the superior aspect of right femoral head (arrows). Features suspicious of early avascular necrosis. The femoral head contour is smooth with no significant collapse of the femoral head.

## CONCLUSION

Imaging plays a crucial role in early diagnosis of AVN of the femoral head. Although MRI is a commonly used modality in detecting AVN, nuclear medicine imaging technology such as SPECT/CT bone scan and 18F-fluoride PET/CT could demonstrate similar or better results in comparison to MRI in AVN of the femoral head and serve a complimentary role in equivocal case.

## Declaration of patient consent

Patient's consent not required as patients identity is not disclosed or compromised.

## Financial support and sponsorship

Nil.

## Conflicts of interest

There are no conflicts of interest.

## REFERENCES

1. Assouline-Dayan Y, Chang C, Greenspan A, Shoenfeld Y, Gershwin ME. Pathogenesis and natural history of

- osteonecrosis. *Semin Arthritis Rheum* 2002;32:94-124.
2. Murphey MD, Foreman KL, Klassen-Fischer MK, Fox MG, Chung EM, Kransdorf MJ. From the radiologic pathology archives imaging of osteonecrosis: Radiologic-pathologic correlation. *Radiographics* 2014;34:1003-28.
3. Genez BM, Wilson MR, Houk RW, Weiland FL, Unger HR Jr., Shields NN, *et al.* Early osteonecrosis of the femoral head: Detection in high-risk patients with MR imaging. *Radiology* 1988;168:521-4.
4. Vande Berg BE, Malghem JJ, Labaisse MA, Noel HM, Maldague BE. MR imaging of avascular necrosis and transient marrow edema of the femoral head. *Radiographics* 1993;13:501-20.
5. Steinberg ME, Hayken GD. A quantitative system for staging avascular necrosis. *J Bone Joint Surg Br* 1995;77:34-41.
6. Stevens K, Tao C, Lee SU, Salem N, Vandevonne J, Cheng C, *et al.* Subchondral fractures in osteonecrosis of the femoral head: Comparison of radiography, CT, and MR imaging. *AJR Am J Roentgenol* 2003;180:363-70.
7. Koo KH, Kim R, Cho SH, Song HR, Lee G, Ko GH. Angiography, scintigraphy, intraosseous pressure, and histologic findings in high-risk osteonecrotic femoral heads with negative magnetic resonance images. *Clin Orthop Relat Res* 1994;308:127-38.
8. Ryu JS, Kim JS, Moon DH, Kim SM, Shin MJ, Chang JS, *et al.* Bone SPECT is more sensitive than MRI in the detection of early osteonecrosis of the femoral head after renal transplantation. *J Nucl Med* 2002;43:1006-11.
9. Gayana S, Bhattacharya A, Sen RK, Singh P, Prakash M, Mittal BR. F-18 fluoride positron emission tomography/computed tomography in the diagnosis of avascular necrosis of the femoral head: Comparison with magnetic resonance imaging. *Indian J Nucl Med* 2016;31:3-8.
10. Agrawal K, Marafi F, Gnanasegaran G, Van der Wall H, Fogelman I. Pitfalls and limitations of radionuclide planar and hybrid bone imaging. *Semin Nucl Med* 2015;45:347-72.
11. Collier BD, Carrera GF, Johnson RP, Isitman AT, Hellman RS, Knobel J, *et al.* Detection of femoral head avascular necrosis in adults by SPECT. *J Nucl Med* 1985;26:979-87.
12. Lee MH, Moon DH, Na HW. Diagnosis of femoral head avascular necrosis by triple head high resolution. *J Nucl Med* 1992;33:936-41.

**How to cite this article:** Ng FH, Lai TK, Lam SY, Pan NY, Luk WH. Hybrid magnetic resonance imaging with single photon emission computed tomography/computed tomography bone scan for diagnosis of avascular necrosis of femoral head. *J Clin Imaging Sci* 2021;11:2.