



Musculoskeletal Imaging Case Report

## Hawkins sign of the knee: Imaging appearance and clinical implication of an unusual pattern of disuse osteopenia

Nicholas C. Adams<sup>1</sup>, Robin L. Alonge<sup>1</sup>, Lance D. Edmonds<sup>1</sup>

<sup>1</sup>Department of Radiology, David Grant Medical Center, Fairfield, California, United States.



**\*Corresponding author:**  
Nicholas C. Adams,  
Department of Radiology,  
David Grant Medical  
Center, Fairfield, California,  
United States.

nadams04@gmail.com

Received : 27 March 2022

Accepted : 09 August 2022

Published : 22 August 2022

DOI  
10.25259/JCIS\_33\_2022

Quick Response Code:



### ABSTRACT

Disuse osteopenia (DO) is a disorder due to reduced weight-bearing often following immobilization injuries. It is most commonly observed in the ankles and knees and is believed to be due primarily to increased bone reabsorption associated with disuse. Both traditional radiography and magnetic resonance (MR) imaging are useful in identifying abnormalities associated with DO. Specifically, linear subchondral osteopenia has been given the term “Hawkins sign” when seen in the talus, but this finding may also be seen elsewhere. When present, it not only is an indication of DO but also indicates the presence of sufficient vascular flow, and the unlikely development of avascular necrosis. We report a case of Hawkins sign of the knee demonstrated on radiography and MR and demonstrate the clinical importance of recognizing this sign, outside its usual setting, in assessing the prognosis of a healing fracture.

**Keywords:** Hawkins sign, Disuse osteopenia, Knee

### INTRODUCTION

Although the pathogenesis is not entirely understood, disuse osteopenia (DO) is a known phenomenon associated with reduced weight-bearing as seen in the setting following a fracture.<sup>[1]</sup> Linear subchondral DO is a characteristic pattern commonly observed following a talus fracture.<sup>[2]</sup> This presents on radiographs as a subchondral radiolucent line, known as “Hawkins sign,” and is the result of active bone resorption which is dependent on a hyperemic state in the disused bone.<sup>[1,2]</sup> This hyperemia appears on magnetic resonance (MR) imaging as T2 hyperintense signal.<sup>[3]</sup> Seen approximately 6–8 weeks after trauma, it is an indicator of an intact vascular supply and an unlikely progression to avascular necrosis.<sup>[4]</sup> This pattern of DO is reported less frequently outside the talar dome. We report a case of isolated subchondral DO seen within the knee, a “Hawkins sign” of the knee.

### CASE REPORT

A 22-year-old otherwise healthy male military member sustained a severe right knee injury including knee dislocation and subsequent relocation. The patient ambulated only with crutches for the following 6 weeks. On presentation to the orthopedic surgeon, he reported pain with

This is an open-access article distributed under the terms of the Creative Commons Attribution-Non Commercial-Share Alike 4.0 License, which allows others to remix, transform, and build upon the work non-commercially, as long as the author is credited and the new creations are licensed under the identical terms.

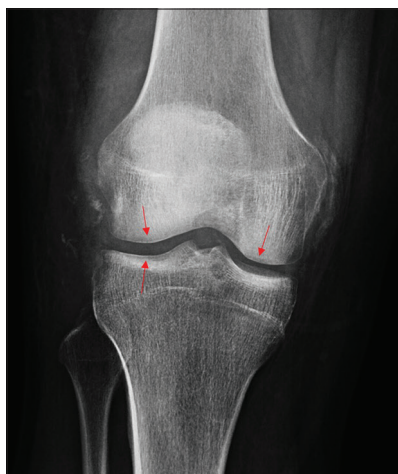©2022 Published by Scientific Scholar on behalf of Journal of Clinical Imaging Science

ambulation and inability to bear full weight secondary to pain and instability. Physical examination demonstrated a large right knee effusion, diffuse joint line tenderness, limited range of motion in flexion and extension, varus laxity, a positive anterior drawer sign, and positive pivot shift.

Knee radiographs revealed a knee effusion and sequelae of impaction injury involving the medial femoral condyle. In addition, faint linear demineralization was observed involving the medial femoral condyle, lateral femoral condyle, and lateral tibial plateau [Figure 1]. Subsequent MR imaging demonstrated findings consistent with severe posterolateral corner injury, sequelae of knee dislocation including impaction fracture of the medial femoral condyle, complete tearing of the anterior and posterior cruciate ligaments, and partial tearing of the medial collateral ligament. Additionally seen was linear increased T2 signal underlying the cartilage in all three compartments, suggestive of hyperemia in the setting of disuse osteopenia [Figure 2].

## DISCUSSION

DO may manifest in any setting of reduced weight-bearing, including fractures, inactivity, neuromuscular, and arthritic diseases. Although the exact pathogenesis is not entirely understood, some studies have indicated it likely begins with a hyperemic state in the disused bone and are followed by active bone resorption accompanied by inhibition of bone formation.<sup>[1,5-7]</sup> This has caused



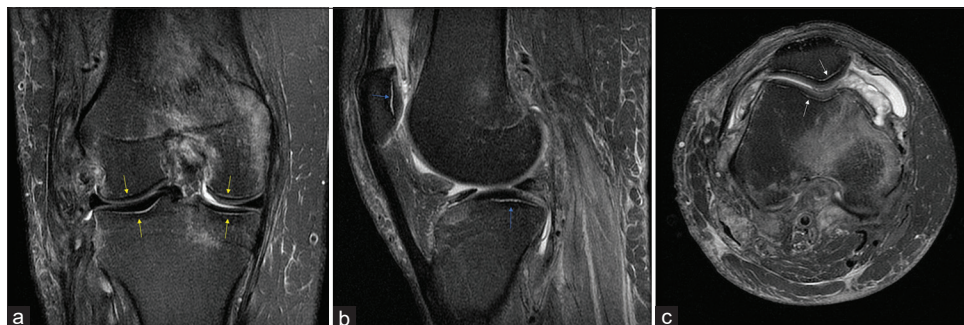
**Figure 1:** A 22-year-old male after 6 weeks inability to bear full weight, subsequent to knee dislocation. Frontal radiograph of the right knee shows impaction fracture of the medial femoral condyle. Linear demineralization is seen involving the medial femoral condyle, lateral femoral condyle, and lateral tibial plateau (red arrows).

it to be considered a “high turnover osteoporosis.”<sup>[3]</sup> DO changes first become evident after approximately 6–8 weeks of disuse, with earlier observations noted in younger populations.<sup>[3]</sup> Although, peak bone mass deficit has been reported to occur as long as 4 months after the immobilizing injury occurred.<sup>[1,3]</sup> Very commonly, bone mass may be recovered if the patient resumes activity within the active phase of DO. However, there may be no regeneration of bone for as long as 1 year following the original period of immobilization.<sup>[3]</sup>

Leland Hawkins first described three patterns of talar neck injury in 1970.<sup>[8]</sup> He described a band-like pattern of subchondral osteopenia involving the talar dome after talar fractures, which has been subsequently referred to as “Hawkins sign.” Hawkins noted that this pattern of DO was most evident on AP radiographs and could be missed on lateral films.<sup>[9]</sup> The development of the subchondral osteopenia is dependent on active hyperemia in the immobilized joint and its high prevalence within the ankle is believed to be due to the nature of the high vascularity of the ankle.<sup>[2,9]</sup> Thus, the “Hawkins sign” has clinical significance as its presence indicates sufficient vascularity within the injured osseous structure and subsequently a decreased risk of the development of avascular necrosis.<sup>[8]</sup>

Traditional radiography and MR imaging have both proved useful in visualizing DO. Visualization of DO is most commonly seen in the ankle and knee, though it has also been described in other locations to include the wrist, shoulder, and spine.<sup>[3,6-7]</sup> Within the knee, the most common sites include the femur and patella.<sup>[1]</sup> A common radiographic appearance of DO is band-like subchondral osteopenia, which is classically seen in the talar dome following a talar neck fracture.<sup>[2]</sup> MR findings of DO include accentuation of vertical trabecular lines, presence of subchondral lobules of fat, presence of horizontal trabecular lines, prominence of bone vessels, and presence of dotted areas of high signal intensity on T2-weighted fat-suppressed sequences.<sup>[1,3]</sup> One study of patients with clinical and radiographic evidence of DO found 100% of patients (16/16) showed evidence of osseous demineralization on MR imaging.<sup>[3]</sup> Increased T2 signal seen in a linear, subchondral distribution reflects hyperemia secondary to prominent vasculature and acts as the corresponding MR finding to a subchondral lucency seen on radiographs.<sup>[3]</sup>

The patient discussed in this case sustained a severe knee injury, resulting in inability to bear weight on his right knee over the 6-week period between injury and imaging. During this time, DO developed in an isolated subchondral distribution. Both radiography and MR imaging revealed this unexpected yet reassuring sign. The patient later underwent arthroscopy with orthopedic surgery, with reconstruction of the cruciate ligaments and



**Figure 2:** Same patient as above. Images from non-contrast knee magnetic resonance imaging. (a) Coronal T2 fat-saturated imaging shows band-like subchondral T2 hyperintensity involving the femoral condyles and tibial plateau (yellow arrows). Also demonstrated was complete tearing of the ACL and PCL, partial tearing of the MCL, and an impaction fracture of the medial femoral condyle, (b) sagittal proton-density fat-saturated imaging shows band-like subchondral T2 hyperintensity involving the patella and lateral tibial plateau (blue arrows), (c) axial proton-density fat-saturated imaging shows band-like subchondral T2 hyperintensity involving the patella and trochlear groove (white arrows). Additionally there is an impaction fracture of the anterior medial femoral condyle with subperiosteal hematoma formation.

posterolateral corner using allograft, and is following an expected postoperative course.

## CONCLUSION

DO is commonly seen in the setting of prolonged immobilization after a traumatic injury and can present in a variety of distributions. A band-like subchondral distribution is frequently described involving the talar dome, but can also be found elsewhere in the body. This finding reflects increased bone resorption dependent on intact vasculature and therefore a lower risk for the development of avascular necrosis. This case demonstrates the importance for awareness among radiologists and orthopedic surgeons to recognize this sign in determination of prognosis following a fracture with a period of prolonged immobility.

## Disclaimer

The views expressed in this manuscript are those of the authors and do not reflect the official policy or position of the Department of the Air Force, Department of Defense, or the US Government.

## Declaration of patient consent

Patient's consent not required as patient's identity is not disclosed or compromised.

## Financial support and sponsorship

Nil.

## Conflicts of interest

There are no conflicts of interest.

## REFERENCES

1. Nardo L, Sandman DN, Virayavanich W, Zhang L, Souza R, Steinbach L, *et al.* Bone marrow changes related to disuse. *Eur Radiol* 2013;23:3422-31.
2. Donnelly EF. The Hawkins sign. *Radiology* 1999;210:195-6.
3. De Abreu MR, Wessely M, Chung CB, Resnick D. Bone marrow MR imaging findings in disuse osteoporosis. *Skeletal Radiol* 2010;40:571-5.
4. Hawkins LG. Fractures of the neck of the talus. *J Bone Joint Surg* 1970;52:991-1002.
5. Gross TS, Damji AA, Judex S, Bray RC, Zernicke RF. Bone hyperemia precedes disuse-induced intracortical bone resorption. *J Appl Physiol* 1999;86:230-5.
6. Marchetti ME, Houde JP, Steinberg GG, Crane GK, Goss TP, Baran DT. Humeral bone density losses after shoulder surgery and immobilization. *J Shoulder Elbow Surg* 1996;5:471-6.
7. Poole KE, Warburton EA, Reeve J. Rapid long-term bone loss following stroke in a man with osteoporosis and atherosclerosis. *Osteoporos Int* 2005;16:302-5.
8. Pearce DH, Mongiardi CN, Fornasier VL, Daniels TR. Avascular necrosis of the talus: A pictorial essay. *Radiographics* 2005;25:399-410.
9. Gossner J, Raab BW, Larsen J, Breitzkreuz S. Marked subchondral bandlike osteopenia on radiography after trauma and inactivity: A report of four cases. *Case Rep Orthop* 2013;2013:234278.

**How to cite this article:** Adams NC, Alonge RL, Edmonds LD. Hawkins sign of the knee: Imaging appearance and clinical implication of an unusual pattern of disuse osteopenia. *J Clin Imaging Sci* 2022;12:51.