

CASE REPORT

Wassel’s Type V Polydactyly with Plain Radiographic and CT Findings

Berna Dirim Mete, Canan Altay¹, Merve Gursoy, Orhan Oyar

Department of Radiology, University of Katip Celebi Ataturk Training and Research Hospital, ¹Department of Radiology, University of Dokuz Eylul, Izmir, Turkey

Address for correspondence:

Dr. Merve Gursoy,
 University of Katip Celebi Ataturk Training and Research Hospital,
 Basin Sitesi, Izmir, Turkey.
 E-mail: gursoymerve@yahoo.com



Dr. Berna Dirim Mete

Received : 25-01-2015
Accepted : 09-03-2015
Published : 25-03-2015

ABSTRACT

Duplication of the thumb is the most common polydactyly of the hand. Wassel’s classification is frequently used to classify the polydactyly of the hand. His classification was based on the level of duplication and the number of bones in the thumb, and has seven groups (Types I–VII) according to the level of the bifurcation, except for his Type VII. The most common type is the bifurcation at the metacarpophalangeal joint (Type IV). In this paper, we report a very rare case of Type V thumb polydactyly in a 42-year-old man, who presented with swan neck deformity of the radial thumb and discuss the plain radiography and computed tomography (CT) findings. Kumar recently reported plain radiography findings in a case of bifid first metacarpal in a 13-year-old girl, who presented with swan neck deformity of the left thumb. To our knowledge, our case is the second presented case that has a swan neck deformity with bifid metacarpal.

Key words: Computed tomography, plain radiograph, polydactyly, swan neck deformity

INTRODUCTION

Duplication of the thumb is the most common polydactyly of the hand.^[1] According to its anatomical location, polydactyly can be generally subdivided into pre- and post-axial forms. There is a gene responsible for pre-axial polydactyly Types II and III as well as for complex polysyndactyly, which is located on chromosome 7q36.^[2]

Pre-axial polydactyly occurs sporadically with an incidence of 8 in 100,000 in both African and Caucasian populations.^[3] The appearance of the duplicated thumb depends on the changes in the skeletal and soft-tissue structures, which vary with the level of the bifurcation and extent of the duplication.

Several classifications have been proposed, among these Wassel’s classification is currently being widely used in the clinical field.^[4] In 1969, Wassel studied 70 hands and identified seven types of thumb duplication. His classification was based on the level of duplication and the number of bones in the thumb. The classification has seven groups (Types I–VII) according to the level of the bifurcation, except for his Type VII. The operative findings in these 70 hands demonstrated that the tendons were duplicated to the same degree as the bones. Therefore, a classification based on the extent of the bifurcation of the bone structures

Access this article online	
Quick Response Code:	Website: www.clinicalimagingscience.org
	DOI: 10.4103/2156-7514.153974

Copyright: © 2015 Mete BD. This is an open-access article distributed under the terms of the Creative Commons Attribution License, which permits unrestricted use, distribution, and reproduction in any medium, provided the original author and source are credited.

This article may be cited as:
 Mete BD, Altay C, Gursoy M, Oyar O. Wassel’s Type V Polydactyly with Plain Radiographic and CT Findings. J Clin Imaging Sci 2015;5:16.
 Available FREE in open access from: <http://www.clinicalimagingscience.org/text.asp?2015/5/1/16/153974>

proved to be useful for planning surgical treatment.^[4] Type I consists of a bifid distal phalanx, while complete duplication of the distal phalanx is considered as Type II. Type III consists of a bifid proximal phalanx with duplication of the distal phalanx, while complete duplication of the proximal and distal phalanges is considered as Type IV. Type V is a duplication of proximal and distal phalanges with a bifid metacarpal, while complete duplication of the phalanges and metacarpal is considered as Type VI. Type VII consists of thumb duplication with a triphalangeal component [Figure 1].

Bifurcation at the metacarpophalangeal joint (Type IV) is the most common type. Duplication of the thumb is usually unilateral. Only 9 out of 70 patients in Wassel's series had bilateral involvement.^[4]

In this paper, we report the plain radiography and computed tomography (CT) findings of a very rare case of Type V thumb polydactyly in a 42-year-old man who presented with swan neck deformity of the radial thumb.

CASE REPORT

A healthy, 42-year-old man was admitted to the hospital with a complaint of functional difficulties in his daily life because of a duplicated thumb on the left hand. There was no family history of polydactyly. Physical examination revealed pre-axial polydactyly. The patient was unable to move the extra digit independently. The digit was mildly hypoplastic. There was flexion deformity of interphalangeal joint and hyperextension of metacarpophalangeal joint (swan neck deformity). Ulnar-side thumb had flexion deformity of interphalangeal and metacarpophalangeal joints [Figure 2].

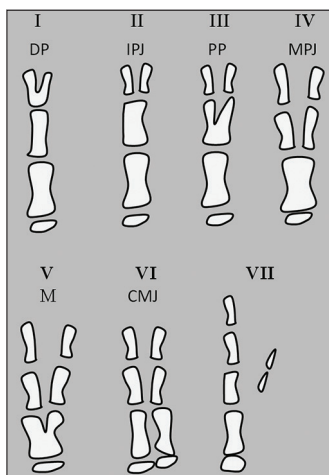


Figure 1: Types of thumb duplication and level of bifurcation according to Wassel's classification. DP = Distal phalanx, IPJ = Interphalangeal joint, PP = Proximal phalanx, MPJ = Metacarpophalangeal joint, M = Metacarpal, and CMJ = Carpometacarpal joint.

Plain radiographs showed duplicated phalanges with bifid first metacarpal [Figure 3]. The extra thumb had proximal and distal phalanges which indicated Type V polydactyly, according to Wassel's classification. The swan neck deformity observed showed hyperextension of metacarpophalangeal joint and flexion deformity of interphalangeal joint. This thumb articulated with the first metacarpal at the mid-level of the metacarpal. Ulnar-side thumb was articulated with the metacarpal head. This thumb had flexion deformity of interphalangeal and metacarpophalangeal joints; therefore, the phalanges of this thumb could not be evaluated sufficiently with plain radiographs. Thus, CT examination was performed to show the phalanges and joints of the thumbs in detail.

CT of the left hand was obtained to demonstrate the articulations of the duplicate thumb in detail. The joints of the radial-side thumb (extra thumb) were best visualized on the coronal reformatted CT images and the joints of the other thumb were best visualized on the axial CT images. Radial-side thumb articulated with the first metacarpal at the mid-level of the metacarpal. A sesamoid bone adjacent to the metacarpophalangeal joint of radial-side thumb was observed on the axial and coronal reformatted CT images [Figure 4]. The other thumb articulated with the metacarpal head. Ulnar-sided thumb had two phalanges. Two phalanges and metacarpal with the joints were best observed on the axial CT images. Three-dimensional (3D) reformatted CT images showed the general view of the articulations and abnormal bones [Figure 5]. The flexor pollicis longus and extensor pollicis longus tendons diverged distally. Ulnar- and radial-side flexor pollicis longus tendons inserted into the palmar aspects of the distal phalanges as seen on the coronal multiplanar reformatted and axial CT images [Figure 6]. Transverse interconnecting fibers were observed between the radial- and ulnar-side

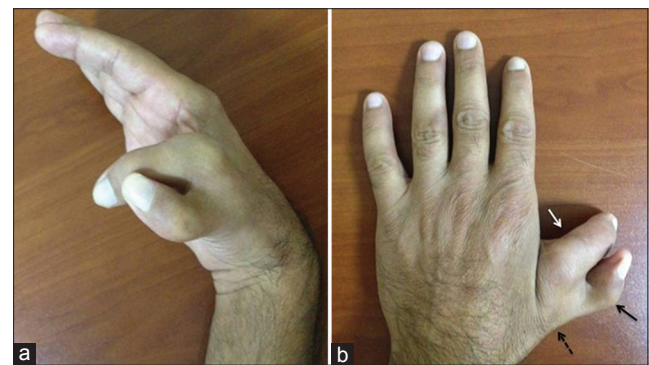

Figure 2: 42-year-old man with isolated left-hand duplicated thumb. Clinical photo of the left hand (a) side view shows pre-axial polydactyly, (b) front view shows the extra digit is mildly hypoplastic, has flexion deformity of interphalangeal joint (black arrow), and hyperextension of metacarpophalangeal joint (dotted arrow) (swan neck deformity). Ulnar-side thumb has flexion deformity of interphalangeal and metacarpophalangeal joints (white arrow).

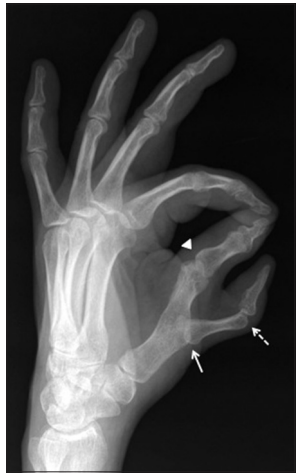

Figure 3: 42-year-old man with isolated left-hand duplicated thumb. Plain radiographic image shows duplicated phalanges with bifid first metacarpal. Swan neck deformity is observed as hyperextension of metacarpophalangeal joint (white arrow) and flexion deformity of interphalangeal joint (dotted arrow). Ulnar-side thumb is articulated with the metacarpal head and has flexion deformity of interphalangeal and metacarpophalangeal joints (arrowhead).

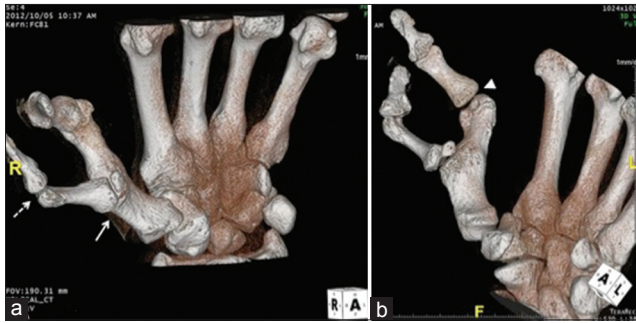

Figure 5: 42-year-old man with isolated left-hand duplicated thumb. (a) Three-dimensional reformatted CT images show the articulations of radial-side and ulnar-side thumbs. The radial-side thumb has hyperextension of metacarpophalangeal joint (white arrow) and flexion deformity of interphalangeal joint (dotted arrow). (b) Ulnar-side thumb has flexion deformity of interphalangeal and metacarpophalangeal joints (arrowhead).

flexor pollicis longus tendons [Figure 6]. Ulnar- and radial-side extensor pollicis longus tendons inserted into the dorsal aspects of the distal phalanges. Abductor pollicis brevis intrinsic muscle inserted into radial aspect of the proximal phalanx of radial-side thumb [Figure 6]. Opponens pollicis muscle connected to the radial aspect of the first metacarpal and the base of the proximal phalanx of the radial-side thumb. Adductor pollicis muscles connected to the base of the proximal phalanx of ulnar-side thumb.

With this deformity, the patient was unable to perform routine activities. Hence, surgical treatment was offered. The patient refused the surgical treatment.

DISCUSSION

Polydactyly is classified into pre-axial, central, and post-axial types. Pre-axial polydactyly, the most common type, refers to the duplication of the first digital ray.^[4] It can occur in

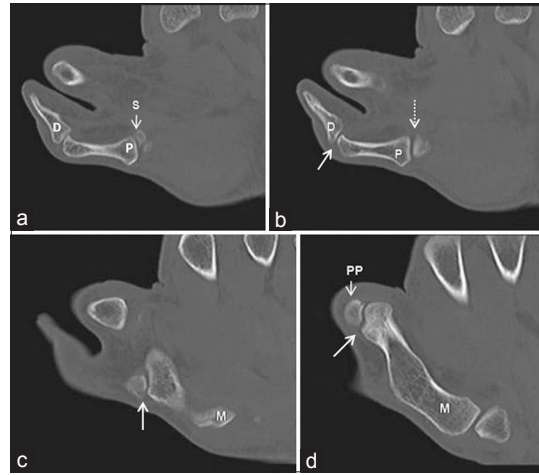


Figure 4: 42-year-old man with isolated left-hand duplicated thumb. (a and b) Coronal reformatted consecutive CT images show the proximal (p) and distal (d) phalanges of the radial thumb. A sesamoid bone (s) is also observed. (b) CT image shows swan neck deformity as hyperextension of metacarpophalangeal joint (dotted arrow) and flexion deformity of interphalangeal joint (arrow). (c) CT image shows the proximal phalanx articulates with the first metacarpal (arrow). (d) CT image shows the articulation between proximal phalanx and first metacarpal (arrow). M = First metacarpal, P = Proximal phalanx, D = Distal phalanx, PP = Proximal phalanx of the ulnar-sided thumb, S = Sesamoid bone.

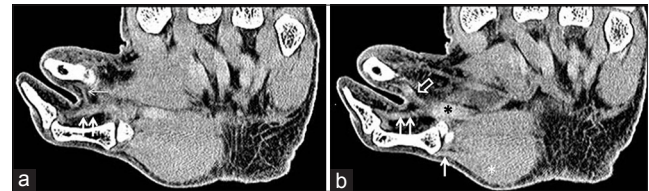


Figure 6: 42-year-old man with isolated left-hand duplicated thumb. (a) Coronal reformatted CT image shows transverse interconnecting fibers (thin arrow) between the radial-side (double thick arrows) and ulnar-side (open arrow) flexor tendons. (b) Coronal reformatted consecutive CT image shows the flexor pollicis longus tendon (black asterisk) diverged distally. Abductor pollicis brevis (white asterisk) muscle is seen inserted into radial aspect of the proximal phalanx (thick arrow) of the radial-side thumb.

isolation or as part of a syndrome. Isolated polydactyly is often autosomal dominant, while syndromic polydactyly is commonly autosomal recessive.^[5] Ezaki found isolated thumb polydactyly associated with several syndromes. Pre-axial polydactyly occurs sporadically with an incidence of 8 in 100,000 people in both African and Caucasian populations.^[3]

Pre-axial polydactyly has a number of genetic causes such as mutations on the human chromosome 7q36.^[2] It was work on mouse polydactyly mutations called Sasquatch (*Ssq*) and hemimelic extra toe (*Hx*) that identified the underlying mechanism for pre-axial polydactyly. The genetics of *Hx* placed the chromosomal location of the mutation to a region on mouse chromosome 5 containing a gene called *LMBR1*.^[6] Subsequently, the human pre-axial polydactyly locus was found to map to a corresponding region on chromosome 7q36 also containing the *LMBR1* gene. A human *t*(5,7)(q11, q36) [the designation *t*(5,7) is used to denote a

translocation between chromosome 5 and chromosome 7, q indicating the long arm, and the numbers after q refer to regions, bands, and sub-bands] identified in a pre-axial polydactyly patient located the breakpoint in intron 5 of the *LMBR1* gene as crucial to the phenotype.^[5] Having identified *LMBR1* (limb region 1 protein homolog is a protein that is encoded by the *LMBR1* gene in humans) as central to the mutant phenotype, this gene became the prime factor responsible for pre-axial polydactyly. Alternatively, the Saunders and Gasseling experiments showed an extra digit formed due to an ectopic zone of polarizing activity (ZPA) in the anterior limb bud in agreement with the prediction *LMRB1* is physically linked to *Shh* (sonic hedgehog) gene. Pre-axial polydactyly disrupts limb asymmetry by producing an ectopic ZPA at the opposite margin of the limb bud. Mutations in the long-range, limb-specific regulatory element of the *Shh* gene, are responsible for the defect according to Lettice et al.^[7]

Wassel identified seven types of thumb duplication in 70 hands. Bifurcation at the metacarpophalangeal joint (Type IV) is the most common type. Wassel reported only 10% of Type V present in 70 duplicated thumbs.^[4] Tada et al., presented the results of surgery of 237 patients with 261 hands showing duplication of the thumb. Of the 261 duplicated thumbs, only 35 (13.5%) were described as Type V in Tada's study. They noted that for Type V duplication, treatment of the soft-tissue anomalies had been very complicated but there was no misalignment of the ulnar component that required treatment. They emphasized that after amputation of the radial component at the bifurcation of the first metacarpal, all of the intrinsic and extrinsic muscles that had been inserted on the radial thumb were transferred to their normal insertions on the preserved ulnar component.^[8]

Kumar recently reported plain radiography findings in a case of bifid first metacarpal in a 13-year-old girl, who presented with swan neck deformity of the left thumb.^[9] To our knowledge, our case is the second case that has a swan neck deformity with bifid metacarpal. We also described the

CT findings of the case. CT of the left hand demonstrated the articulations of the two thumbs with the metacarpal in detail. The coronal reformatted CT images showed the phalanges and metacarpal of the ulnar-side thumb on the same CT image. The joints of the radial-side thumb were best visualized on the axial CT images.

CONCLUSION

CT scan with multiplanar reconstructions and 3D reformations provide images of the bone structures and joints of the thumbs in detail. Soft-tissue components of the thumb, such as flexor and extensor pollicis tendons, adductor pollicis brevis, abductor pollicis, and opponens pollicis muscles can be observed clearly on axial and coronal reformatted CT images. For this reason, CT scan is chosen as a guide for surgical treatment in these patients.

REFERENCES

1. Woolf CM, Myriantopoulos NC. Polydactyly in American negroes and whites. *Am J Hum Genet* 1973;25:397-404.
2. Zguricas J, Heus H, Morales-Peralta E, Breedveld G, Kuyt B, Mumcu EF, et al. Clinical and genetic studied on 12 preaxial polydactyly families and refinement of the localisation of the gene responsible to a 1.9 cM region on chromosome 7q36. *J Med Genet* 1999;36:32-40.
3. Graham TJ, Ress AM. Finger polydactyly. *Hand Clin* 1998;14:49-64.
4. Wassel HD. The results of surgery for polydactyly of the thumb. A review. *Clin Orthop Relat Res* 1969;64:175-93.
5. Elliott AM, Evans JA. Genotype-phenotype correlations in mapped split hand foot malformation (SHFM) patients. *Am J Med Genet A* 2006;140:1419-27.
6. Clark RM, Marker PC, Kingsley DM. A novel candidate gene for mouse and human preaxial polydactyly with altered expression in limbs of Hemimelic extra-toes mutant mice. *Genomics* 2000;67:19-27.
7. Lettice LA, Heaney SJ, Purdie LA, Li L, de Beer P, Oostra BA, et al. A long-range Shh enhancer regulates expression in the developing limb and fin and is associated with preaxial polydactyly. *Hum Mol Genet* 2003;12:1725-35.
8. Tada K, Yonenobu K, Tsuyuguchi Y, Kawai H, Egawa T. Duplication of the thumb. A retrospective review of two hundred and thirty-seven cases. *J Bone Joint Surg Am* 1983;65:584-98.
9. Kumar S. An unusual bifid first metacarpal. *Indian J Orthop* 2010;44:227-9.

Source of Support: Nil, **Conflict of Interest:** None declared.