

CASE REPORT

Report of Two Siblings with Overlapping Features of Ellis-van Creveld and Weyers Acrodistal Dysostosis

Devi C. Shetty, Harkanwal P. Singh, Prince Kumar¹, Chanchal Verma

Departments of Oral and Maxillofacial Pathology and Microbiology, ¹Prosthodontics and Oral Implantology, I.T.S. Center for Dental Studies and Research, Muradnagar, Ghaziabad, Uttar Pradesh, India

Address for correspondence:

Dr. Harkanwal Preet Singh,
 Department of Oral and Maxillofacial
 Pathology and Microbiology,
 I.T.S. Center for Dental Studies and
 Research, Muradnagar, Ghaziabad –
 201 206, Uttar Pradesh, India.
E-mail: hkps0320@gmail.com



Received : 23-02-2012
Accepted : 31-03-2012
Published : 28-04-2012

ABSTRACT

Skeletal dysplasias are a heterogenous group of disorders combining abnormalities in the skull and other skeletal bones. Weyers acrofacial dysostosis also known as Weyers acrodistal dysostosis was first described in 1952, by Weyers, as a postaxial polydactyly, which had features distinct from, yet some in common with the Ellis-van Creveld Syndrome (EvC). Both the syndromes have been mapped to the same chromosome, 4p16. The cases reported here highlight the overlapping features of both syndromes, which are dissimilar in mode of inheritance and phenotypic severity, emphasizing the need for genetic analysis, to categorize these conditions.

Key words: Ellis-van Creveld, polydactyly, syndrome, weyers acrodistal dysostosis

INTRODUCTION

A syndrome is a group of signs and symptoms that occur together and characterize a particular disease or abnormality. The abnormalities or defects can involve

multiple systems. It is characteristic of certain of these conditions to follow a strict Mendelian pattern of heredity. An adequate in-depth investigative record of the individual who is presenting with such condition is essential.

Skeletal dysplasias are a heterogenous group of disorders that result in a disproportionate short stature. Attempting to reach a unified nomenclature system, an International Nomenclature and Classification was proposed in 1969, which was subsequently updated in the years 1992 and 1997. In the 2001 revision, the term 'dysostoses' was incorporated, which referred to malformations of individual

Access this article online	
Quick Response Code:	Website: www.clinicalimaging-science.org
	DOI: 10.4103/2156-7514.95432

Copyright: © 2012 Shetty DC. This is an open-access article distributed under the terms of the Creative Commons Attribution License, which permits unrestricted use, distribution, and reproduction in any medium, provided the original author and source are credited.

This article may be cited as:
 Shetty DC, Singh HP, Kumar P, Verma C. Report of Two Siblings with Overlapping Features of Ellis-van Creveld and Weyers Acrodistal Dysostosis. J Clin Imaging Sci 2012;2:18.
 Available FREE in open access from: <http://www.clinicalimaging-science.org/text.asp?2012/2/1/18/95432>

bones, single or in combination, and did not refer to a generalized disorder of the skeleton.^[1]

The acrofacial dysostoses are a heterogeneous group of disorders that affect the skull and other skeletal bones. The Curry Hall syndrome (Weyer's acrofacial dysostosis) was first described in 1952, by Weyer, as postaxial polydactyly (POADS), now also known as the Miller's syndrome. He proposed the name acrofacial dysostoses and suggested an autosomal mode of inheritance. The syndrome is characterized by postaxial polydactyly, dysplastic nails, oligodontia, enamel hypoplasia, and conical teeth.^[2]

Weyer's acrofacial dysostosis is distinct from, and yet has some features in common with, the Elli-van Creveld syndrome (EvC, MIM 225500). EvC is an autosomal recessive skeletal dysplasia characterized by short limbs, short ribs, postaxial polydactyly, and dysplastic nails and teeth. Congenital cardiac defects, most commonly defects of primary atrial septation producing a common atrium, occur in 60% of the affected individuals. This entity has been mapped to chromosome 4p16, which is same as that affected in Weyer's Acrofacial Dysostoses.^[3,4] Majority of EvC patients have mutations either in *EVC* or *EVC2* and the phenotypes associated with mutations in these genes are clinically indistinguishable, whereas, in the Weyers syndrome only two mutations, S307P in *EVC* and c.3793delC in *EVC2*, have been identified to date. There are very few Weyers cases described with mutations and interestingly most of them have been found carrying heterozygous mutations in the last exon of *EVC2*.^[5] Weyer syndrome has a lower prevalence than EvC and is considered a less severe form.^[5,6]

We present two cases of a 15-year-old boy and his 14-year-old sister, presenting with features suggesting partial expression of Weyer's acrofacial dysostoses and an overlap with the features of the EvC syndrome. Through these case reports we would be highlighting the need for a methodology for classifying or naming the syndromes where a heterogeneous group of disorders are present. This would be pertinent and have a specific relevance to a situation where syndromes show an overlap of the features of differing designations, and would also address the problem of identifying the syndrome in cases of partial expression of the phenotypes.

CASE REPORTS

A 15-year-old-boy and his 14-year-old sister, the third and fourth among eight children of consanguineous and normally developed parents reported to the department with a major common complaint of discolored and worn

down teeth, desiring treatment and replacement of the missing teeth.

Case 1

The 15-year-old boy was apparently asymptomatic up till seven years of age when he had first noticed the beginning of discoloration and chipping of his teeth. Subsequently many teeth were found to be carious and he had undergone multiple extractions over the past 8 years.

On general examination, a short stature (138 cm), with short limbs and a moderate build were noted. Frontal bossing with receding hairline [Figure 1], hypotelorism with antimongoloid slant of the eyes was also seen [Figure 1]. Facial asymmetry with a depressed midface and protruding mandible were evident.

A thorough intra-oral examination revealed oligodontia, with widely spaced, discolored, malformed dentition, and over-retained deciduous teeth with pulpal exposure in all teeth [Figure 2]. Partial ankyloglossia was also seen [Figure 3].

A detailed radiographic analysis with complete skeletal

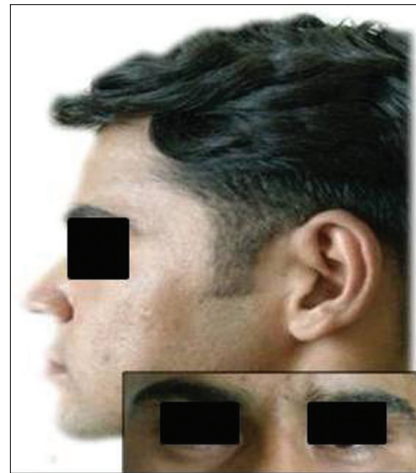

Figure 1: Extra-oral photograph shows protruding mandible and hypotelorism.

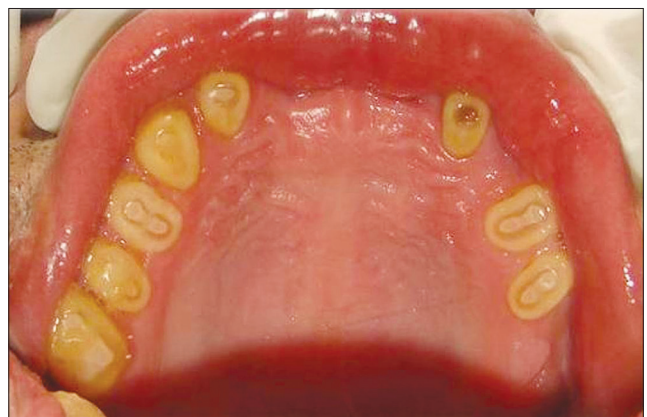


Figure 2: Intra-oral photograph shows malformed dentition with pulpal exposure of all teeth in the maxillary arch.

radiographs was performed. An Orthopantomogram (OPG) revealed multiple unerupted permanent teeth, multiple missing permanent tooth germs, short roots, and enlarged pulpal chambers [Figure 4].

Cephalometric analysis of the lateral cephalogram confirmed the presence of a hypoplastic maxilla, increased mandibular gonial, and increased mandibular body length. The abnormal sella and presence of wormian bones were the prominent findings in the skull.

The ground section revealed increased interprismatic distance and focal areas of calcifications. The remaining teeth specimens were decalcified in 10% Nitric acid, processed, sectioned, and stained with the routine Hematoxylin and Eosin stain. Examination of the stained sections revealed multiple calcifications within the pulp chamber.

Case 2

A 14-year-old-girl also complained of worn out and multiple missing teeth. The general physical examination revealed a short stature (128 cm), short limbs, short ribs, and dysplastic nails and teeth. An extra-oral examination showed dolicocephalic, hypoplastic maxilla, frontal bossing, receding hair line, antimongoloid slant of eyes, and poor vision [Figure 5]. Her prenatal and natal histories were uneventful and she had attained all the developmental milestones at the appropriate time.

An intra-oral examination revealed partial ankyloglossia, widely spaced attrited teeth, discolored malformed dentition with hypoplastic enamel, oligodontia, large pulp chambers, and a collapsed bite [Figures 6a and 6b].

The OPG showed multiple impacted teeth, multiple missing permanent tooth germs, retained teeth, short roots, and enlarged pulp chambers [Figure 7]. A Hand-Wrist Radiograph showed incomplete capping of the epiphysis of the mid phalanx and incomplete fusion of the epiphysis and diaphysis of the radius [Figure 8].

These findings indicated a skeletal abnormality associated with the orofacial defect. After a thorough search and symptomatic analysis the diagnosis was narrowed down to two syndromes:

- Weyers Acrofacial Dysostoses
- EvC syndrome

These syndromes show a plethora of features among which a few matched with the cases presented here.

DISCUSSION

The patients described here, had features common to

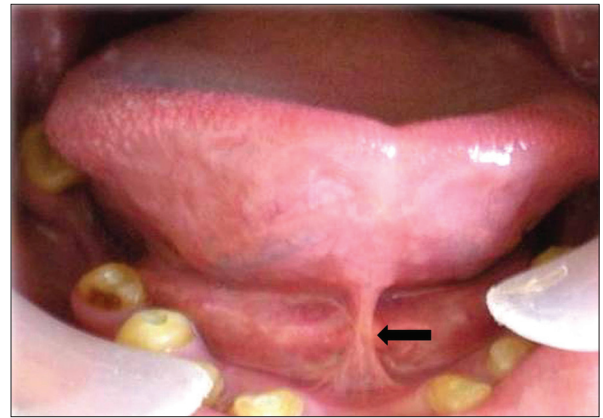


Figure 3: Intra-oral photograph shows partial ankyloglossia (arrow).

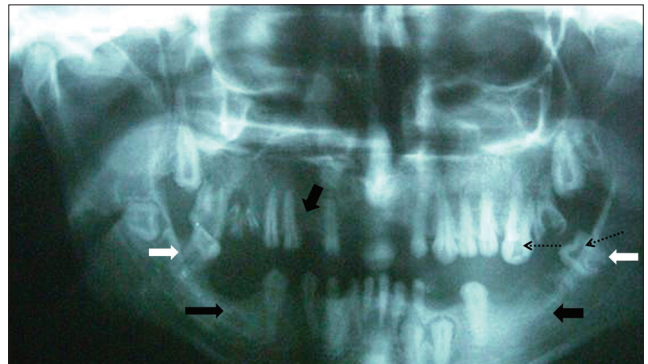


Figure 4: Orthopantomograph shows multiple unerupted teeth and missing permanent tooth germs (black arrow), short roots (white arrow), and enlarged pulpal chambers (dashed arrow).

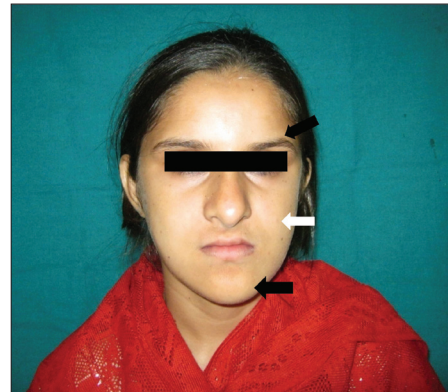

Figure 5: Extra-oral photograph shows dolicocephalic, hypoplastic maxilla (white arrow), with anti-mongoloid features (black arrow).

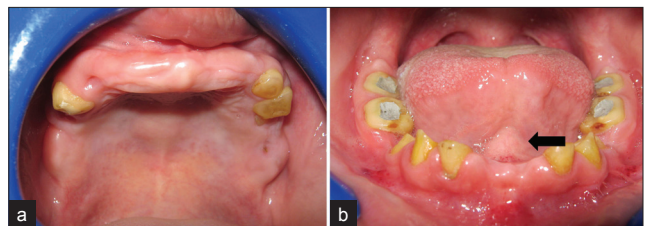


Figure 6: (a) Intra oral photograph of the maxillary arch shows multiple missing teeth (b) Intra oral photograph shows ankyloglossia (arrow), widely spaced, discolored, and malformed teeth.

EvC and Weyer's Acrofacial dysostosis as elaborated in Table 1.

Table 1: Comparative evaluation of features in the present cases with EvC syndrome and Weyers acrofacial dysostosis

Orofacial	EvC syndrome	Weyers acrofacial dysostoses	Case 1	Case 2
Hypodontia	+	-	+	+
Conical teeth	+	+	+	+
Enlarged pulp chambers	+	+/-	+	+
Hypoplastic enamel	+	-	+	+
Natal teeth	+	-	-	-
Multiple frenulae	+	+/-	-	-
Ankyloglossia	-	+	+	+
Protruded mandible	-	+	+	+
Hair changes	+	-	+	+
Hypotelorism	-	+	+	+
Skeletal				
Disproportionate dwarfism	+	Mild	+	+
Postaxial polydactyly	+	+	-	-
Hypoplastic nails	+	+	-	-
Brachydactyly	+	+	-	-
Hypoplastic thorax	+	-	-	-
Digital deformities	Fusion of capitate and hamate	Fusion of metatarsals and metacarpals	-	+
Systemic				
Cardiac abnormalities	+	-	-	-
Retinal deformities	-	-	Poor vision	Poor vision
Renal	-	-	-	-
Pancreatic	-	-	-	-
Lethal in newborns	+/-	-	-	-

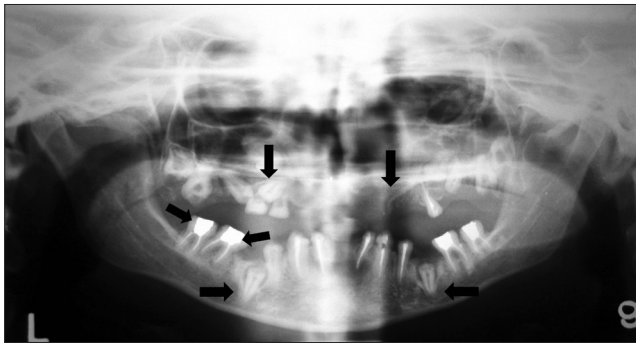


Figure 7: Orthopantomograph shows multiple impacted teeth, multiple missing permanent tooth germs, retained teeth (arrow), short roots (arrow), and enlarged pulp chambers (arrow).

Ellis-van Creveld is an autosomal recessive skeletal dysplasia characterized by short limbs, postaxial polydactyly, short ribs, and dysplastic nails and teeth. Congenital cardiac defects occur in 60% of the affected individuals and the disease is mapped to chromosome 4p 16.^[7]

The syndrome can be diagnosed during the prenatal period, starting from the eighteenth week of gestation, by ultrasonography, or later by clinical examination after birth.^[7] Chondrodysplasia is the most common clinical feature affecting the tubular bones, resulting in a serious ossification defect. In consequence, the distal extremities of the limbs are short and the patient is small in stature.^[8] Baujat et al.,^[7] have demonstrated that the growth hormone therapy is not effective in these patients. However, there is one published case that has shown a favorable result in growth following hormonal treatment.^[8]

Orofacial digital syndromes present with variable and

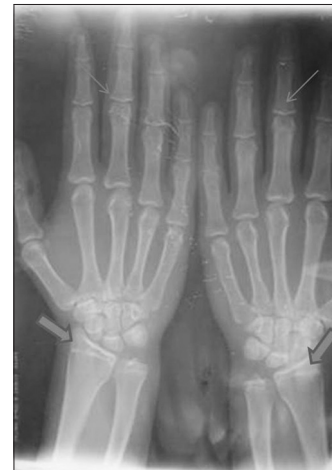

Figure 8: Hand-wrist radiograph shows incomplete capping of the epiphysis of the mid phalanx (small arrow) and incomplete fusion of the epiphysis and diaphysis of the radius (large arrow).

overlapping phenotypic features, rendering this syndrome difficult to classify and differentiate from other syndromes of a similar clinical spectrum like EvC and Weyers syndrome. It results from a dominant sex-linked inheritance; they are limited to women and clinically characterized by multiple gingivolabial frenula, hypoplasia of the nasal cartilages, moderate mental retardation, fissured tongue, and in one-third of the cases ankyloglossia.^[4,8]

In the year 1952, Weyers described a syndrome of postaxial polydactyly, anomalies of the lower jaw, dentition, and oral vestibule, and proposed the name 'acrofacial dysostosis'. He simultaneously suggested an autosomal dominant inheritance of the disorder. The occurrence of nail anomalies is non-obligatory and incomplete penetrance has been suggested. Weyers acrofacial dysostoses (MIM

193550) is considered a similar, but milder phenotype of EvC and has been mapped in a single pedigree to an area that is also a critical genomic region for the EvC syndrome mutation. According to McKusick both these syndromes are allelic conditions.^[9]

Ellis-van Creveld belongs to the short rib-polydactyly group (SRP). These SRPs are all autosomal recessive disorders that have been classified into various types (Saldino-Noonan syndrome, Type I; Majewski syndrome, Type II; Verma-Naumoff syndrome, Type III; Beemer-Langer syndrome, Type IV; and Jeune Dystrophy). They are characterized by hypoplastic thorax due to short ribs, short limbs, frequent polydactyly, and visceral abnormalities, and are detected prenatally. Radiographically and histologically, SRP III (Verma-Naumoff syndrome, OMIM 263510) resembles some forms of EvC.^[10,7]

The Ellis-van Creveld syndrome requires multidisciplinary therapeutic planning. The odontologist plays a fundamental role in the control of oral and dental manifestations. A combination of orthodontics, surgery, and prosthetics is essential to correct the craniofacial morphology and dental defects, aiming to achieve satisfactory functional and esthetic result. Dental treatment should be made under low antibiotic prophylaxis due to the high incidence of heart pathology in these patients.^[7]

We emphasize the fact that cognitive development in the syndromes described here is normal. Prognosis of the final body height in individual patients is difficult to predict, as a few publications have been reported in literature on adult patients. Although postaxial polydactyly is a constant clinical finding seen in both EvC and Weyers syndrome, in the present cases this feature is not seen. Therefore, the authors suggest the need for further gene analysis that consider the possibility of mutation at different gene loci.

In the current study, we found many features overlapped with those associated with Weyers Acrofacial Dysostoses, such as, short limbs, dysplastic teeth, and lower jaw abnormalities. This definitely indicates possible incomplete penetrance and partial expression of the phenotypic

characteristics. On account of the consanguinity of the pedigree and the parents being healthy, a recessive pattern of inheritance is highly probable in the present cases.

CONCLUSION

Proper systematic methodology is needed in classifying or categorizing the syndromes discussed. Further case series are required to exactly demarcate these syndromic conditions from others, as the clinical spectrum of EvC and Weyers syndrome is not well delineated at present. Molecular testing in the affected individuals is required to ascertain whether they have mutations in EVC or EVC2, and whether the patients are homozygous or heterozygous for these changes.

REFERENCES

1. Shafer, Hine, Levy. Diseases of bones and joints. In: Rajendran R, Sivapathasundaram B, editors. Shafer's Textbook of Oral Pathology. 5th ed. India: Elsevier; 2006.
2. Roubicek M, Spranger J. Weyers acrofacial dysostosis in a family. *Clin Genet* 1984;26:587-90.
3. Ruiz-Perez VL, Ide SE, Strom TM, Lorenz B, Wilson D, Woods K, et al. Mutations in a new gene in Ellis-van Creveld syndrome and Weyers acrofacial dysostosis. *Nat Genet*. March 2000;2:283-6.
4. Ghosh S, Setty S, Sivakumar A, Pai KM. Report of a new syndrome: Focus on differential diagnosis and review of Ellis-van Creveld, Curry-Hall, Acrofacial dysostosis, and orofacial digital syndromes. *Oral Surg Oral Med Oral Pathol Oral Radiol Endod* 2007;103:670-6.
5. Valencia M, Lapunzina P, Lim D, Zannolli R, Bartholdi D, Wollnik B, et al. Widening the Mutation Spectrum of EVC and EVC2: Ectopic Expression of Weyer Variants in NIH 3T3 Fibroblasts Disrupts Hedgehog Signaling. *Hum Mutat* 2009;30:1667-75.
6. Ali BR, Akawi NA, Chedid F, Bakir M, Rehman MU, Rahmani A, et al. Molecular and clinical analysis of Ellis-van Creveld syndrome in the United Arab Emirates. *BMC Med Genet* 2010;11:33.
7. Baujat G, Le Merrer M. Ellis-van Creveld syndrome. *Orphanet J Rare Dis* 2007;2:27.
8. Alves-Pereira D, Berini-Aytés L, Gay-Escoda C. Ellis-Van Creveld Syndrome. Case report and literature review. *Med Oral Patol Oral Cir Bucal* 2009;14:E340-3.
9. McKusick VA. Ellis-van Creveld syndrome and the Amish. *Nat Genet* 2000;24:203-4.
10. Yang S, Langer L, Cacciarelli A, Dahms B, Unger E, Roskamp J. Three conditions in neonatal asphyxiating thoracic dysplasia (Jeune) and short rib-polydactyly syndrome spectrum: A clinicopathologic study. *Am J Med Genet* 1987;3(Suppl):191-207.

Source of Support: Nil, **Conflict of Interest:** None declared.