



Case Report

Ovotesticular Disorder of Sex Development: An Unusual Presentation

Meltem Özdemir, Rasime Pelin Kavak, Ihsan Yalcinkaya, Kursat Guresci

Department of Radiology, University of Health Sciences, Dışkapı Yıldırım Beyazıt Training and Research Hospital, Ankara, Turkey.



*Corresponding author:

Meltem Özdemir,
Department of Radiology,
University of Health Sciences,
Dışkapı Yıldırım Beyazıt
Training and Research Hospital,
Ziraat mah. Şehit Ömer
Halisdemir Cad. Altındağ,
Ankara 06010, Turkey.

meltemkaan99@gmail.com

Received : 20 May 19

Accepted : 03 June 19

Published :

DOI

Quick Response Code:

ABSTRACT

Disorder of sex development is an inclusive term that refers to any problem where the genital organ is atypical in relation to chromosomes or gonads. Ovotesticular disorder of sex development, which is formerly known as “true hermaphroditism,” is the most rare form among all disorders of sex development in humans. It is characterized by the simultaneous presence of both ovarian and testicular tissues in the same individual and characteristically presents with ambiguous genitalia in neonates or infants. Herein, we present an unusual case of a 19-year-old individual with phenotypically nearly normal male genitalia who presented with the complaint of bilateral breast enlargement.

Keywords: Intersexuality, Ovotestis, Sex differentiation disorders, True hermaphroditism

INTRODUCTION

Disorders of sex development (DSDs) are a group of rare and complex disorders characterized by abnormalities of chromosomal, gonadal, or phenotypic properties that determine sex development. The prevalence of DSD is reported to be 1.8 per 10,000 live births.^[1] Ovotesticular DSD, which is formerly known as “true hermaphroditism,” is the rarest disorder of sex development in humans. Its prevalence has been reported to be less than 1/20,000, and about 500 affected individuals have been reported to date.

Ovotesticular DSD is characterized by the simultaneous presence of both ovarian and testicular tissues in the same individual and characteristically presents with ambiguous genitalia in neonates or infants. The gender assignment of these cases represents a great therapeutic challenge and mostly addressed as an endocrine emergency situation. The responsibility for overcoming this multiparametric problem is often undertaken by a gender assignment committee consisting of pediatric surgeons, endocrinologists, neonatologists, clinical geneticists, and psychiatrists.^[2,3]

It has been reported that only about 10% of all patients with ovotesticular DSD present with a phenotypically normal or nearly normal male penis and diagnosed later during adolescence.^[4] Herein, we present an unusual case of ovotesticular DSD who presented with progressive bilateral gynecomastia at the age of 19 years.

CASE REPORT

A 19-year-old male presented with progressive bilateral breast enlargement for the past 4 years. He had no concomitant urologic or systemic complaints. History of the growth and development

This is an open-access article distributed under the terms of the Creative Commons Attribution-Non Commercial-Share Alike 4.0 License, which allows others to remix, tweak, and build upon the work non-commercially, as long as the author is credited and the new creations are licensed under the identical terms.

©2019 Published by Scientific Scholar on behalf of Journal of Clinical Imaging Science

was normal with pubic hair being recorded at the age of 13 years. The patient described having erections but no experience of sexual activity. He is the second son of healthy parents and his elder brother is completely healthy. There is no history of sexual ambiguity in the extended family. Physical examination revealed an apparently healthy male weighing 58 kg and 163 cm tall. The amount of facial and axillary hair was normal. Bilateral gynecomastia without accompanying lymphadenopathy or nipple discharge was noted. Examination of genitalia revealed a small but well-developed male phallus with a normally positioned single orifice at the glans penis, consistent with Prader Stage V. There was no external vaginal opening. The patient did not state penile bleeding or any kind of penile discharge. No palpable gonads were present in both labioscrotal areas. However, in the left inguinal region, a mass that was likely to be a gonad was palpated.

Hormone testing revealed normal levels of total testosterone (322 ng/dl) and estradiol (28 pg/ml) for a male. Blood dehydroepiandrosterone and prolactin levels as well as thyroid function studies were normal. However, levels of luteinizing hormone (12.4 IU/L) and follicle-stimulating hormone (19.6 mIU/L) were elevated, consistent with primary testicular failure. The cytogenetic analysis of the karyotype was performed using peripheral blood, and the analysis showed the genotype 46, XX. No translocation of sex-determining region of the Y chromosome (SRY) gene was detected on the fluorescence in situ hybridization (FISH) study.

Transscrotal ultrasonography showed no gonads in the hemiscrota. There was a well-circumscribed, ovoid, heterogeneously hypoechoic lesion of 31 × 21 × 13 mm size in the left inguinal region. Multiple focal cystic areas were recorded throughout the lesion parenchyma. Abdominopelvic ultrasonography (US) depicted a small uterus, a vagina, a small prostate, and accompanying seminal vesicles. Subsequently, an abdominal magnetic resonance imaging (MRI) study was performed on a 1.5T unit. Sagittal T2-weighted imaging demonstrated a hypoplastic uterus, a normal-looking vagina, and a hypoplastic prostate. There was a well-circumscribed lesion in the left inguinal region showing a heterogeneous high signal, compatible with the left gonad. The penis was smaller than normal [Figure 1]. Sagittal T2-weighted images as well as the coronal short tau inversion recovery (STIR) and axial fat-suppressed T2-weighted images nicely delineated the left gonad containing a large number of high signal foci, consistent with cystic areas. Vas deferens was visible adjacent to the left gonad [Figure 2]. Coronal STIR and axial fat-suppressed T2-weighted sections through the prostate and seminal vesicles showed a small prostate and multiple disorganized tubular structures at both seminal vesicle locations [Figure 3]. The right gonad could not be detected in any imaging sequence.

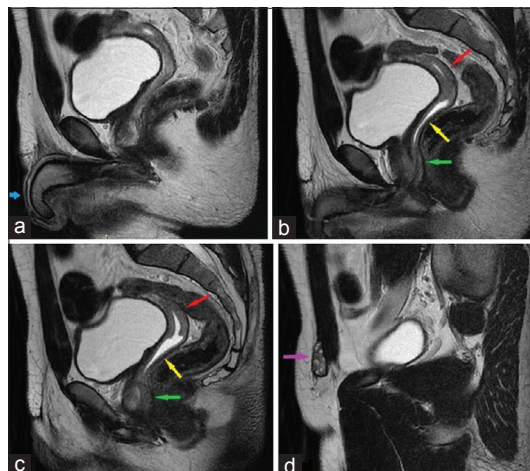


Figure 1: A 19-year-old individual with ovotesticular disorder of sex development who presented with progressive bilateral breast enlargement. (a) Midsagittal T2-weighted MRI section shows a small male phallus (blue arrow). (b) Parasagittal T2-weighted MRI section through the prostatic urethra demonstrates a hypoplastic prostate (green arrow), a normal-looking vagina (yellow arrow), and a hypoplastic uterus (red arrow). (c) Parasagittal T2-weighted MRI section depicts a hypoplastic prostate (green arrow), a normal-looking vagina (yellow arrow), and a hypoplastic uterus (red arrow). (d) Parasagittal T2-weighted MRI section through the left inguinal region shows the undescended left gonad (purple arrow).

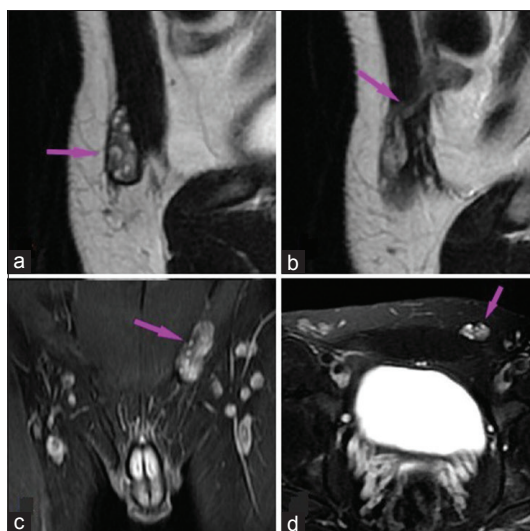


Figure 2: A 19-year-old individual with ovotesticular disorder of sex development who presented with progressive bilateral breast enlargement. (a) Parasagittal T2-weighted MRI section through the left inguinal region shows the left gonad containing a large number of high signal foci, consistent with cystic areas (arrow). (b) Parasagittal T2-weighted MRI section through the left inguinal region demonstrates the vas deferens adjacent to the left gonad (arrow). (c) Coronal short tau inversion recovery MR image shows the left gonad located in the left inguinal region (arrow). (d) Axial fat-suppressed T2-weighted MR image depicts the undescended left gonad (arrow).

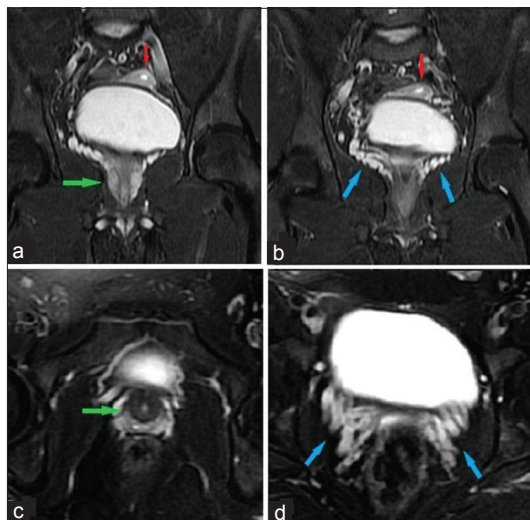


Figure 3: A 19-year-old individual with ovotesticular disorder of sex development who presented with progressive bilateral breast enlargement. (a) Coronal short tau inversion recovery MR image shows the hypoplastic prostate (green arrow) and the hypoplastic uterus (red arrow). (b) Coronal short tau inversion recovery MR image demonstrates multiple disorganized tubular structures at both seminal vesicle locations (blue arrows). Note the hypoplastic uterus adjacent to the bladder (red arrow). (c) Axial fat-suppressed T2-weighted MR image depicts the hypoplastic prostate (green arrow). (d) Axial fat-suppressed T2-weighted MR image shows multiple disorganized tubular structures at both seminal vesicle locations (blue arrows).

Deep wedge biopsy of the left gonad was performed. Histological evaluation revealed an ovotestis with a distinct demarcation between ovarian and testicular tissues. The ovarian portion of the ovotestis showed normal ovarian tissue with primordial follicles and ovarian stroma. Seminiferous tubules and spermatogonia were found in the testicular portion. The number of seminiferous tubules was decreased, whereas interstitial tissue was increased. Exploratory laparoscopy revealed a streak right gonad in the abdomen. A gonadectomy was performed, and the gonadal histology revealed the presence of a dysgenetic streak gonad with fibrous tissue resembling ovarian stroma. Based on the specific histological findings as well as highly supportive imaging findings, the patient was diagnosed as having ovotesticular DSD.

After the diagnosis, partial left gonadectomy and uterocolpectomy were performed. Areas of focal hemorrhage of various ages along with follicles and ovarian stroma were recorded in the assessment of the resected ovarian portion of the gonad. Further, bilateral reduction mammoplasties were performed within a few months. In the 2nd year of patient follow-up, persistent testosterone deficiency developed, and the condition was controlled by androgen supplementation.

DISCUSSION

DSD is an inclusive term that refers to any problem where the genital organ is atypical in relation to chromosomes or gonads. It typically manifests with the appearance of external genitalia incompatible with normal development for both genders in a neonate or infant. Congenital adrenal hyperplasia and mixed gonadal dysgenesis, which constitute more than half of all cases of neonatal genital ambiguity, are the most common causes of DSD.^[5]

Ovotesticular DSD is the rarest form of DSDs. The distinctive feature of the ovotesticular DSD is that the infant is born with the gonads of both sexes. The gonads may present any combination of ovary, testes, or combined ovary and testes (ovotestes). An ovotestis is present in about two-thirds of the affected individuals. The gonad may also appear as a streak gonad which is characterized by a non-functional dysgenetic tissue with increased fibrous component.^[6] Our patient presented a gonadal combination of an ovotestis and a streak gonad. Being reported to occur in only 1.2% of all cases of ovotesticular DSD, the combination of ovotestis-streak gonad is extremely rare.^[3]

The exact cause of the disease remains unknown in the majority of the cases of ovotesticular DSD. Most commonly detected chromosomal makeup among patients with ovotesticular DSD is a 46, XX karyotype.^[6] In approximately 10% of patients with a 46, XX karyotype, the presence of the testicular tissue is the result of the SRY gene being translocated to the X chromosome or another chromosome. Our patient had a 46, XX karyotype; however, no SRY gene translocation was detected on the FISH study. Genetic variations of other genes, such as duplication of SOX9, mutations in RSPO1, or NR5A1 genes, can also be present in cases with a 46, XX karyotype.^[7]

Like the other forms of DSD, ovotesticular DSD typically manifests in the neonatal period or infancy with ambiguous genitalia. In cases with a penis, the urethral orifice can be located underside. If the testes are present, they are usually undescended. A hypoplastic uterus along with an abnormal vagina is usually evident in the US. Radiologic examinations play a critical role in the assessment of internal genitalia of DSD cases. Being easily accessible and not involving radiation or contrast material, the US is the modality of choice in evaluating the patients with ambiguous genitalia. For further clarification of the internal anatomy and localization of the non-palpable gonads, other imaging methods such as genitography, voiding cystourethrography, and MRI can be employed. In selected cases, endoscopy and/or diagnostic laparoscopy may be needed in addition to radiologic imaging.^[8] MRI clearly delineated the internal genitalia of our patient. However, the right gonad could not be detected by any imaging studies, and an exploratory laparoscopy was indicated. The depiction of a streak gonad, which is often in

the form of a small and bizarre fibrous tissue, is quite difficult using any imaging method.

The present case is an extremely rare one in that the external genitalia is nearly normal, and the patient (and his parents) has not been in doubt about any sexual abnormality until a progressive breast enlargement occurred. However, the fact that both hemiscrota being empty and the penis being smaller than normal are the findings that could be detected at younger ages. We think that this delay in applying for medical care might be an unconscious resistance to a possible diagnosis of a sexual abnormality. In our patient, reactive behaviors such as not believing in the diagnosis and not cooperating in treatment processes were observed at the first. After accepting the diagnosis, he developed symptoms of severe depression. Fortunately, after regular psychotherapy sessions and medical psychiatric support, the patient's overall psychology improved significantly. Cultural and social factors as well as the intense psychological confusion which the patient experiences have a great impact on gender assignment and consecutive management. In cases of ovotesticular DSD who are diagnosed in infancy, gender assignment is based on the appearance of the external genitalia, the formation of the glands, and the potential for fertility.^[9] However, in an adult patient, gender assignment is based solely on the patient's perception of sexual belonging. The management of a patient with ovotesticular DSD must be carried out by a multidisciplinary team in which an experienced psychiatrist should absolutely take part.

CONCLUSION

Ovotesticular disorder of sex development is the most rare form among all disorders of sex development and characterized by the simultaneous presence of both ovarian and testicular tissues in the same individual. While it characteristically presents with ambiguous genitalia in neonates or infants, it may also present in adulthood. The management of a patient with ovotesticular DSD must be carried out by a multidisciplinary team.

Declaration of patient consent

The authors certify that they have obtained all appropriate patient consent forms. In the form the patient(s) has/have

given his/her/their consent for his/her/their images and other clinical information to be reported in the journal. The patients understand that their names and initials will not be published and due efforts will be made to conceal their identity, but anonymity cannot be guaranteed.

Financial support and sponsorship

Nil.

Conflicts of interest

There are no conflicts of interest.

REFERENCES

1. Makiyan Z. Systematization of ambiguous genitalia. *Organogenesis* 2016;12:169-82.
2. van Niekerk WA, Retief AE. The gonads of human true hermaphrodites. *Hum Genet* 1981;58:117-22.
3. Matsui F, Shimada K, Matsumoto F, Itesako T, Nara K, Ida S, *et al.* Long-term outcome of ovotesticular disorder of sex development: A single center experience. *Int J Urol* 2011;18:231-6.
4. Kropp BP, Keating MA, Moshang T, Duckett JW. True hermaphroditism and normal male genitalia: An unusual presentation. *Urology* 1995;46:736-9.
5. Kim KS, Kim J. Disorders of sex development. *Korean J Urol* 2012;53:1-8.
6. Ovotesticular Disorder of Sex Development. Available from: <https://rare-diseases.org/rare-diseases/ovotesticular-disorder-of-sex-development>. [Last accessed at 2019 Apr 14].
7. Kyriakou A, Lucas-Herald AK, McGowan R, Tobias ES, Ahmed SF. Disorders of sex development: Advances in genetic diagnosis and challenges in management. *Adv Genomics and Genet* 2015;5:165-77.
8. Moshiri M, Chapman T, Fechner PY, Dubinsky TJ, Shnorhavorian M, Osman S, *et al.* Evaluation and management of disorders of sex development: Multidisciplinary approach to a complex diagnosis. *Radiographics* 2012;32:1599-618.
9. Kuhnle U, Krahl W. The impact of culture on sex assignment and gender development in intersex patients. *Perspect Biol Med* 2002;45:85-103.

How to cite this article: Özdemir M, Kavak RP, Yalcinkaya I, Guresci K. Ovotesticular disorder of sex development: An unusual presentation. *J Clin Imaging Sci* 2019;9:xx.