




Original Research

## Role of Computed Tomography-guided Biopsies in the Era of Electromagnetic Navigational Bronchoscopy: A Retrospective Study of Factors Predicting Diagnostic Yield in Electromagnetic Navigational Bronchoscopy and Computed Tomography Biopsies

Naomi K. Atkins<sup>1</sup>, Jasraj Marjara<sup>1</sup>, Jussuf T. Kaif<sup>2</sup>, Jeffrey R. Kunin<sup>1</sup>, Sachin S. Saboo<sup>3</sup>, Ryan M. Davis<sup>1</sup>, Ambarish P. Bhat<sup>1</sup>

Departments of <sup>1</sup>Radiology and <sup>2</sup>Cardiothoracic Surgery, University of Missouri, Columbia, Missouri, <sup>3</sup>Department of Radiology, University of Texas Health Science Center, San Antonio, Texas, United States.



**\*Corresponding author:**

Ambarish P. Bhat,  
Department of Radiology,  
Section of Vascular and  
Interventional Radiology,  
University of Missouri, Columbia  
65203, Missouri, United States.

[bhatambarish@gmail.com](mailto:bhatambarish@gmail.com)

Received : 12 April 2020

Accepted : 20 May 2020

Published : 06 June 2020

**DOI**

10.25259/JCIS\_53\_2020

**Quick Response Code:**



### ABSTRACT

**Objectives:** Over 25% of the high-risk population screened for lung cancer have an abnormal computed tomography (CT) scan. Conventionally, these lesions have been biopsied with CT guidance with a high diagnostic yield. Electromagnetic navigational bronchoscopy (ENB) with transbronchial biopsy has emerged as a technology that improves the diagnostic sensitivity of conventional bronchoscopic biopsy. It has been used to biopsy lung lesions, due to the low risk of pneumothorax. It is, however, a new technology that is expensive and its role in the diagnosis of the solitary pulmonary nodule (SPN) is yet to be determined. The purpose of this study was to evaluate the diagnostic yield of CT-guided biopsy (CTB) following non-diagnostic ENB biopsy and identify characteristics of the lesion that predicts a low diagnostic yield with ENB, to ensure appropriate use of ENB in the evaluation of SPN.

**Materials and Methods:** One hundred and thirty-five lung lesions were biopsied with ENB from January 2017 to August 2019. Biopsies were considered diagnostic if pathology confirmed malignancy or inflammation in the appropriate clinical and imaging setting. We evaluated lesions for several characteristics including size, lobe, and central/peripheral distribution. The diagnostic yield of CTB in patients who failed ENB biopsies was also evaluated. Logistic regression was used to identify factors likely to predict a non-diagnostic ENB biopsy.

**Result:** Overall, ENB biopsies were performed in 135 patients with solitary lung lesions. ENB biopsies were diagnostic in 52% (70/135) of the patients. In 23 patients with solitary lung lesions, CTBs were performed following a non-diagnostic ENB biopsy. The CTBs were diagnostic in 87% of the patients (20/23). ENB biopsies of lesions <21.5 mm were non-diagnostic in 71% of cases (42/59); 14 of these patients with non-diagnostic ENB biopsies had CTBs, and 86% of them were diagnostic (12/14). ENB biopsies of lesions in the lower lobes were non-diagnostic in 59% of cases (35/59); 12 of these patients with non-diagnostic ENB biopsies had CTBs, and 83% were diagnostic (10/12). ENB biopsies of lesions in the outer 2/3 were non-diagnostic in 57% of cases (50/87); 21 of these patients with non-diagnostic ENB biopsies had CTBs, and 86% were diagnostic (18/21).

**Conclusion:** CTBs have a high diagnostic yield even following non-diagnostic ENB biopsies. Lesions <21.5 mm, in the outer 2/3 of the lung, and in the lower lung have the lowest likelihood of a diagnostic yield with ENB biopsies. Although CTBs have a slightly higher pneumothorax rate, these lesions would be more successfully diagnosed with CTB as opposed to ENB biopsy, in the process expediting the diagnosis and saving valuable medical resources.

**Keywords:** Electromagnetic navigational bronchoscopy, Computed tomography, Solitary pulmonary nodule, Pneumothorax, Non-small cell lung cancer

This is an open-access article distributed under the terms of the Creative Commons Attribution-Non Commercial-Share Alike 4.0 License, which allows others to remix, tweak, and build upon the work non-commercially, as long as the author is credited and the new creations are licensed under the identical terms.

©2020 Published by Scientific Scholar on behalf of Journal of Clinical Imaging Science

## INTRODUCTION

Over 25% of the high-risk population screened for lung cancer have an abnormal computed tomography (CT) scan.<sup>[1-5]</sup> Non-small cell lung cancer (NSCLC) is the most common type of lung cancer, and often presents as a solitary pulmonary nodule (SPN). The National Lung Cancer Screening Trial has shown a survival benefit associated with early detection and resection of NSCLC, which makes prompt diagnosis and treatment of the SPN critically important.<sup>[3,6-8]</sup> The probability of malignancy within a SPN may be estimated using existing models.<sup>[9-14]</sup> Guidelines from the American College of Chest Physicians<sup>[1,15,16]</sup> recommend direct surgical approach or follow-up with serial CT scans, depending on the high or low malignant probability of the SPN, respectively.<sup>[9,17]</sup> However, in cases of a SPN with intermediate probability of malignancy or for patients with a high surgical risk, the recommendation is to biopsy the lesion, most often CT-guided.<sup>[17]</sup> The sensitivity of CT-guided biopsy (CTB) for the diagnosis of NSCLC is very high ranging from 81% to 97%.<sup>[1,18-20]</sup> CTBs, however, are associated with a 15% pneumothorax risk and about 40% of these require a chest tube.<sup>[20-23]</sup>

Bronchoscopy-guided biopsies theoretically have less risk of pneumothorax as they do not traverse pleural layers; however, the yield of conventional bronchoscopic biopsy for peripheral lung lesions is low.<sup>[24]</sup> Electromagnetic navigational bronchoscopy (ENB) with transbronchial biopsy has emerged as a technology that improves the sensitivity of conventional bronchoscopy.<sup>[24-27]</sup> It is, however, a new technology that is evolving and its role in the diagnosis of the SPN is yet to be determined.

The purpose of this retrospective single-institution analysis was to evaluate the diagnostic yield of CTB following non-diagnostic ENB biopsy and identify characteristics of lesions that predict a low yield with ENB, hence ensure judicious use of ENB in the evaluation of SPN.

## MATERIALS AND METHODS

The study was conducted in a large, academic, tertiary care hospital. We used picture archiving and communication system and electronic medical records to identify 135 lung lesions biopsied with ENB from January 2017 to August 2019. The biopsies were performed by fellowship trained interventional pulmonologists (IP) and interventional radiologists (IR) with 2–5 years post fellowship experience. Biopsies were considered diagnostic if pathology showed malignancy or inflammation in the appropriate clinical and image setting, and non-diagnostic if pathology showed benign respiratory epithelium, indicating the target lesion was not biopsied. Using the pre-procedural CT, the biopsied lesions were assessed for size, vertical (upper or lower lung), and

axial distribution (inner 1/3 vs. outer 2/3). We then identified patients referred for CTB following the non-diagnostic ENB biopsy. Again, we evaluated the biopsied lesions for size, vertical (upper or lower lung), and axial distribution (inner 1/3 vs. outer 2/3), and if the CTB was diagnostic in the given clinical and imaging scenario using the previously described criteria to define a diagnostic sample [Table 1].

## Research ethics standards compliance

This original article was completed under an institutional review board (IRB) approved protocol which waived the need for informed consent. The IRB number was 2004777. All procedures performed in studies involving human participants were in accordance with the ethical standards of the institutional and/or national research committee and with the 1964 Helsinki Declaration and its later amendments or comparable ethical standards.

## Statistical analysis

The statistical analysis was performed with a commercially available statistical package, SPSS for Windows, Version 15.0

**Table 1:** Demographic, nodule, and pathologic characteristics of CT and ENB patients/samples.

Mean age (y)	62.4±12.8
Sex (M:F %)	51:49
Average nodule size (mm)	28.2±16.7
Smokers in both ENB and CTB groups (%)	77
Pathology on ENB (%)	
Neuroendocrine	7
Carcinoid	1
NSCLC	27
SCLC	2
Miscellaneous*	63
Pathology on CTB (%)	
Neuroendocrine	9
NSCLC	43
Pulmonary hamartoma	4
Metastatic	13
Miscellaneous*	30
Size of nodule (%)	
<21.5 mm	33 (n=45)
>21.5 mm	67 (n=90)
Location (%)	
Upper lung	56 (n=76)
Lower lung	44 (n=59)
Distribution (%)	
Peripheral 2/3	64 (n=87)
Central 1/3	36 (n=48)

y: Years, M: Male, F: Female, SCLC: Small cell lung cancer, NSCLC: Non-small cell lung cancer, \*Non-diagnostic/granulomatous/inflammation. ENB: Electromagnetic navigational bronchoscopy, CT: Computed tomography, CTB: CT-guided biopsy

(IBM SPSS for Windows, Version 15.0). Chi-square or rank sum tests were used to examine the association of patient's age, sex, nodule side, shape, size, vertical (upper or lower), axial (inner 1/3 or outer 2/3) distribution, characteristics (solid or ground glass), and ENB biopsy yield. Logistic regression was used to examine the association between nodule location (upper or lower lung), peripheral, or central and size (> or < than 21.5 mm) with the probability of a failed ENB (ENB non-diagnostic= "N"). A classification tree method was used to find an optimal cut-point for nodule size which indicated 21.5 mm being the strongest single value in predicting ENB failure. A significance level ( $P < 0.05$ ) was applied for all analyses.

## RESULT

Overall, ENB biopsies were performed in 135 patients with solitary lung lesions. ENB biopsies were diagnostic in 52% (70/135) of the patients. In 23 patients with solitary lung lesions, CTBs were performed following a non-diagnostic ENB biopsy. The CTBs were diagnostic in 87% of the patients (20/23). ENB biopsies of lesions <21.5 mm were non-diagnostic in 71% of cases (42/59); 14 of these patients with non-diagnostic ENB biopsies had CTBs, and 86% of them were diagnostic (12/14). ENB biopsies of lesions in the lower lobes were non-diagnostic in 59% of cases (35/59); 12 of these patients with non-diagnostic ENB biopsies had CTBs, and 83% were diagnostic (10/12). ENB biopsies of lesions in the outer 2/3 were non-diagnostic in 57% of cases (50/87); 21 of these patients with non-diagnostic ENB biopsies had CTBs, and 86% were diagnostic (18/21) [Table 2]. In the logistic regression model, the probability of "ENB failure," i.e., not yielding a diagnostic result, the size ( $P = 0.002$ ), the location of the nodule in the lower lobe ( $P = 0.043$ ), and outer 2/3 of the lung ( $P = 0.012$ ) were significant. If the nodule measured < 21.5 mm, in the lower lobe and in the outer 2/3 of the lung, the odds of a non-diagnostic ENB biopsy were nearly 6, 2.3, and 3 times greater, relative to a nodule >21.5 mm, in the upper lobe and inner 1/3 of the lung [Table 3], respectively.

The probability of a diagnostic ENB was highest, if the nodule was in the upper lobe, inner 1/3 and larger than 21.5 mm (84%) [Table 4]. About 13% of patients who underwent CTBs developed pneumothorax, however none required placement of a chest tube. About 2% (4/135) of patients who underwent ENB biopsy developed a pneumothorax, with only 2% (3/135) requiring placement of a chest tube.

## DISCUSSION

ENB with biopsy is a relatively new technology for evaluation of the SPN, reportedly associated with a decreased risk of pneumothorax and other complications when compared to CTB, however ENB biopsy increases average costs by \$3719 per case and increases video assisted thoracoscopy rates by an absolute 20%.<sup>[28]</sup> The patients with a non-diagnostic ENB biopsy may need a subsequent CTB for work up, which can lead to patient anxiety in the period between the non-diagnostic sampling and subsequent CTB, and loss of valuable time to initiate appropriate treatment.

Before ENB is performed, images from a detailed chest CT examination (performed as per the vendors protocol) are loaded into a software package, which generates a three-dimensional image of the lungs and airways. After identifying the nodule of interest, the software generates a virtual bronchoscopic view and a proposed pathway to the nodule through the fourth and fifth generational bronchi [Figure 1a]. The bronchoscopist navigates to the lung nodule with guidance from the pathway. Once in the vicinity of the nodule, several biopsy instruments can then be used to sample the nodule, including a needle, brush, and biopsy forceps (or variants and combinations of these). The sampling is often performed using fluoroscopic guidance. Having rapid on-site evaluation of the cytologic specimens collected during the procedure can provide feedback to the bronchoscopist regarding the need for additional sampling or repeat navigation.

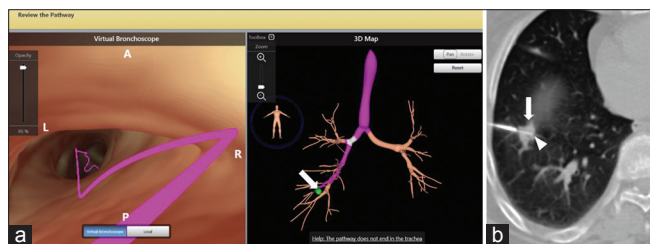
This study evaluated the performance of CTB when ENB failed to obtain a clinically diagnostic yield. The CTBs were obtained in

**Table 2:** Non-diagnostic rates of CT and ENB by nodule size, location, and distribution.

Size	n	%	Non-diagnostic CT biopsy	Non-diagnostic ENB biopsy
<21.5 mm	45	33	14	71
>21.5 mm	90	67	11	30
Location	n	%	Non-diagnostic CT biopsy	Non-diagnostic ENB biopsy
Upper lung	76	56	6	39
Lower lung (including middle lobe lesions)	59	44	17	59
Distribution	n	%	Non-diagnostic CT biopsy	Non-diagnostic ENB biopsy
Outer 2/3	87	64	14	57
Inner 1/3	48	36	0	31

ENB: Electromagnetic navigational bronchoscopy, CT: Computed tomography

the patient population following a non-diagnostic ENB, serves as an internal control to compare the performance of these two modalities without the influence of confounding factors. Overall, ENB was diagnostic in 52% of cases, significantly less



**Figure 1:** Planning electromagnetic navigational bronchoscopy (ENB) for a slowly growing nodule in the right lower lobe (white arrow). Images show the virtual bronchoscopic and 3D maps (a) to help navigate the bronchoscope close to the right lower lobe nodule and facilitate biopsy. These maps are created using the CT data set obtained before the procedure. A CT-guided biopsy was subsequently performed as the ENB biopsy was non-diagnostic. The axial CT image (b) obtained during the procedure with the needle (white arrowhead) deployed in the center of the nodule (white arrows) before obtaining the sample. The CT biopsy sample showed non- small cell cancer.

than reported in the previous studies.<sup>[23,24,26,29,30]</sup> The reason for the low diagnostic rate in our study is not clear. However, some potential factors may be non-availability of a cytopathologist in the procedure room and lack of experience of the IP with ENB and use of smaller gauge needles. The probability of a diagnostic ENB was highest, if the nodule was in the upper lobe, inner 1/3 and larger than 21.5 mm (84%). The overall diagnostic rate for CTB was 87% (20/23) in our study, lower than rates reported in prior studies evaluating the performance of CTB.<sup>[1,18-20]</sup> This may be attributable to the nodule characteristics in the CTB group, with the majority of these nodules being smaller than 21.5 mm 14/23 (61%), in lower lobes 12/23 (52%), and in the outer thirds of the lung 21/23 (91%) [Figure 1b].

Pneumothorax was the most common complication after biopsy in both groups. In our study, 13% of patients who underwent CTB developed a pneumothorax, however none required placement of a chest tube since these were typically of minor extent and not symptomatic. The pneumothorax and chest tube rates were less when compared with the values of 20.5% (range, 4–62%) and 7.3% (range, 0–31%), respectively, reported in the literature.<sup>[20-22,31]</sup> The reason for the low rate of pneumothorax with CTB is not exactly clear, but maybe related to the experience of the IRs, use of small caliber needles and limited sampling. In our analysis, 2% (4/135) of patients who underwent ENB biopsy developed a pneumothorax, with only 2% (3/135) requiring placement of a chest tube, compared with values of 1.5% (range, 0–7.5%) and 0.6%, respectively, reported in the literature.<sup>[23,32,33]</sup> Although the numbers are small to draw any conclusions, more patients with a pneumothorax after ENB (75%) required chest tube placement, which typically requires hospitalizations and adds significant costs.

One potential benefit of the ENB tissue sampling approach is the ability to sample thoracic lymph nodes (e.g., for staging purposes) during the same intervention. However, some studies have reported very high negative predictive values

**Table 3:** Odds ratio of non-diagnostic ENB based on nodule size and location.

Nodule	P value	Odds ratio estimates		
		Point estimate	95% Confidence limits	
Size <21.5 mm	<0.0002	5.77	2.70	12.35
Inner 1/3 or outer 2/3	0.0125	2.82	1.25	6.37
Lower or upper lobe	0.0453	2.26	1.02	5.00

ENB: Electromagnetic navigational bronchoscopy

**Table 4:** Probability of a diagnostic biopsy with ENB and CT depending of nodule size, and location.

Probability of a non-diagnostic ENB biopsy					Non-diagnostic ENB biopsies referred for CT (n=23)		
Size < 2.1 cm	Mid or outer 1/3	Lower or mid location	Estimated probability	95% Prediction limits	# Cases	# CT diagnostic	% CT diagnostic
No	No	No	0.167	0.082 0.310	1	1	100
No	No	Yes	0.291	0.153 0.483	--		
No	Yes	No	0.362	0.235 0.510	5	4	80
No	Yes	Yes	0.537	0.368 0.697	5	5	100
Yes	No	No	0.516	0.290 0.735	--		
Yes	No	Yes	0.685	0.455 0.850	1	1	100
Yes	Yes	No	0.750	0.568 0.873	5	5	100
Yes	Yes	Yes	0.860	0.719 0.936	6	4	67

ENB: Electromagnetic navigational bronchoscopy, CT: Computed tomography

for positron emission tomography (PET) scan for staging patients with lung cancer.<sup>[34,35]</sup> These studies also suggest that lymph node sampling may be unnecessary when the primary lung cancer is <3 cm and the lymph nodes are not avid or enlarged on PET. Lymph node sampling is recommended when the primary lesion is larger than 3 cm, in central lesions or when enlarged lymph nodes are observed on CT.<sup>[34,35]</sup> In our study, 105 patients who underwent ENB biopsy also underwent nodal staging by endobronchial US.

This study certainly has some limitations. The relatively small sample and smaller control size, retrospective study design, single center cohort makes the results less broadly generalizable. Despite careful design and comprehensive review, lack of statistical power represents another possible limitation in our analysis. ENB is relatively new and training for this procedure is not as robust as for CTB, which has been around for several years. This may have contributed to the low diagnostic yield of ENB (learning curve). As overall experience with ENB increases, future studies with larger control groups matched for all confounding factors including operator experience can provide a more accurate head to head comparison between the two modalities.

## CONCLUSION

CTBs have a high diagnostic yield, regardless of nodule size and locations and even following non-diagnostic ENB biopsies. CT was diagnostic in 87% of the cases that had a non-diagnostic ENB biopsy. Lesions <21.5 mm, in the outer 2/3, and in the lower lungs have the lowest likelihood of diagnosis with ENB biopsy. Although associated with a slightly higher pneumothorax rate, CT should be the preferred modality to biopsy these lesions, given the higher diagnostic yield, (particularly in patients who do not need concomitant staging of mediastinal and hilar nodes) to ensure judicious use of medical resources and for expedient diagnosis.

## Declaration of patient consent

Institutional Review Board (IRB) permission obtained for the study.

## Financial support and sponsorship

Nil.

## Conflicts of interest

There are no conflicts of interest.

## Acknowledgments

We acknowledge Greg Petroski, PhD for his help with the statistics pertaining to the paper and Philip Ong, MD,

Assistant Professor, Department of Clinical Medicine -Pulmonary Disease, University of Texas Health Science Center, San Antonio, Texas, United States for the ENB picture.

## REFERENCES

- Ost D, Fein AM, Feinsilver SH. Clinical practice. The solitary pulmonary nodule. *N Engl J Med* 2003;348:2535-42.
- Swensen SJ, Silverstein MD, Ilstrup DM, Schleck CD, Edell ES. The probability of malignancy in solitary pulmonary nodules. Application to small radiologically indeterminate nodules. *Arch Intern Med* 1997;157:849-55.
- National Lung Screening Trial Research Team. Reduced lung-cancer mortality with low-dose computed tomographic screening. *N Engl J Med* 2011;365:395-409.
- Patz EF, Greco E, Gatsonis C, Pinsky P, Kramer BS, Aberle DR. Lung cancer incidence and mortality in national lung screening trial participants who underwent low-dose CT prevalence screening: A retrospective cohort analysis of a randomised, multicentre, diagnostic screening trial. *Lancet Oncol* 2016;17:590-9.
- Yasin J, Thimmappa N, Kaifi JT, Avella DM, Davis R, Tewari SO, *et al.* CT-guided cryoablation for post-thoracotomy pain syndrome: A retrospective analysis. *Diagn Interv Radiol* 2020;26:53-7.
- Taioli E, Lieberman-Cribbin W, Rosenzweig S, Van Gerwen MA, Liu B, Flores RM. Early stage lung cancer survival after wedge resection and stereotactic body radiation. *J Thorac Dis* 2018;10:5702-13.
- Cao C, Wang D, Chung C, Tian D, Rimner A, Huang J, *et al.* A systematic review and meta-analysis of stereotactic body radiation therapy versus surgery for patients with non-small cell lung cancer. *J Thorac Cardiovasc Surg* 2019;157:362-73.
- Schuchardt P, Yasin J, Davis RM, Thimmappa N, Bhat AP. Pelvic trauma. *Contemp Diagn Radiol* 2019;42:1-6.
- Ost DE, Gould MK. Decision making in patients with pulmonary nodules. *Am J Respir Crit Care Med* 2012;185:363-72.
- Al-Ameri A, Malhotra P, Thygesen H, Plant PK, Vaidyanathan S, Karthik S, *et al.* Risk of malignancy in pulmonary nodules: A validation study of four prediction models. *Lung Cancer* 2015;89:27-30.
- Swensen SJ, Silverstein MD, Edell ES, Trastek VF, Aughenbaugh GL, Ilstrup DM, *et al.* Solitary pulmonary nodules: Clinical prediction model versus physicians. *Mayo Clin Proc* 1999;74:319-29.
- Ghouri MA, Gupta N, Bhat AP, Thimmappa ND, Saboo SS, Khandelwal A, *et al.* CT and MR imaging of the upper extremity vasculature: Pearls, pitfalls, and challenges. *Cardiovasc Diagn Ther* 2019;9:S152-73.
- Bhat A, Layfield LJ, Tewari SO, Gaballah AH, Davis R, Wu Z. Solitary fibrous tumor of the ischioanal fossa-a multidisciplinary approach to management with radiologic-pathologic correlation. *Radiol Case Rep* 2018;13:468-74.
- Patel PJ, Hieb RA, Bhat AP. Percutaneous revascularization of chronic total occlusions. *Tech Vasc Interv Radiol* 2010;13:23-36.
- Gould MK, Fletcher J, Iannettoni MD, Lynch WR, Midthun DE, Naidich DP, *et al.* Evaluation of patients with pulmonary nodules: When is it lung cancer?: ACCP evidence-

- based clinical practice guidelines (2nd Edition). *Chest* 2007;132:108S-30.
16. Bhat AP, Schuchardt PA, Bhat R, Davis RM, Singh S. Metastatic appendiceal cancer treated with yttrium 90 radioembolization and systemic chemotherapy: A case report. *World J Radiol* 2019;11:116-25.
  17. Rivera MP, Mehta AC. Initial diagnosis of lung cancer: ACCP evidence-based clinical practice guidelines (2nd Edition). *Chest* 2007;132:131S-48.
  18. DiBardino DM, Yarmus LB, Semaan RW. Transthoracic needle biopsy of the lung. *J Thorac Dis* 2015;7:S304-16.
  19. Yao X, Gomes MM, Tsao MS, Allen CJ, Geddie W, Sekhon H. Fine-needle aspiration biopsy versus core-needle biopsy in diagnosing lung cancer: A systematic review. *Curr Oncol* 2012;19:e16-27.
  20. Winokur RS, Pua BB, Sullivan B, Madoff DC. Percutaneous lung biopsy: Technique, efficacy, and complications. *Semin Intervent Radiol* 2013;30:121-7.
  21. Wiener RS, Schwartz LM, Woloshin S, Welch HG. Population-based risk for complications after transthoracic needle lung biopsy of a pulmonary nodule: An analysis of discharge records. *Ann Intern Med* 2011;155:137-44.
  22. Bungay HK, Berger J, Traill ZC, Gleeson F V. Pneumothorax post CT-guided lung biopsy: A comparison between detection on chest radiographs and CT. *Br J Radiol* 1999;72:1160-3.
  23. Bhatt KM, Tandon YK, Graham R, Lau CT, Lempel JK, Azok JT, *et al.* Electromagnetic navigational bronchoscopy versus CT-guided percutaneous sampling of peripheral indeterminate pulmonary nodules: A cohort study. *Radiology* 2018;286:1052-61.
  24. Zhang W, Chen S, Dong X, Lei P. Meta-analysis of the diagnostic yield and safety of electromagnetic navigation bronchoscopy for lung nodules. *J Thorac Dis* 2015;7:799-809.
  25. Du Rand IA, Barber PV, Goldring J, Lewis RA, Mandal S, Munavvar M, *et al.* British thoracic society guideline for advanced diagnostic and therapeutic flexible bronchoscopy in adults. *Thorax* 2011;66 Suppl 3:iii1-21.
  26. Ozgul G, Cetinkaya E, Ozgul MA, Abul Y, Gencoglu A, Kamiloglu E, *et al.* Efficacy and safety of electromagnetic navigation bronchoscopy with or without radial endobronchial ultrasound for peripheral lung lesions. *Endosc Ultrasound* 2016;5:189-95.
  27. Schuchardt PA, Yasin JT, Davis RM, Tewari SO, Bhat AP. The role of an IVC filter retrieval clinic-A single center retrospective analysis. *Indian J Radiol Imaging* 2019;29:391-6.
  28. Dale CR, Madtes DK, Fan VS, Gorden JA, Veenstra DL. Navigational bronchoscopy with biopsy versus computed tomography-guided biopsy for the diagnosis of a solitary pulmonary nodule: A cost-consequences analysis. *J Bronchol Interv Pulmonol* 2012;19:294-303.
  29. Gex G, Pralong JA, Combescure C, Seijo L, Rochat T, Soccia PM. Diagnostic yield and safety of electromagnetic navigation bronchoscopy for lung nodules: A systematic review and meta-analysis. *Respiration* 2014;87:165-76.
  30. Thimmappa N, Bhat AP, Bishop K, Nagpal P, Prince MR, Saboo SS. Preoperative cross-sectional mapping for deep inferior epigastric and profunda artery perforator flaps. *Cardiovasc Diagn Ther* 2019;9:S131-42.
  31. Bhat AP, Pimpalwar A, Dyke PC. Ultrasonography and X-Ray guided drain placement to evacuate a pneumopericardium/pneumomediastinum in a 1-day-old infant. *Indian J Radiol Imaging* 2019;29:94-7.
  32. Memoli JS, Nietert PJ, Silvestri GA. Meta-analysis of guided bronchoscopy for the evaluation of the pulmonary nodule. *Chest* 2012;142:385-93.
  33. Verma M, Yarlagadda B, Hendrani A, Bhat AP, Kumar S. Simplified rapid protocol for assessing the thoracic aortic dimensions and pathology with noncontrast MR angiography. *Int J Angiol* 2019;28:130-6.
  34. Graeter TP, Hellwig D, Hoffmann K, Ukena D, Kirsch CM, Schäfers HJ. Mediastinal lymph node staging in suspected lung cancer: Comparison of positron emission tomography with F-18-fluorodeoxyglucose and mediastinoscopy. *Ann Thorac Surg* 2003;75:231-6.
  35. De Leyn P, Doooms C, Kuzdzal J, Lardinois D, Passlick B, Rami-Porta R, *et al.* Revised ESTS guidelines for preoperative mediastinal lymph node staging for non-small-cell lung cancer. *Eur J Cardiothorac Surg* 2014;45:787-98.

**How to cite this article:** Atkins NK, Marjara J, Kaifi JT, Kunin JR, Saboo SS, Davis RM, *et al.* Role of computed tomography-guided biopsies in the era of electromagnetic navigational bronchoscopy: A retrospective study of factors predicting diagnostic yield in electromagnetic navigational bronchoscopy and computed tomography biopsies. *J Clin Imaging Sci* 2020;10:33.