



Genitourinary and Gynecologic Imaging Case Report

## Ruptured pyomyoma – Rare complication of post-uterine artery embolization: A case report

Sai Swarupa Reddy Vulasala<sup>1</sup> , Dheeraj Reddy Gopireddy<sup>1</sup>, Khaled Mohamed<sup>2</sup>, Chandana Lall<sup>1</sup>

Departments of <sup>1</sup>Radiology and <sup>2</sup>Pathology, University of Florida College of Medicine-Jacksonville, Jacksonville, Florida, United States.



**\*Corresponding author:**

Sai Swarupa Reddy Vulasala,  
Department of Radiology,  
University of Florida College  
of Medicine-Jacksonville,  
Jacksonville, Florida, United  
States.

[vulasalaswarupa@gmail.com](mailto:vulasalaswarupa@gmail.com)

Received : 06 October 2021  
Accepted : 30 November 2021  
Published : 23 December 2021

DOI  
10.25259/JCIS\_188\_2021

Quick Response Code:



### ABSTRACT

Leiomyomas, also termed as fibroids, are benign smooth, muscle neoplasms seen in 70–80% of women by the age of 50 years. Uterine artery embolization (UAE) is a minimally invasive procedure that involves cessation of vascular supply to the fibroids, by infusion of gelatinous microspheres into the uterine arteries. Pyomyoma is a suppurative leiomyoma, secondary to infection of necrotic tissue. It is an infrequent complication of uterine artery embolization (UAE). Pyomyoma can lead to sepsis, peritonitis, and respiratory distress syndrome resulting in high morbidity and mortality. Due to its rarity, high suspicion is crucial in the diagnosis, and prompt treatment is recommended to reduce mortality. Ultrasound, computed tomography, and magnetic resonance imaging assist in diagnosis. We present a case of a 44-year-old woman with ruptured pyomyoma, following an UAE intervention. The patient was treated with total abdominal hysterectomy and salpingo-oophorectomy along with peritoneal irrigation and drainage.

**Keywords:** Pyomyoma, Uterine artery embolization, Uterine artery embolization complications, Ruptured pyomyoma, Peritonitis

### INTRODUCTION

Pyomyoma is an infected leiomyoma that can develop spontaneously, or be observed in postpartum, post-surgical, and postmenopausal phases.<sup>[1]</sup> It forms secondary to infarction, necrosis, and infection of uterine leiomyoma.<sup>[1]</sup> Pyomyoma, secondary to uterine artery embolization (UAE) is a rare complication with a higher mortality rate ranging from 20 to 30%.<sup>[2]</sup> UAE induces ischemia and infarction of leiomyoma by occluding uterine arteries.<sup>[3]</sup> The infarcted tissue serves as a nidus for microbes, leading to the formation of pyomyoma. Pyomyoma in post-UAE patients is rare, and to the best of our knowledge, only 11 cases were reported in the literature.<sup>[4]</sup> The diagnosis is arduous due to non-specific clinical and radiological findings. Strong clinical suspicion is imperative in correlating the findings for prompt diagnosis. In this manuscript, we have described a case of ruptured pyomyoma which ensued after the UAE procedure.

### CASE REPORT

A 44-year-old woman was presented to the emergency room, with complaints of vaginal bleeding and fatigue. She had a prior history of fibroids and underwent UAE, 30 days before the current presentation.

This is an open-access article distributed under the terms of the Creative Commons Attribution-Non Commercial-Share Alike 4.0 License, which allows others to remix, tweak, and build upon the work non-commercially, as long as the author is credited and the new creations are licensed under the identical terms.

©2021 Published by Scientific Scholar on behalf of Journal of Clinical Imaging Science

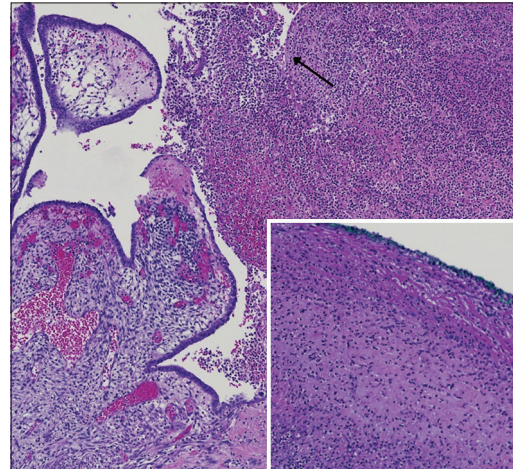
During the current visit, her hemoglobin was noted to be 5.1 g/dl, and she received packed red blood cell transfusions. She was noted to have a persistent lower abdominal pain and fever. Pertinent laboratory investigations, including COVID swab, respiratory panel, blood culture, and urine culture, were negative. Diagnostic imaging with computed tomography (CT) scan was performed, which revealed an enlarged uterus with necrotic fibroids containing a large pocket of gas/fluid within the endometrial cavity, uterine perforation along with the fundal fibroid, dilated right fallopian tube, and inflamed right ovary. CT findings in conjunction with a clinical picture raised a suspicion for a ruptured pyomyoma with ovarian adhesions, ensued post-UAE. The patient was initiated on intravenous fluids and antibiotics. She was taken to the operating room, and a total abdominal hysterectomy with bilateral salpingectomy and right oophorectomy was performed. The intra-operative findings include 6 cm fundal fibroid with two necrotic foci of 1 cm each, draining pus into the peritoneal cavity, 5 cm anterior exophytic fibroid, 3 cm posterior exophytic fibroid, and right ovarian adhesions to the uterus. The gross examination of the resected specimen revealed multiple fibroids, one of which had evidence of necrosis, as shown in [Figure 1a and b]. [Figures 2 and 3] describe the histopathological findings of acute inflammation. Post-operatively, the patient was continued on antibiotics and was discharged from the hospital after a favorable recovery.

## DISCUSSION

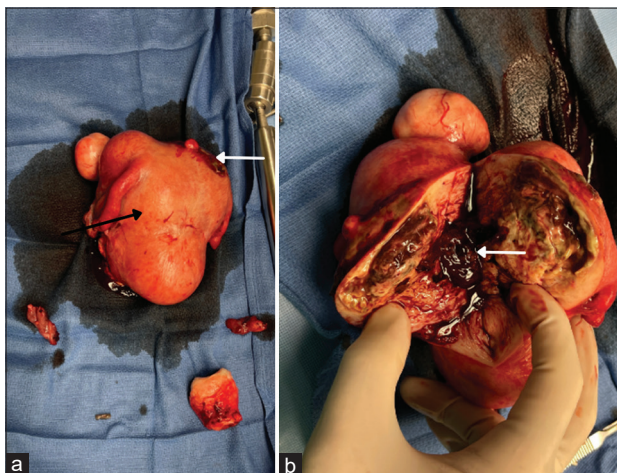
Uterine leiomyomas are the most prevalent benign neoplasms, comprising of smooth muscle and fibrous

connective tissue. Its prevalence ranges from 70 to 80% in women of aged 50 years.<sup>[3]</sup> Abnormal uterine bleeding and pelvic pressure are the most common symptoms of leiomyoma.<sup>[3]</sup> Conservative therapy of leiomyomas includes oral contraceptive pills and gonadotropin-releasing hormone agonists. Surgically, fibroids can be managed through myomectomy, magnetic resonance (MR)-guided high-intensity focused ultrasound, UAE, and hysterectomy.<sup>[3]</sup>

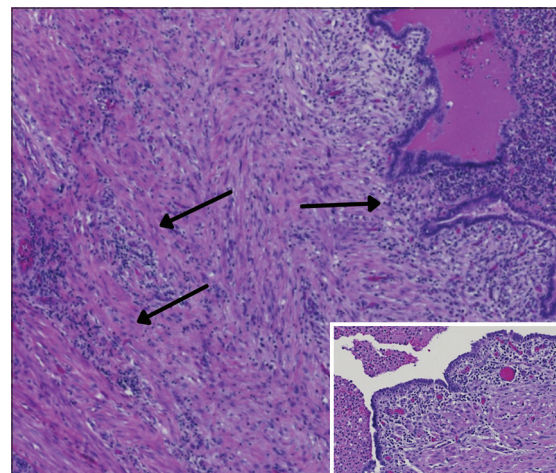
UAE is a minimally invasive procedure performed as an alternative to myomectomy and hysterectomy. It



**Figure 2:** A 44-year-old woman with uterine fibroids status post-uterine artery embolization presented with vaginal bleeding and fatigue. Histopathology of hysterectomy specimen showing acute endometritis with the destruction of the surface epithelium (black arrow) due to marked neutrophilic infiltration extending till the green inked uterine serosa (insert).



**Figure 1:** A 44-year-old woman with uterine fibroids status post-uterine artery embolization presented with vaginal bleeding and fatigue. (a) Gross specimen of uterus after hysterectomy (black arrow), notice the uterine perforation (white arrow). (b) Gross specimen after slicing the uterus demonstrates necrotic material in the uterine cavity (pyometra) (white arrow).



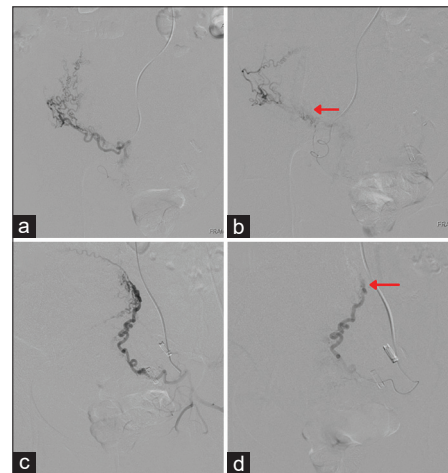
**Figure 3:** A 44-year-old woman with uterine fibroids status post-uterine artery embolization presented with vaginal bleeding and fatigue. Histopathology of hysterectomy specimen showing prominent acute inflammation in the ovarian stroma (black arrows). Insert: Acute salpingitis (neutrophils in lamina) and pyosalpinx (neutrophils in lumen).

involves the injection of gelatinous microspheres into the uterine artery, thereby halting the blood supply to leiomyoma.<sup>[3]</sup> The employment of embolization, helped avoid hysterectomy in 96% and improved symptoms in 74% of the patients, in a study by Yuan *et al.*<sup>[5]</sup> Besides, polyvinyl alcohol particles (PVA), tris-acryl gelatin microspheres, and gelatin sponge particles are being used as embolic agents in the UAE. Various complications associated with these agents are listed in [Table 1]. The resulting ischemia, due to UAE, leads to infarction and necrosis of target leiomyoma. Post-interventional complications include fibroid expulsion, infection (endometritis, tubo-ovarian abscess, and pyomyoma), pulmonary embolism, and fibroid regrowth.

Pyomyoma is an infrequent complication characterized by the infected necrotic tissue of embolized leiomyoma.<sup>[4]</sup> Often, it is due to polymicrobial infection, including anaerobic, Gram-positive, and Gram-negative bacteria, submucosal leiomyomas, elderly old age, pre-existing infection, intravenous drug users, presence of intra-uterine devices, diabetes, hypertension, post-partum, and immunocompromised states are the known risk factors predisposing patients to pyomyoma.<sup>[6]</sup> Employing UAE in patients with leiomyoma of size <8 cm reduces the risk of pyomyoma. [Figure 4a-d] shows embolization of the right and left uterine arterial branches with PVA; post-embolization, there is a significant reduction in the vascularity of the fibroids.

After embolization, the route of infection is often a direct spread from the endometrial cavity, adnexa, bowel, or blood.<sup>[1]</sup> Pyomyoma presents with a classic triad of pelvic pain, sepsis, and no an unknown source of infection.<sup>[6]</sup> However, diagnosis based on clinical findings is challenging, as its presentation mimics post-embolization syndrome (PES), which may also present with pelvic pain, elevated white cell count, and fever within 1 week of UAE.<sup>[4,7]</sup> PES can be seen in 21% of patients undergoing UAE, and is a self-limiting condition managed with hydration, pain control,

and anti-inflammatory medications.<sup>[4]</sup> The persistence of symptoms beyond 1 week should raise suspicion of pyomyoma.<sup>[7]</sup> Table 2 describes the differentiating features of pyomyoma and PES. Alternate differential diagnoses of pyomyoma include tubo-ovarian abscess, infected ectopic pregnancy, degenerated leiomyoma, or malignancy [Table 3].<sup>[8]</sup> Pyomyoma might traverse the thickness of the myometrium and rupture into the peritoneal cavity or the



**Figure 4:** A 44-year-old woman with uterine fibroids status post-uterine artery embolization presented with vaginal bleeding and fatigue. (a and b) Angiography of the right uterine artery. (a) Pre-embolization image of the right uterine artery. (b) 500–700 micron polyvinyl alcohol particles (PVA) mixed with contrast were injected into the right uterine artery. Notice the decreased flow in post-embolization image (red arrow). (c and d) Angiography of the left uterine artery. (c) pre-embolization image of the left uterine artery. (d) 500–700 micron PVA particles mixed with contrast were injected into the left uterine artery. Post-embolization, there is a decreased flow in the left uterine arterial branches (red arrow).

**Table 1:** A 44-year-old woman with uterine fibroids, status post-uterine artery embolization presented with vaginal bleeding and fatigue. The table describes the embolic agents and their complications.

Embolic agent	Complications
Polyvinyl alcohol	Uterine ischemia, endometrial infection, ovarian dysfunction, tubal dysfunction permanent amenorrhea, and pulmonary embolism
Tris-acryl gelatin microspheres	Permanent amenorrhea
Gelatin sponge	Acute inflammatory reaction; abscess formation; and vascular recanalization

**Table 2:** A 44-year-old woman with uterine fibroids status post-UAE presented with vaginal bleeding and fatigue. Table described the differentiating features of pyomyoma and post-embolization syndrome.

	Pyomyoma	Post-embolization syndrome
Foul smelling vaginal discharge	Present	Absent
Course of symptoms	Over days to weeks after UAE	Within a few days of UAE
Leukocytosis	High-grade leukocytosis	Reactive leukocytosis
Response to therapy	Responds to antibiotic therapy	Responds to anti-inflammatory and pain medications
Prognosis	Worse	Good

UAE: Uterine artery embolization

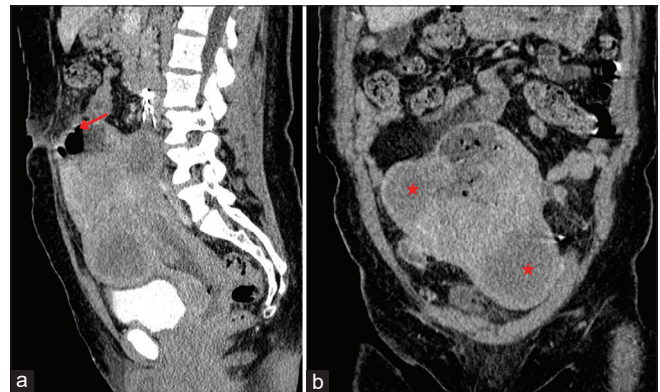
endometrial cavity resulting in peritonitis or pyometra, respectively, as shown in [Figures 1 and 5].<sup>[2]</sup>

Imaging findings of pyomyoma on ultrasonography demonstrate a heterogeneous mass with solid and cystic echogenic foci.<sup>[9]</sup> The reverberation artifacts and echogenic foci within the lesion indicate suppurative (gas forming) pyomyoma.<sup>[9]</sup> In the presence of concomitant endometritis, there are abnormal echoes in the uterine cavity, as shown in [Figure 6]. CT images displaying gas-filled uni- or multilocular mass suggest contained pyomyoma [Figure 5].<sup>[9]</sup> Gas within leiomyoma can also be considered a normal post-UAE finding in patients with no signs of infection.<sup>[7]</sup> The ruptured pyomyoma is evident by visualizing the disrupted wall of the leiomyoma and the presence of gas and fluid in the peritoneal cavity.<sup>[9]</sup>

Pre-procedural MR imaging assists in a comprehensive evaluation of potential candidates for UAE, thereby reducing the post-procedural complications. Fibroids with high signal intensity on T2-weighted (T2W) MR imaging show greater size reduction in size following UAE.<sup>[10]</sup> Furthermore, fibroids with strong perfusion on T1 perfusion imaging adapt to UAE better than those with weak perfusion. Demonstration of infarcted fibroid and pedunculated fibroid

on MR imaging is considered a contraindication to UAE. Hemorrhagic infarction (red degeneration) displays high signal intensity on T1-weighted (T1W) imaging and variable intensity on T2W imaging. In addition, MR imaging assesses the post-UAE response of leiomyomas and identifies the complications such as pyomyoma.

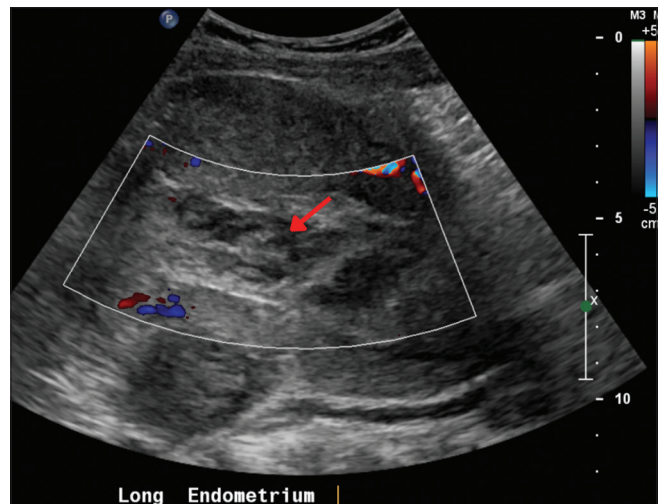
MR imaging of pyomyoma shows a cystic mass that is hypo- to iso-intense on T1W imaging, and hypo- to hyper-intense on T2W imaging.<sup>[9]</sup> Besides, similar findings on MR imaging can be elicited in patients with degenerated leiomyoma.<sup>[9]</sup> The demonstration of the fibrous capsule surrounding the mass is the distinguishing feature that is indicative of pyomyoma.



**Figure 5:** A 44-year-old woman with uterine fibroids status post-uterine artery embolization presented with vaginal bleeding and fatigue. (a) Sagittal and (b) coronal CT demonstrates the fundal necrotic fibroid with perforation (arrow), notice multiple non-enhancing fibroids (star).

**Table 3:** A 44-year-old woman with uterine fibroids status post-uterine artery embolization presented with vaginal bleeding and fatigue. The table describes the magnetic resonance imaging features of the differential diagnosis of pyomyoma.

Differential diagnosis	MRI findings
Tubo-ovarian abscess	Lateral adnexal location Cystic component: Hypo-intense on T1W imaging and hyper-intense on T2W imaging Post-contrast: Thick enhancing rim
Red degenerated leiomyoma	Diffuse or peripheral hyperintensity on T1W imaging and variable intensity on T2W imaging Rim: Hyperintense on T1W imaging and hypointense on T2W imaging; ill-demarcated border Post-contrast imaging: No enhancement
Endometritis	Enlarged uterus with hyperintense hematoma in the endometrial cavity on T1W imaging; signal voids due to gas on both T1W and T2W imaging No fibrous capsule
Malignant leiomyosarcoma	>50% of fibroid appearing hyperintense on T2W imaging; Multiple hyperintense areas on T1W imaging indicating indicate necrosis and hemorrhage Post-contrast imaging: Avascular pocket-like necrotic areas



**Figure 6:** A 44-year-old woman with uterine fibroids status post-uterine artery embolization presented with vaginal bleeding and fatigue. Gray and color Doppler images of the uterus post-day 30 after embolization demonstrate thickened and heterogeneous content in the cavity with diminished vascularity indicating necrotic area (arrow).

The fibrous capsule appears hyper-intense on T1W imaging and hypo-intense on T2W imaging, and the intensity of the signal from the fibrous capsule is influenced by the free radicals generated by the macrophages.<sup>[9]</sup> The low apparent diffusion co-efficient value and hyper-intensity on diffusion-weighted MR imaging imply pus in the pyomyoma.

The definitive therapy of pyomyoma includes intravenous antibiotics, and myomectomy or hysterectomy, depending on the patient's desire for future pregnancy and the size and number of pyomyoma.<sup>[2]</sup> In a few patients with ruptured pyomyoma, CT- or laparoscopic-guided peritoneal drainage and lavage can be considered with antibiotic therapy.<sup>[6]</sup>

## CONCLUSION

High index of clinical suspicion is imperative in diagnosing pyomyoma, given its rare occurrence and non-specific presentation. A clinical triad of sepsis, leiomyoma, and no known source of infection is suggestive of pyomyoma. Correlation of clinical and multimodality radiological findings aids in accurate diagnosis. On CT imaging, specific signs of discontinuity in the wall and intraperitoneal gas/fluid indicate a rupture of pyomyoma and impending peritonitis. Hysterectomy or myomectomy, along with IV antibiotic therapy, is the definitive treatment of pyomyoma. Peritoneal lavage and irrigation are required in patients with pyomyoma ruptured into the peritoneal cavity.

## ACKNOWLEDGMENT

None.

## Declaration of patient consent

Patient's consent not required as patient's identity is not disclosed or compromised.

## Financial support and sponsorship

Nil.

## Conflicts of interest

There are no conflicts of interest.

## REFERENCES

1. Obele CC, Dunham S, Bennett G, Pagan J, Sung LY, Charles HW. A case of pyomyoma following uterine fibroid embolization and a review of the literature. *Case Rep Obstet Gynecol* 2016;2016:9835412.
2. Karcaaltincaba M, Sudakoff GS. CT of a ruptured pyomyoma. *AJR Am J Roentgenol* 2003;181:1375-7.
3. Rezai S. Pyomyoma following uterine artery embolization (UAE)-dual case report and review of literature. *Obstet Gynecol Int J* 2016;4:9-13.
4. Yu Q, Gabriel G, Hoffman M, Sanampudi S, Jassim T, Raissi D. Uterine-sparing management of pyomyoma after uterine fibroid embolization. *Radiol Case Rep* 2019;14:1031-5.
5. Yuan K, Zhang JL, Yan JY, Yuan B, Fu JX, Wang Y, *et al.* Uterine artery embolization with small-sized particles for the treatment of symptomatic adenomyosis: A 42-month clinical follow-up. *Int J Gen Med* 2021;14:3575-81.
6. Pinto E, Trovão A, Leitão S, Pina C, Mak FK, Lanhos A. Conservative laparoscopic approach to a perforated pyomyoma after uterine artery embolization. *J Minim Invasive Gynecol* 2012;19:775-9.
7. Ezzedine D, Ndubizu C, Kayani S, David A. Pyomyoma after uterine artery embolization: A case report. *Case Rep Womens Health* 2020;26:e00186.
8. DeMaio A, Doyle M. Pyomyoma as a rare source of postpartum sepsis. *Case Rep Obstet Gynecol* 2015;2015:263518.
9. Ono H, Kanematsu M, Kato H, Toyoki H, Hayasaki Y, Furui T, *et al.* MR imaging findings of uterine pyomyoma: Radiologic-pathologic correlation. *Abdom Imaging* 2014;39:797-801.
10. Duc NM, Huy HQ. Effect of magnetic resonance imaging characteristics on uterine fibroid treatment. *Rep Med Imag* 2018;11:1-8.

**How to cite this article:** Vulasala SS, Gopireddy DR, Mohamed K, Lall C. Ruptured pyomyoma – Rare complication of post-uterine artery embolization: A case report. *J Clin Imaging Sci* 2021;11:67.