



Breast Imaging Pictorial Essay

Pregnancy Associated Breast Cancer

Frances Perez¹, Ashley Bragg¹, Gary Whitman¹

¹Department of Breast Imaging, UT Texas MD Anderson Cancer Center, Houston, Texas, United States.



***Corresponding author:**

Frances Perez,
Department of Breast Imaging,
1911 Holcombe Blvd Apt.
1918, Houston - 77030, Texas,
United States.

fperez1@mdanderson.org

Received : 14 April 2021
Accepted : 22 August 2021
Published : 21 September 2021

DOI
10.25259/JCIS_81_2021

Quick Response Code:



ABSTRACT

Pregnancy associated breast cancer (PABC) is a subset of cancer that is too often diagnosed at a more advanced stage due to physiologic changes of the breast and lack of awareness among patients and physicians, resulting in higher mortality rates. While PABC is rare, it is postulated that as women delay childbearing, the rate of PABC may increase. Therefore, it is important to discuss appropriate workup, safety of mammography during pregnancy, and biopsy techniques.

Keywords: Pregnancy associated breast cancer, Breast masses in women who are pregnant, Mammograms in pregnant/breast feeding population

INTRODUCTION

Pregnancy associated breast cancer (PABC) is defined as cancer diagnosed during pregnancy, within 12 months postpartum, or anytime while the patient is lactating. PABC is a rare condition which is increasing in incidence likely due to a combination of delaying childbearing together with an overall increase in breast cancer incidence.^[1] Although it is infrequent, occurring in 0.3 in 1000 pregnancies, it is the most common malignancy in pregnancy and the most common cause of cancer-related death in pregnant and lactating women. The diagnosis of PABC is often delayed and remains a challenge due to the underlying anatomical and physiologic changes of the breast during pregnancy and lactation. Early recognition of PABC is imperative as there is an expected increase in incidence as more women delay childbearing. In addition, PABC is associated with a mortality rate that is 50% higher when compared to non-PABC.^[2]

DIFFERENTIAL DIAGNOSIS OF A BREAST MASS IN A PREGNANT OR A LACTATING WOMAN

The breast may be affected by a variety of physiologic changes and disorders during pregnancy and lactation, which range from benign masses, including cysts, to infectious or inflammatory processes. A breast mass during pregnancy and lactation most often does not represent malignancy. The most common benign masses during this time period include fibroadenomas, galactoceles, and lactating adenomas. Fibroadenomas are the most common breast masses in women between the ages of 25 and 40 years and fibroadenomas tend to regress in size after the age of 40 years.^[3] Due to hormonal influences during pregnancy and lactation, fibroadenomas may demonstrate an increase in size or even infarct.^[4] Galactoceles are breast masses commonly seen

This is an open-access article distributed under the terms of the Creative Commons Attribution-Non Commercial-Share Alike 4.0 License, which allows others to remix, tweak, and build upon the work non-commercially, as long as the author is credited and the new creations are licensed under the identical terms.

©2021 Published by Scientific Scholar on behalf of Journal of Clinical Imaging Science

during lactation and present as complicated cystic masses with fat-fluid levels.^[4] Lactating adenomas are seen late in the third trimester and during lactation. The sonographic appearance of lactating adenomas is often indistinguishable from that of fibroadenomas.^[5]

APPROPRIATE IMAGING WORKUP OF PREGNANT AND LACTATING WOMEN

The workup of a mass in a pregnant or a lactating patient begins with an ultrasound [Figures 1 and 2]. The benefits of

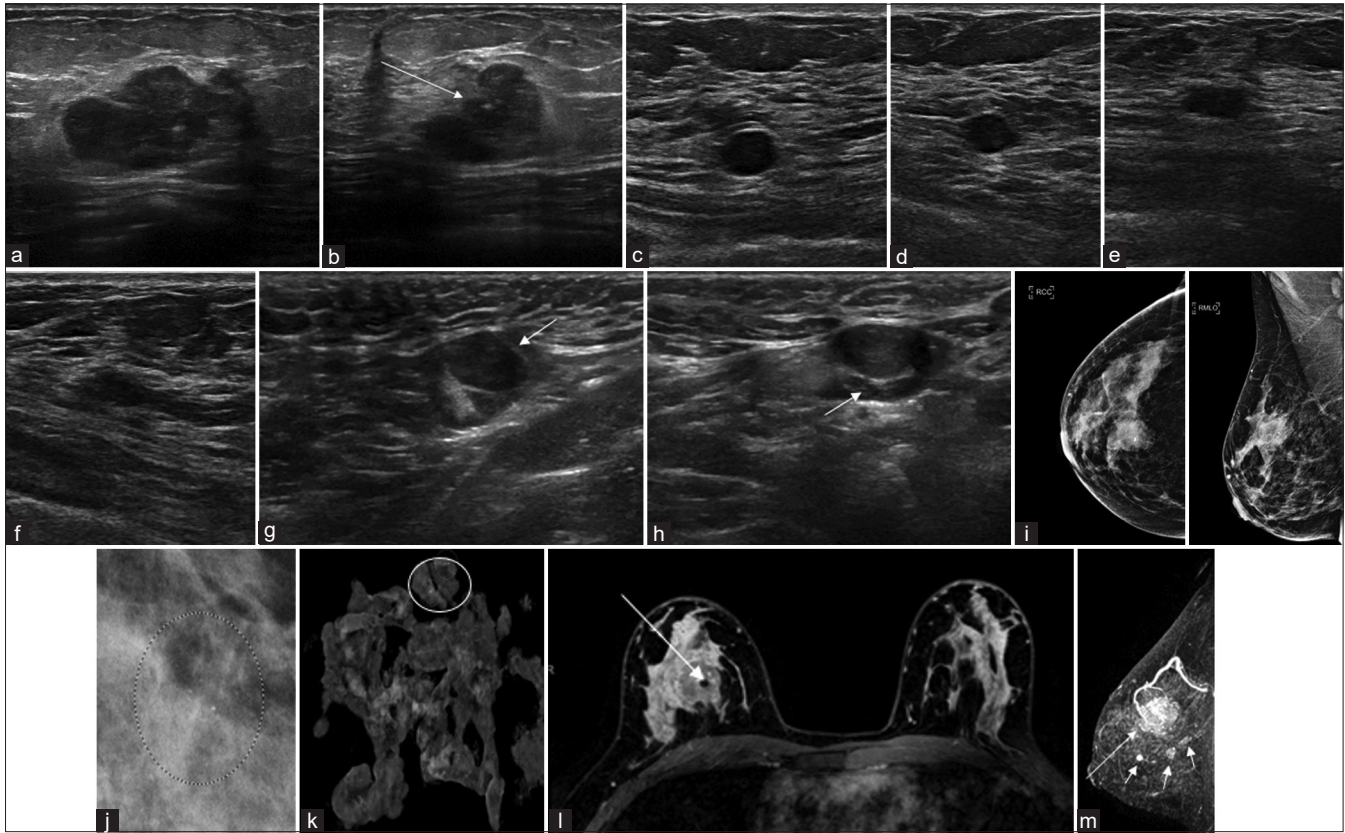


Figure 1: A 38-year-old woman in her third trimester felt a palpable area in the right breast. She presented 2 months after delivery for further evaluation of the palpable area in the right breast. Initial evaluation was performed with a breast ultrasound. Longitudinal (a) and transverse (b) ultrasound of the palpable area in the right breast at the 12 o'clock position, 6 cm from the nipple, demonstrates an irregular mixed echogenicity mass with indistinct margins (long arrow). Longitudinal (c) and transverse (d) ultrasound of the right breast at the 10 o'clock position, 5 cm from the nipple, demonstrates a round hypoechoic mass (short arrow). Longitudinal (e) and transverse (f) ultrasound of the right breast at the 10 o'clock position, 7 cm from the nipple, demonstrates an oval hypoechoic mass with indistinct margins (long arrows). These two masses at the 10 o'clock position, 5 cm (c and d), and 7 cm (e and f) from the nipple were suspicious for additional sites of malignancy. Longitudinal (g) and transverse (h) ultrasound of the right axillary level I region demonstrates an abnormal lymph node (short arrow) with cortical thickening and effacement of the fatty hilum. Ultrasound-guided needle biopsy of the right breast mass at the 12 o'clock position, 6 cm from the nipple, revealed invasive ductal carcinoma. Ultrasound-guided fine-needle aspiration of the abnormal right axillary lymph node demonstrated metastatic carcinoma. (i) Craniocaudal (left) and mediolateral oblique (right) views of the right breast demonstrate an obscured mass (arrows) with an internal clip, measuring $3.1 \times 2.3 \times 2.6$ cm, with associated fine pleomorphic calcifications at the 12 o'clock position, 4 cm from the nipple. The additional masses visualized on ultrasound were mammographically occult. (j) Lateral magnification view of the left breast at the 3 o'clock position, 6 cm from the nipple demonstrates suspicious amorphous calcifications with a grouped distribution (circle). A stereotactic biopsy of the left breast was performed. (k) Specimen radiograph confirms removal of the targeted calcifications (circle). Pathology results of the left breast stereotactic biopsy yielded ductal carcinoma *in situ* (intermediate to high nuclear grade). (l) Axial T1-weighted-contrast-enhanced MRI demonstrates bilateral lactational changes as well as the biopsy proven right breast malignancy with a signal void artifact from the associated marker clip (arrow). (m) Sagittal maximum intensity projection image demonstrate the index malignancy (long arrow) as well as three additional suspicious masses (short arrows) inferior to the index right breast malignancy. All of these masses demonstrated washout kinetics. There was no MRI correlate for the ductal carcinoma *in situ* of the left breast.

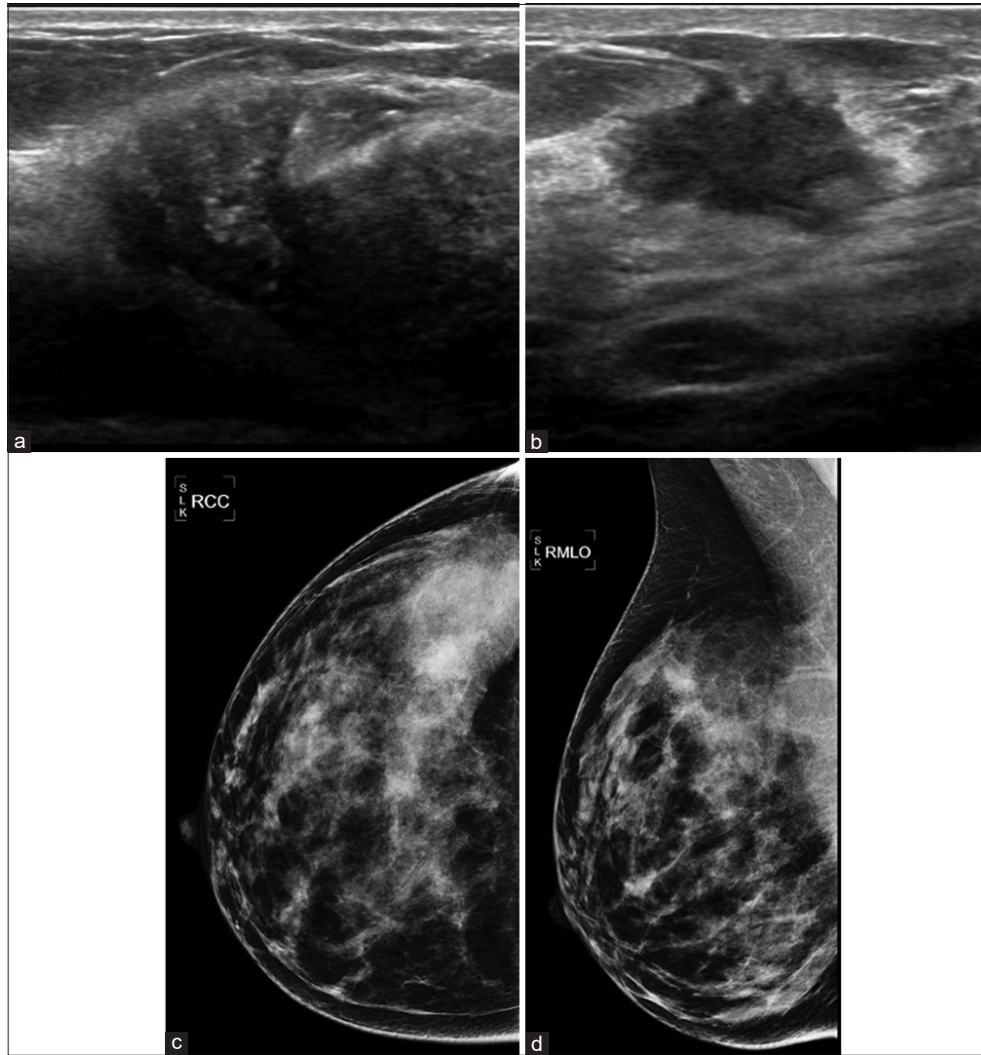


Figure 2: A 26-year-old woman who was 25 weeks pregnant presented with a palpable right breast mass. Initial evaluation was performed with a right breast ultrasound. Longitudinal (a) and transverse (b) ultrasound evaluation of the palpable area in the right breast at the 11 o'clock position, 4 cm from the nipple, demonstrates an irregular hypoechoic $1.4 \times 1.4 \times 1.7$ cm mass (arrow) with associated calcifications. (c) Craniocaudal and (d) mediolateral oblique views of the right breast demonstrated lactation changes. There is an irregular mass with obscured margins at the 11–12 o'clock position, 6 cm from the nipple (arrow). Ultrasound-guided core needle biopsy revealed invasive ductal carcinoma and ductal carcinoma *in situ*.

sonographic imaging include high sensitivity and a lack of ionizing radiation. Some studies have reported sensitivities and negative predictive values as high as 100%.^[1] An additional benefit of ultrasound is that it can detect and characterize benign breast masses.

Mammography is considered generally safe during pregnancy and lactation. The radiation dose from a bilateral two view mammogram is <3 mGy per view, which is roughly equivalent to 7 weeks of background radiation. The radiation dose to the uterus is <0.03 microGy, which is a fraction of

the 50 microGy threshold that is known to cause teratogenic fetal effects.^[6] In addition, a lead apron shield can be used to decrease the dose to the uterus by up to 50%. Despite the relative safety of mammography during pregnancy and lactation, mammography is only indicated if there is a strong suspicion of malignancy or if malignancy has been proven by core needle biopsy [Figure 3].

The sensitivity of mammography, which normally ranges from 78% to 90%, decreases drastically during pregnancy and lactation. The discrepancy between the sensitivities of

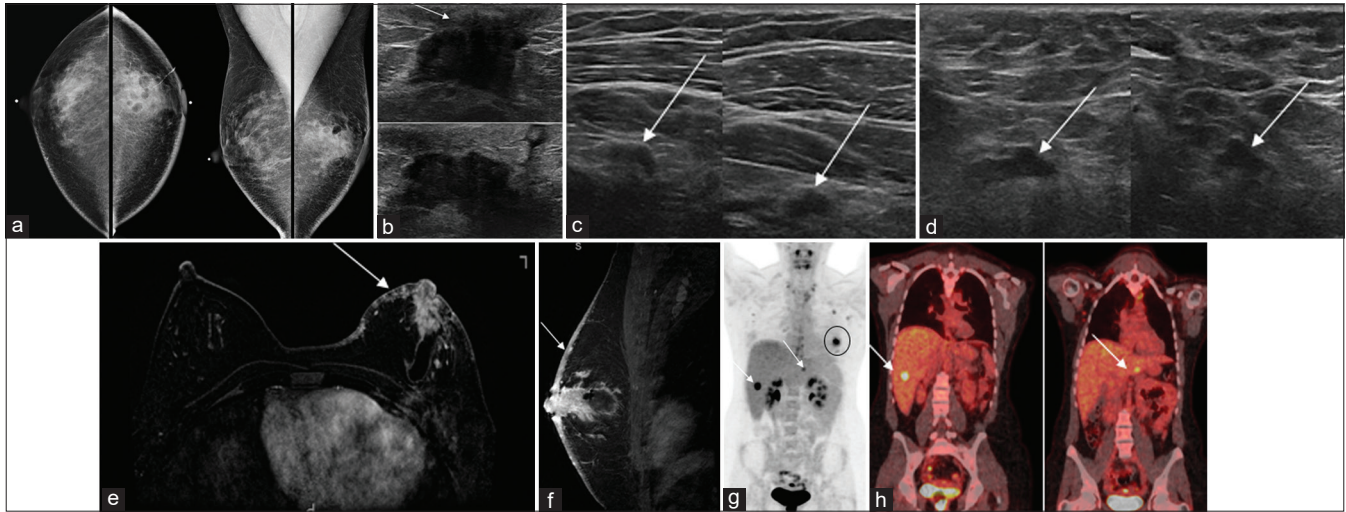


Figure 3: A 29-year-old woman 4 months postpartum noticed an inability to breast feed from the left breast. She later developed a palpable area in the left breast that did not resolve with warm compresses. One month later, she developed a rash and erythema that did not improve with antibiotics. Initial work-up was performed with surgical excisional biopsy with pathology yielding carcinoma. A referral to radiology and subsequent imaging workup was then performed, starting with a mammogram. (a) Craniocaudal (left) and mediolateral oblique (right) mammograms demonstrate post-excisional biopsy changes of the left breast, a focal asymmetry in the central region of the left breast, 3 cm from the nipple, associated global skin thickening (arrow) and trabecular thickening. (b) Longitudinal (top) and transverse (bottom) ultrasound images of the palpable area in the central region of the left breast demonstrate a hypochoic irregular mass, measuring $3.5 \times 2.5 \times 1.9$ cm, with extension to the nipple base (arrow). (c) Transverse (left) and longitudinal (right) ultrasound of the left regional nodal basin demonstrates multiple abnormal lymph nodes, including infraclavicular lymph nodes (arrows). (d) Transverse (left) and longitudinal (right) ultrasound of the right axilla demonstrated an abnormal lymph node with a cortical bulge (arrow). Ultrasound-guided core needle biopsy of the left breast mass revealed poorly differentiated invasive ductal carcinoma, which, in addition to the skin changes, was consistent with inflammatory breast cancer. Ultrasound-guided-fine-needle aspirations of abnormal lymph node in the left infraclavicular region and the right axillary region yielded metastatic carcinoma. (e) Axial T1-weighted contrast-enhanced MRI and (f) sagittal T1-weighted contrast enhanced MRI demonstrates an irregular heterogenous enhancing mass with an associated seroma that measures $4.1 \times 1.8 \times 2.2$ cm, in the central region of the left breast. There is direct extension of the malignancy to the nipple areolar complex. There is global skin thickening with heterogenous nodular enhancement of the dermis (arrow), consistent with dermal tumor emboli. These skin findings are key MRI features of inflammatory breast cancer. Coronal PET CT (g and h) demonstrate that in addition to the index left breast carcinoma (black circle) and bilateral lymphadenopathy, there were two liver masses which demonstrated increased FDG avidity (arrows). Ultrasound-guided core needle biopsy of the right liver mass demonstrated metastatic carcinoma.

mammography and ultrasound [Figure 4] results from the increase in parenchymal density due to hormonal influences, resulting in a decrease in mammographic sensitivity.^[6] The benefits of mammography are that microcalcifications are detected more easily compared to ultrasound, when associated calcifications are present, mammography can be helpful in the determination of the extent of disease including multicentric and multifocal disease.

BIOPSY TECHNIQUES AND POTENTIAL RISK OF BIOPSY IN A PREGNANT OR LACTATING WOMAN

Ultrasound-guided biopsy is the preferred method of tissue sampling due to the lack of ionizing radiation and

ease of the performance. However, stereotactic biopsy and mammography-guided wire localization are safe during pregnancy and can be performed. MRI-guided biopsy is not recommended in pregnancy due to the gadolinium-based contrast agent crossing the placenta and small quantities of gadolinium dissociating in the amniotic fluid and dissolving into toxic free gadolinium ions. However, MRI-guided biopsies are safe in lactating women. In addition to the usual risks of bleeding and infection, there is a small risk of milk fistula. This risk is mitigated by feeding or pumping immediately before the biopsy and resuming shortly after and also using a 14 g needle or smaller.

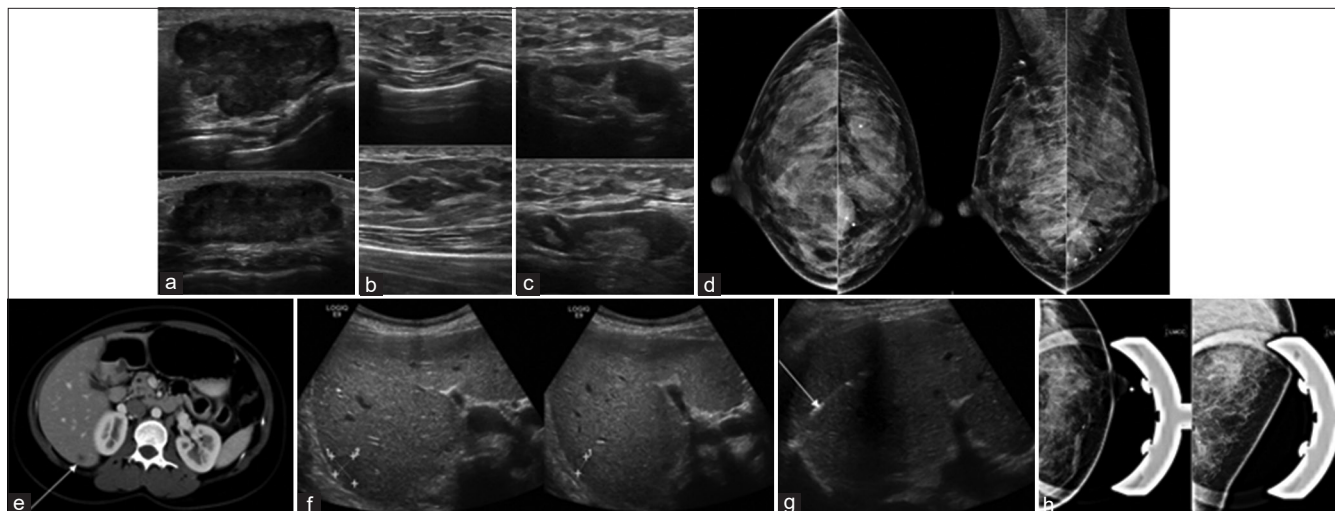


Figure 4: A 32-year-old woman, 9 weeks pregnant, presented for further evaluation of a left breast mass at the 6 o'clock position. Initial evaluation was performed with a breast ultrasound. (a) Longitudinal (top) and transverse (bottom) ultrasound of the palpable abnormality at the 6 o'clock position, 7 cm from the nipple, demonstrates an irregular hypoechoic $2.8 \times 1.6 \times 3.8$ cm mass (short arrow). (b) Longitudinal (top) and transverse (bottom) ultrasound of the left breast at the 9 o'clock position, 1 cm from the nipple, demonstrates irregular hypoechoic mass, measuring $0.7 \times 0.5 \times 0.8$ cm (long arrow). (c) Longitudinal (top) and transverse (bottom) ultrasound of the left axilla demonstrates an abnormal lymph node with increased cortical thickness (arrow). (d) Craniocaudal (right) and mediolateral oblique (left) images of the bilateral breasts demonstrate that the palpable abnormality in the left breast at the 6 o'clock position, 4 cm from the nipple, correlates with a round mass with indistinct margins (arrow). There was no mammographic correlate for the left breast mass at the 9 o'clock position. Ultrasound-guided core needle biopsy of the left breast mass at the 6 o'clock position revealed invasive ductal carcinoma. Ultrasound-guided core needle biopsy of the left breast mass at the 9 o'clock position revealed ductal carcinoma *in situ*. Ultrasound-guided fine-needle aspiration of the left axillary lymph node demonstrated metastatic carcinoma. (e) CT of the chest and the abdomen was performed for the evaluation of metastatic disease and demonstrates a 1.4 cm hypodense lesion in the right lobe of the liver (arrow) that was suspicious for metastasis. (f) Ultrasound of the abdomen demonstrated a 1.4 cm hypodense mass in the right lobe of the liver (calipers, short arrow). (g) Ultrasound-guided core needle biopsy (long arrow) of the liver mass demonstrated metastatic carcinoma. (h) The patient received five cycles of chemotherapy and delivered a healthy baby. Left breast craniocaudal (left) and lateral medial (right) magnification views were obtained after completion of chemotherapy and demonstrate interval development of pleomorphic calcifications (oval) in the inferior left breast and resolution of the previously visualized mass, consistent with tumor necrosis and response to chemotherapy.

CONCLUSION

PABC is a rare condition that is increasing in incidence possibly due to women choosing to delay childbearing in conjunction with an overall increase in breast cancer. There are many factors to consider when imaging pregnant and lactating patients, such as radiation exposure to the breast and the fetus in addition to the risks of performing biopsies. Early detection of breast cancer can decrease morbidity and mortality in this group of patients.

Declaration of patient consent

Patient's consent not required as patient's identity is not disclosed or compromised.

Financial support and sponsorship

Nil.

Conflicts of interest

There are no conflicts of interest.

REFERENCES

1. Ayyappa AP, Kulkarni S, Crystal P. Pregnancy associated breast cancer: Spectrum of imaging appearances. *Br J Radiol* 2010;83:529-34.
2. Ong A, Mullen L, Harvey S. Pregnancy associated breast cancer and other breast disease: A radiologic review. *Appl Radiol* 2020;49:10-7.
3. Chung EM, Cube R, Hall GJ, González C, Stocker JT, Glassman LM. From the archives of the AFIP: Breast masses in children and adolescents: Radiologic-pathologic correlation. *Radiographics* 2009;29:907-31.
4. Sabate, JM, Clotet M, Torrubia S, Gomez A, Guerrero R, de las Heras P, et al. Radiologic evaluation of breast disorders related to pregnancy and lactation. *Radiographics* 2007;27 Suppl 1:S101-24.

5. Sumkin JH, Perron AM, Harris KM, Nath ME, Amortegui AJ, Weinstein BJ. Lactating adenoma: US features and literature review. *Radiology* 1998;206:271-4.
6. Yang WT, Dryden MJ, Gwyn K, Whitman GJ, Theriault R. Imaging of breast cancer diagnosed and treated with chemotherapy during pregnancy. *Radiology* 2006;239:52-9.

How to cite this article: Perez F, Bragg A, Whitman G. Pregnancy associated breast cancer. *J Clin Imaging Sci* 2021;11:49.