




## Dental Radiology Case Report

# Ten-year developmental-evolution of a solitary osteoma of the mandibular ramus: Report of a case and short review

Ioannis Tilaveridis<sup>1</sup>, Panagiotis Karakostas<sup>2</sup>, Vasilios Tilaveridis<sup>1</sup>, Stavros Tilaveridis<sup>1</sup>

<sup>1</sup>Department of Oral and Maxillofacial Surgery, School of Dentistry, Aristotle University of Thessaloniki, <sup>2</sup>Department of Preventive Dentistry, Periodontology and Implant Biology, School of Dentistry, Aristotle University of Thessaloniki, Thessaloniki, Greece.



### \*Corresponding author:

Panagiotis Karakostas,  
Department of Preventive  
Dentistry, Periodontology and  
Implant Biology, School of  
Dentistry, Aristotle University  
of Thessaloniki, Thessaloniki,  
Greece.

[karako.dent@gmail.com](mailto:karako.dent@gmail.com)

Received : 10 July 2022

Accepted : 25 July 2022

Published : 10 August 2022

### DOI

10.25259/JCIS\_78\_2022

### Quick Response Code:



## ABSTRACT

Osteomas of the maxilla and the mandible are rare, benign, and slow-growing tumors arising from the bone cells. They are more frequently located on the mandible than the maxilla, with mandibular body, angle, and condyle being more frequently affected. The development of a peripheral osteoma at the mandibular ramus is a rare occurrence, and few cases have been published in English literature. Even though the developmental process of this pathologic entity is characterized as slow growing, little data are known about the developmental rate of the peripheral osteomas of the mandible. In our paper, we present a case of peripheral osteoma of the external surface of the right mandibular ramus that was diagnosed 10 years earlier; its dimensions were measured precisely at that time with CT. The patient declined a surgical operation, and 10 years after the initial diagnosis, she visited our department with an increase in the size of the lesion and asked for a re-evaluation. A new CBCT was performed, and accurate measurement of the new dimensions of the lesion was conducted; this was compared with the previous dimensions. The comparison of the current CBCT with the CT performed 10 years earlier permitted to calculate the growth rate of osteoma that was approximately 2.0 mm/year.

**Keywords:** Osteoma, Mandibular ramus, Growth rate

## INTRODUCTION

True benign bone tumors may arise from the jaw bones, and they are classified as osteomas, myxomas, chondromas, fibro-osteomas, and central giant cell tumors. Peripheral osteomas of the jaws are well-circumscribed, bony tumors that develop at the external surfaces of the mandible or the maxilla. They consist of dense, compact bone, or cancellous bone, and they are characterized by a slow-growing rate the above time frame.<sup>[1,2]</sup> The torus palatinus and tori mandibularis are – occasionally – seen, as are osteomas of the paranasal sinuses, with those exceptions peripheral osteomas of the jaws are rare entities.<sup>[1]</sup> They present as compact, painless swelling that remains stable for long time, growing slowly. Most peripheral osteomas are encountered more often on the mandible, especially at the mandibular body, than the maxilla.<sup>[3]</sup>

In our paper, we illustrate an unusual case of osteoma of the ramus that was diagnosed 10 years earlier as a mild, external preauricular swelling. After this long period of time, the patient came for a new evaluation. The CBCT permitted the measuring of the new dimensions of the lesion that was 38.1 × 40.2 × 21.6 mm. The comparison of the new dimensions with the initial ones

This is an open-access article distributed under the terms of the Creative Commons Attribution-Non Commercial-Share Alike 4.0 License, which allows others to remix, transform, and build upon the work non-commercially, as long as the author is credited and the new creations are licensed under the identical terms.

©2022 Published by Scientific Scholar on behalf of Journal of Clinical Imaging Science

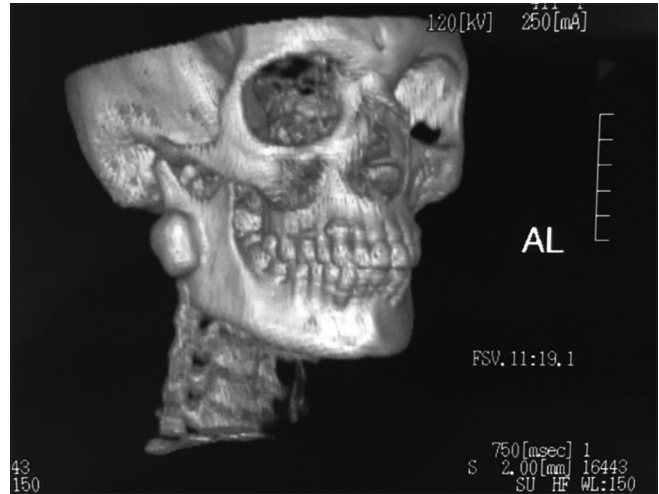
permeated the calculation of the growth rate of osteoma per year.

## CASE REPORT

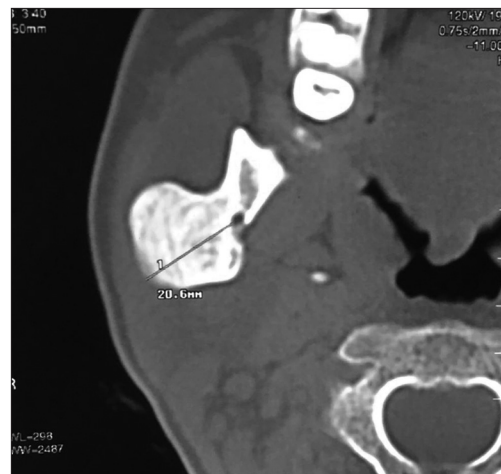
A 47-year-old woman on November of 2010 was referred by her dentist to a maxillofacial surgeon for the evaluation of a swelling at the right mandibular ramus. The swelling was hard in constancy, mild in size, and located at the right preauricular area. According to history and clinical examination, the provisional diagnosis of an osteoma was considered. A CT examination, CT was preferred to plain X-rays as it provides the accurate dimensions of the lesion in all three dimension. CT imaging disclosed a radiopaque lesion at the external surface of the right mandibular ramus measuring of  $22.5 \times 20.6 \times 12.3$  mm. Hounsfield Units (HUs) of the swelling were identical with ones of the mandibular ramus ranging from 1490 to 1590 HU. The suspicion of a peripheral osteoma was established and confirmed with intraoral biopsy of the lesion that established the diagnosis of a peripheral osteoma [Figures 1 and 2].

The patient had informed by the maxillofacial surgeon that according to the results of biopsy, the lesion was a benign tumor and for the risks if the lesion left untreated. However, the patient declined the proposed surgical operation. On October of 2019, the patient visited the oral and maxillofacial surgery department with a painless preauricular swelling, complaining that the swelling had progressively increased in size. Clinical evaluation of the affected area revealed a painless, compact mass with well-circumscribed margins, attached to the underlying external surface of the right mandibular ramus, and moved with mandibular movements. The above-mentioned characteristics excluded the origin of the swelling from the parotid gland. Clinical evaluation of the temporomandibular joint was normal, and there was no deviation of the mandible during opening of the mouth. According to the patient, the swelling had progressively increased in size over the years, causing an asymmetry of the lower one-third of the face but remained painless [Figure 3].

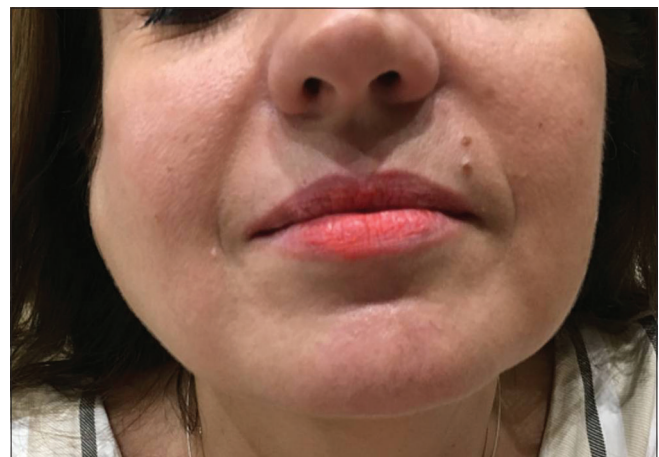The history was non-contributory, and the patient had not undergone any kind of operation on the affected side or experienced any trauma in this area. An imaging evaluation with CBCT was requested, to evaluate the dimensions of the lesion which revealed a large swelling consisting of dense bone [Figure 4] measuring of  $38.1 \times 40.2 \times 21.6$  mm in its greatest dimensions. The absence of alterations in clinical behavior of the lesion except for the size along with radiologic findings did not raise the suspicion that the initial diagnosis of osteoma has changed. A surgical operation through an intraoral approach to remove the tumor was proposed to the patient, but she declined again, as she covered the swelling of her face by modification of hair dressing.



**Figure 1:** 3D reconstruction of CT with the initial appearance of osteoma.



**Figure 2:** A section of the CT with the exact dimensions of the osteoma at the initial presentation.



**Figure 3:** Preauricular swelling of the right side of the patient's face.

## DISCUSSION

The etiology of peripheral osteomas is not clear, and neoplastic, traumatic, or developmental theories have been proposed.<sup>[4]</sup> Considering that a large percentage of peripheral osteomas encountered on the mandible – a bone prone to trauma – the traumatic theory may be more acceptable. In our patient, there was no history of previous trauma or an operation at the site of tumor development.<sup>[5-7]</sup>

Peripheral osteomas are painless, tough swellings that develop beyond the jaw borders and consist of lamellar or compact bone. Sometimes, they have a broad base on the jaws, but otherwise they arise from a relatively narrow base and have a mushroom-like appearance.<sup>[7]</sup>

Computerized tomography or cone-beam CT is the imaging of choice, as it reveals the exact location, the dimensions, and the nature of bone lesions as in contrast to orthopantomogram, it represents the lesion in three dimensions and not in two.<sup>[8]</sup> The confirmed diagnosis of osteoma at 2010 with biopsy along with its clinical course and imaging appearance 10 years later was adequate for reaffirmation of initial diagnosis.

The mandible is more frequently affected than the maxilla, and peripheral osteomas more frequently are encountered on the mandibular body, the angle of the mandible, and the condyle; they rarely appear on the ramus or the coronoid process.<sup>[4,9]</sup>

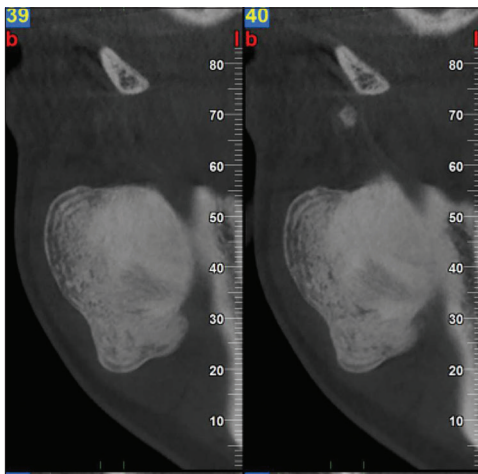
Anatomically, osteomas of the mandibular ramus are located at its external or internal surface and along its posterior surface or ascending ramus.<sup>[10]</sup> The function of the mandible is rarely affected, as the development of tumors at this site causes esthetic rather than functional disturbances, unless the tumor extending to the temporomandibular joint creates functional disturbances.<sup>[8]</sup> In our case, the development

of osteoma occurred at the external surface of the right mandibular ramus, and it was painless. The only complaint from the patient was the facial disfigurement rather than functional problems. However, the locations of the swelling at the posterior part of the lower face and the possibility of camouflage with hair dressing were important factors in the patient's refusal of the surgical operation to remove the tumor.

A literature review disclosed 112 cases of peripheral mandibular osteomas, located at different parts of the mandible. Analysis of these cases revealed that 28 cases were located at the ramus, and from these, only six peripheral osteomas, including our case, were located at the external mandibular surface [Table 1].<sup>[7,10]</sup>

Our case is unique, as we had the opportunity to follow with accuracy the developmental evolution of a solitary peripheral osteoma over an extended time frame, as at the initial diagnosis of osteoma, a CT was available; we knew with accuracy the dimensions of the lesion at the first presentation, and we compared these dimensions with the current dimensions measured with CBCT. Calculating the increase in size of osteoma in a 10-year follow-up, we found that the annual increase in dimensions was approximately 1.75 mm/year. A similar study described by Maglittero *et al.*<sup>[11]</sup> indicates the annual development of a peripheral osteoma located at the mandibular notch, and they found a developmental increase of 1.1 mm/year. However, the measurements in the study Maglittero *et al.* (2021) were based solely on orthopantomograms rather than on CTs or CBCTs, except for the most recent imaging in which a CT was utilized. Although orthopantomogram is a valuable examination, it estimates only the two dimensions instead of CT or CBCT that can define with accuracy the third dimensions of a lesion.<sup>[8]</sup> However, the measurements, in our study, revealed a slightly greater increase in size per year compared to the case of Maglittero *et al.* (2021). We cannot assess whether this difference was related to the anatomic position of the osteoma, but the very slow increase in size indicates the benign nature of the lesion.

Treatment of peripheral osteomas of the jaws is the surgical removal that in most of the cases performed through intraoral procedure. Intraoral procedure is recommended to avoid any



**Figure 4:** A section of the new CT performed 10 years after the initial diagnosis of osteoma, featuring the important increase of the lesion.

**Table 1:** The distribution of 28 peripheral osteomas along the mandibular ramus.

Location at the ramus	Number of cases
Anterior ramus	8
Posterior ramus	2
External surface	6
Medial surface	2
Sigmoid notch	4
Coronoid process	6

noticeable scar to the face and to avoid damage to the marginal branch of the facial nerve. Peripheral osteomas located at the external surface of the mandibular ramus can be removed either with intraoral or extraoral approach depending on the surgeon's preferences and his surgical experience. Surgical treatment of peripheral osteomas located at the condylar head performed exclusively extraorally through a preauricular approach and includes removal of osteoma only or removal of osteoma with condylar head and subsequent reconstruction.<sup>[5,7,10]</sup>

Peripheral osteomas of the jaws irrespectively of the location site may gradually increase in size with a slow growth rate. However, the slow growth rate is should not considered a crucial factor to defer the surgical operation as any delay may contribute to the gradual increase of the size of osteoma. The increased size of an osteoma may be associated with symptoms or additional post-operative complications.

## CONCLUSION

Osteoma is a benign osteogenic tumor that may arise from facial bones. The body of the mandible and mandibular condyle is the most frequently affected sites while the external surface of the ramus is rarely affected. The article presents the case of a peripheral osteoma of the mandibular ramus which was diagnosed 10-year earlier and remained untreated. The comparison of the CT performed at the time of initial diagnosis along with CBCT performed 10 years later, which permitted us to estimate with precision the growth rate that was approximately 1.75 mm/year. Surgical excision of the lesion was recommended to avoid future difficulties during the operation and to minimize post-operative complications.

## Declaration of patient consent

Patient's consent not required as patient's identity is not disclosed or compromised.

## Financial support and sponsorship

Nil.

## Conflicts of interest

There are no conflicts of interest.

## REFERENCES

1. Pendlar J, Frame J. Oral and Maxillofacial Surgery: An Objective-based Textbook. London: Churchill Livingstone, Elsevier Limited; 2007.
2. Neville B, Damm D, Allen C, Bouquot J. Oral and Maxillofacial Pathology. Philadelphia, Pennsylvania: WB Saunders Company; 2002.
3. Manjunatha BS, Das N, Sutariya R, Ahmed T. Peripheral osteoma of the body of mandible. *BMJ Case Rep* 2013;2013:bcr2013009857.
4. Sayan NB, Ucok C, Karasu HA, Gunhan O. Peripheral osteoma of the oral and maxillofacial region: A study of 35 new cases. *J Oral Maxillofac Surg* 2002;60:1299-301.
5. Schneider LC, Dolinsky HB, Grondjesk JE. Solitary peripheral osteoma of the jaws: Report of case and review literature. *J Oral Surg* 1980;38:452-5.
6. Kaplan I, Calderon S, Buchner A. Peripheral osteoma of the mandible: A study of 10 new cases and analysis of the literature. *J Oral Maxillofac Surg* 1994;52:467-70.
7. Johann AC, De Freitas JB, De Aguiar MC, De Araujo NS, Mesquita RA. Peripheral osteoma of the mandible: Case report and review of the literature. *J Craniomaxillofac Surg* 2005;33:276-81.
8. Weiss R 2<sup>nd</sup>, Read-Fuller A. Cone beam computed tomography in oral and maxillofacial surgery: An evidence-based review. *Dent J (Basel)* 2019;7:52.
9. Dalabiras S, Boutsioukis C, Tilaveridis I. Peripheral osteoma of the maxilla: Report of an unusual case. *Oral Surg Oral Med Oral Pathol Oral Radiol* 2005;100:19-24.
10. Osawa K, Iwai T, Sugiyama S, Kitajima H, Baba J, Oguri S, *et al.* Peripheral osteoma arising from the lateral surface of the mandibular ramus. *J Oral Maxillofac Surg Med Pathol* 2018;30:278-80.
11. Maglito A, Mariani SA, de Pater E, Rodriguez-Seoane C, Vink CS, Piao X, *et al.* Unexpected redundancy of Gpr56 and Gpr97 during hematopoietic cell development and differentiation. *Blood Adv* 2021;5:829-42.

**How to cite this article:** Tilaveridis I, Karakostas P, Tilaveridis V, Tilaveridis S. Ten-year developmental-evolution of a solitary osteoma of the mandibular ramus: Report of a case and short review. *J Clin Imaging Sci* 2022;12:47.