

DENTAL ARTICLE

Osteonecrosis Secondary to Paget's Disease: Radiologic and Pathologic Features

Naveen Polisetti², Mahesh Neerupakam, Venkata Sarath Prathi¹, Jacob Prakash³,
D. Vaishnavi², Swapna Sridevi Beeraka¹, Deepthi Bhavirisetty¹

Departments of Oral Medicine and Radiology, ²Oral and Maxillofacial Surgery, ³Oral Pathology, KLR'S Lenora Institute of Dental Sciences, Rajanagaram, Rajahmundry, ¹Oral Medicine and Radiology, Narayana Dental College, Nellore, Andhra Pradesh, India

Address for correspondence:

Dr. Venkata Sarath Prathi,
Department of Oral Medicine and
Radiology, Narayana Dental College
and Hospital, Chinthareddypalem,
Nellore, Andhra Pradesh, India.
E-mail: sarathprathi@gmail.com.



Received : 08-11-2013

Accepted : 07-01-2014

Published : 21-03-2014

ABSTRACT

Paget's disease (PD) is a chronic progressive disease of the bone characterized by abnormal bone metabolism affecting either a single bone (monostotic) or many bones (polyostotic) with uncertain etiology. We report a case of PD in a 70-year-old male, which was initially identified as osteonecrosis of the maxilla. Non-drug induced osteonecrosis in PD is rare and very few cases have been reported in the literature.

Key words: Bone disease, bone metabolism paget's disease, osteonecrosis, osteitis deformans

INTRODUCTION

Paget's disease (PD) of the bone was first described, in 1877, by Sir James Paget under the term "osteitis deformans".^[1] It is characterized by rapid bone resorption and deposition, resulting in formation of numerous reversal lines, which give rise to a mosaic pattern in the lamellar bone with profuse local vascularity and fibrous tissue in the marrow.^[2] In the initial phase of PD, there is excessive bone resorption followed by increased deposition. However, both may occur simultaneously, resulting in

osteoporosis and sclerotic bone. Within the sclerotic bone there is reduced vascularity (localized vascularity) and the ability for normal healing is compromised, hence it can lead to osteonecrosis.^[3] Therapeutic agents for PD include bisphosphonates like alendronate, risedronate, and zoledronic acid.^[4]

A 70-year-old male patient presented with a 3-month history of perforation in the left maxillary region with drainage of oral fluids from the nasal cavity. The patient had difficulty in swallowing and speech was altered. Past medical history revealed sudden weight loss, intermittent headaches, and partial deafness. Patient also revealed no history of malignancy and previous treatment. Extra-oral examination showed localized hyperthermia with enlarged cranium, zygoma, and incompetent lips [Figure 1]. A single left submandibular lymphnode of inflammatory nature was palpable. Intraoral examination showed enlarged maxilla, fistulous tract connecting posterior maxilla and maxillary

Access this article online**Quick Response Code:****Website:**

www.clinicalimaging-science.org

DOI:

10.4103/2156-7514.129262

Copyright: © 2014 Neerupakam M. This is an open-access article distributed under the terms of the Creative Commons Attribution License, which permits unrestricted use, distribution, and reproduction in any medium, provided the original author and source are credited.

This article may be cited as:

Polisetti N, Neerupakam M, Prathi VS, Prakash J, Vaishnavi D, Beeraka SS, Bhavirisetty D. Osteonecrosis Secondary to Paget's disease: Radiologic and Pathologic Features. J Clin Imaging Sci 2014;4:S1. Available FREE in open access from: <http://www.clinicalimaging-science.org/text.asp?2014/4/1/1/129262>

sinus, and ill-fitting temporary partial denture in relation to left maxillary molars [Figure 2].

RADIOLOGIC FEATURES

PD of the bone is diagnosed primarily by radiographic examination. Early in the course of the disease, lytic activity predominates causing focal osteolytic lesions. Subsequently, areas of sclerosis develop leading to the characteristic appearance of mixed lytic and sclerotic areas, thickened trabeculae, bone expansion, cortical thickening, and deformity.

Panoramic radiograph showed generalized tooth displacement with hypercementosis. Generalized mixed radiolucent and radiopaque areas were seen in the maxilla and mandible with characteristic cotton-wool appearance in the left maxilla [Figure 3]. Paranasal sinus view revealed generalized increase in the fuzziness of all the facial bones with mixed radiolucencies in the frontal bones and marked haziness in the maxillary sinuses. Lateral skull view showed

generalized mixed radiolucent and radiopaque areas suggestive of Pagetic calvaria [Figure 4].

PATHOLOGIC FEATURES

Bone biopsy was taken from 26 regions. Histopathology of the lesion showed increased osteoblastic activity and hematoxyphilic reversal lines giving an appearance of the characteristic Pagetoid bone. Marrow spaces were filled with fibrous connective tissue, confirming osteitis deformans [Figure 5]. Biochemical analysis showed abnormal increase (740 U/l) in serum alkaline phosphatase enzyme level (Normal range is 40-125 U/L)^[5] and urinary hydroxylproline (88 mg/day/m²).

On correlating the clinical, radiographic, histopathological, and biochemical findings, it was finally diagnosed as a case of PD involving the maxilla and skull. An obturator was

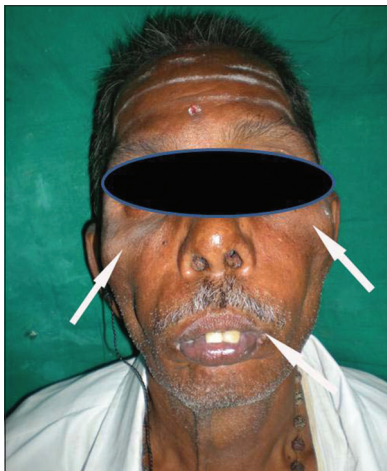

Figure 1: 70-year-old male with perforation in the left maxillary region diagnosed with Paget's disease. Extra-oral clinical photograph shows enlarged cranium, zygoma, and incompetent lips (arrows).

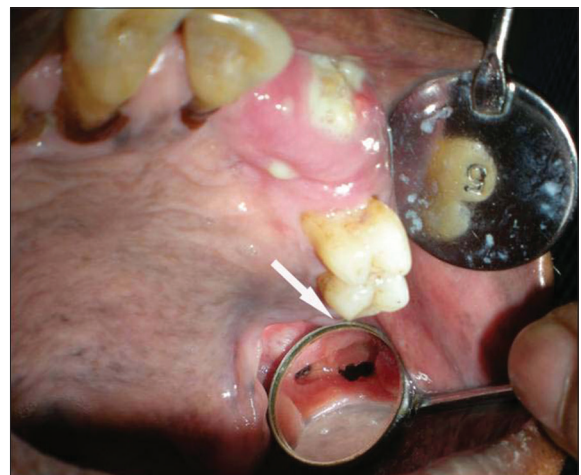

Figure 2: 70-year-old male with perforation in the left maxillary region diagnosed with Paget's disease. Intraoral clinical photograph shows a fistulous tract (arrow).

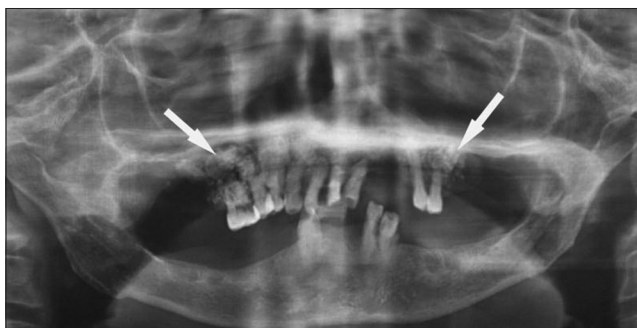

Figure 3: 70-year-old male with perforation in the left maxillary region diagnosed with Paget's disease. Panoramic radiograph shows generalized mixed radiolucent and radiopaque areas in the maxilla and mandible (arrows) with characteristic cotton wool appearance in the left maxilla.

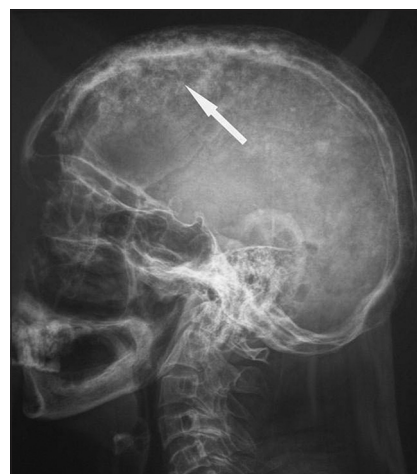

Figure 4: 70-year-old male with perforation in the left maxillary region diagnosed with Paget's disease. Lateral skull view shows generalized mixed radiolucent and radiopaque areas (arrows) suggestive of Pagetic calvaria.

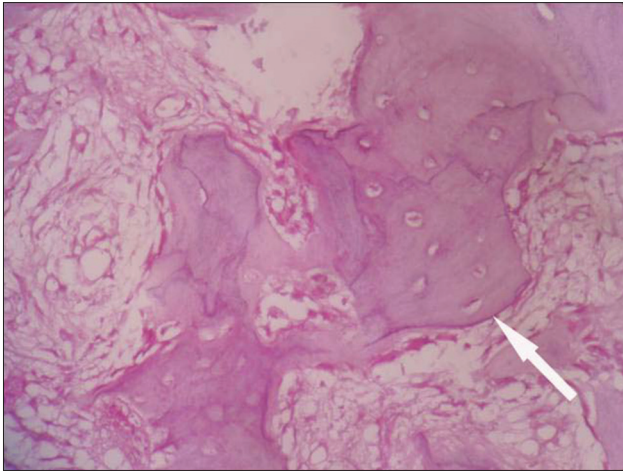


Figure 5: 70-year-old male with perforation in the left maxillary region diagnosed with Paget's disease. Hematoxylin and eosin stained biopsy tissue ($\times 100$) shows immature bone either with osteoid and osteoblastic rimming, reversal lines, and enough fibrovascular stroma (arrow).

placed in the left maxillary ridge to prevent draining of oral fluids into the nasal cavity [Figure 6].

DISCUSSION

PD is a relatively common disease in Western countries; it is very rarely encountered in the Indian population. It occurs mostly in the fifth to sixth decade of life, with a high preponderance in the male population.^[6] The etiology of PD is still not totally clear, but genetic and environmental factors may play a role. PD may affect the jaw bones, cementum of the teeth and pulp tissue, which lack cellular structure with manifestation of interglobular dentine. In our case altered size and shape of the maxilla, osteonecrosis that resulted in a fistulous tract, radiographically hypercementosis, displacement of the teeth, and cotton-wool appearance in both the jaws were evident. Biochemical analysis revealed abnormal increase in bone turnover.

Non-healing extraction sites and exposed alveolar bone following the removal of maxillary teeth in a patient with advanced PD has been reported.^[7] A case of chronic osteomyelitis involving the maxilla following dental extractions in a Pagetoid patient has been documented.^[8] Osteonecrosis of the jaws associated with actinomyces infection have been reported.^[9] A total of 63 cases of bisphosphonate-induced osteonecrosis of the jaws were reported; majority of the cases affected the maxilla.^[10] In the clinical scenario, the question posed is whether osteonecrosis in postoperative sites occurs as a result of PD, bisphosphonate therapy, or a combination of the two. In both, the pathogenesis is vascular insufficiency. But, in our case there was no evidence of any non-healing socket and the patient had not used any medication to treat PD.

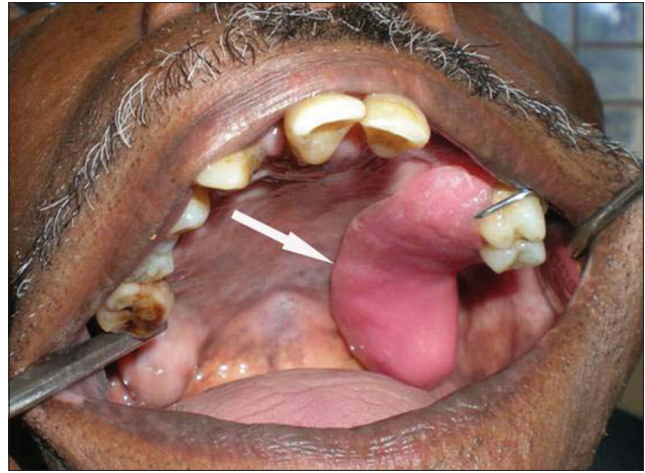


Figure 6: 70-year-old male with perforation in the left maxillary region diagnosed with Paget's disease. Intraoral clinical photograph shows an obturator (arrow) placed in the left maxillary molar region.

The patient was referred to a physician for treatment of PD, who prescribed Alendronate 40 mg/day for 6 months.

CONCLUSION

Drug induced osteonecrosis in Paget's disease is common. In the present case, osteonecrosis secondary to Paget's disease (non-drug induced) seen in a 70-year-old male patient shows characteristic radiographic and pathologic features of Paget's disease.

REFERENCES

1. Paget J. On a form of chronic inflammation of bones (Osteitis deformans). *Med Chir Trans* 1877;60:37-64.
2. Kanis JA, editor. *Pathophysiology and treatment of Paget's diseases of bone*. 2nd ed. London: Martin Dunitz; 1998.
3. Seehra J, Sloan P, Oliver RJ. Paget's disease of bone and Osteonecrosis. *Dent Update* 2009;36:166-72.
4. Silverman SL. Paget disease of bone: Therapeutic options. *J Clin Rheumatol* 2008;14:299-305.
5. McKiernan FE, Shrestha LK, Berg RL, Fuehrer J. Acute hypophosphatasemia. *Osteoporos Int* 2014;25:519-23.
6. Joshi SR, Ambhore S, Butala N, Patwardhan M, Kulkarni M, Pai B, et al. Paget's disease from western India. *J Assoc Physicians India* 2006;54:535-8.
7. Ripp GA. A complication after extractions in a patient with advanced Paget's disease. *Oral Surg Oral Med Oral Pathol* 1972;33:35-40.
8. Feig HI, Edmunds WR, Beaubien R, Finkelman AA. Chronic osteomyelitis of the maxilla secondary to Paget's disease. A complication following dental extraction. Report of case. *Oral Surg Oral Med Oral Pathol* 1969;28:320-5.
9. Hansen T, Kunkel M, Weber A, Kirkpatrick J. Osteonecrosis of the jaws in patients treated with bisphosphonates – histomorphologic analysis in comparison with infected Osteoradionecrosis. *J Oral Pathol Med* 2006;35:155-60.
10. Ruggiero SL, Mehrotra B, Rosenberg TJ, Engroff SL. Osteonecrosis of the Jaws associated with the use of bisphosphonates: A review of 63 cases. *J Oral Maxillofac Surg* 2004;62:527-34.

Source of Support: Nil, **Conflict of Interest:** None declared.