

DENTAL ARTICLE

Intramedullary Osteosarcoma of the Mandible: A Clinikoradiologic Perspective

Bhogisetty Chittaranjan, ML Avinash Tejasvi¹, Bangi Balaji Babu¹, Paramkusam Geetha¹

Departments of Prosthodontics and ¹Oral Medicine and Radiology, Kamineni Institute of Dental Sciences, Narketpally, Nalgonda District, Telangana, India

Address for correspondence:

Dr. ML Avinash Tejasvi,
Department of Oral Medicine and
Maxillofacial Radiology, Kamineni Institute
of Dental Sciences, Narketpally, Nalgonda
District, Telangana - 508 254., India.
E-mail: avinash_tejaswi@yahoo.co.in



Received : 08-11-2013

Accepted : 12-12-2014

Published : 31-12-2014

ABSTRACT

Osteosarcoma is a non-hematopoietic primary malignant tumor of bone or mesenchymal tissue. Although osteosarcoma is not a common malignant bone tumor, accounting for approximately 20% of sarcomas, tumor of the jaw bone is uncommon, representing only about 4% of osteosarcomas of long bones. We report a case of a 72-year-old female with a swelling on the left side of the mandible and intra-oral swelling on the floor of the mouth. Conventional radiograph and advanced imaging modalities such as computed tomography and magnetic resonance imaging revealed an intramedullary osteosarcoma of the mandible. This report highlights importance of imaging modalities in the diagnosis of malignant tumors of the jaws.

Key words: Magnetic resonance imaging, mandible, osteosarcoma, tomography, X-ray computed

INTRODUCTION

Osteosarcoma is an uncommon primary malignant tumor of bone and consists of a group of comparatively rare primary malignant neoplasms of bone which exhibit considerable variation not only in the clinical and histological appearance but also in the course and prognosis of the disease.^[1] However, osteosarcoma is uncommon in the jaw bones, comprising only 6–9% of all cases of osteosarcomas. Garrington et al., reported that osteosarcoma of the jaw represents 1% of osteosarcomas of the body and affects 50,000 people worldwide each

year.^[2] Dentists are usually the first to detect this tumor in the jaw during their diagnostic workup irrespective of the biological behavior of the tumor. Since osteosarcoma of the jaw is usually asymptomatic, early diagnosis of the lesion is very essential. This report describes the clinical, radiological, and imaging characteristics of the tumor. In-depth knowledge of the radiological features can lead to an early diagnosis. Early diagnosis and complete resection of the tumor are the most important factors that improve the prognosis of osteosarcoma.

A 72-year-old female patient presented with a 6-month history of intermittent pain and a large swelling on the left mandibular molar region, which gradually increased in size. On intra-oral examination an exophytic growth was seen on the left alveolar region, extending into the floor of the mouth along with an extra-oral swelling. Previous history of trauma was present; mild paresthesia of the lower lip and truisms were also noted. The patient had consulted a dental practitioner 2 months earlier

Access this article online

Quick Response Code:



Website:

www.clinicalimagingscience.org

DOI:

10.4103/2156-7514.148273

Copyright: © 2014 Chittaranjan B. This is an open-access article distributed under the terms of the Creative Commons Attribution License, which permits unrestricted use, distribution, and reproduction in any medium, provided the original author and source are credited.

This article may be cited as:

Chittaranjan B, Tejasvi MA, Babu BB, Geetha P. Intramedullary Osteosarcoma of the Mandible: A Clinikoradiologic Perspective. J Clin Imaging Sci 2014;4:6.

Available FREE in open access from: <http://www.clinicalimagingscience.org/text.asp?2014/4/2/6/148273>

and was advised to take antibiotics and analgesics. However, she had no permanent relief. Medical history was noncontributory.

On examination, a single diffuse extra-oral non-mobile swelling, about 5 × 4 cm in diameter, was seen in the left mandibular molar region. The swelling extended beyond the lower border of the mandible, with overlying skin that appeared stretched. On palpation, the swelling was tender and bony hard in consistency. Intra-orally, a diffuse exophytic growth was seen arising from the alveolar area and extending into the floor of the mouth. The teeth on the left side appeared to be floating inside the exophytic growth without any bone support. There was no pulsation on palpation. All these features gave a clinical impression of a neoplastic swelling. Following the clinical evaluation, a set of investigations were carried out. Hematological and biochemical laboratory tests were done. Hemoglobin levels were found to be reduced and alkaline phosphatase level was elevated 152 units/L (normal range of serum alkaline phosphatase is 30 units/L-120 units/L).

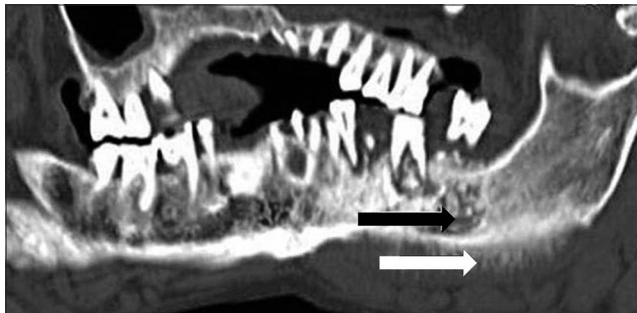


Figure 1: 72-year-old female with swelling on the right side of her mandible diagnosed as osteosarcoma of the mandible. Multidetector computed tomography (MDCT) panoramic view shows mixed radiolucent-radiopaque or hyperdense area (black arrow) with erosion of the inferior cortex (white arrow) indicating periosteal reaction.

RADIOLOGIC FEATURES

Panoramic reformatted CT image of the jaw showed a mixed radiolucent-radiopaque lesion in the left mandibular molar region, showing irregular margins indicating severe bone loss [Figure 1]. The teeth appeared to be floating in the lytic area with malignant bone beneath. Inferior cortex was eroded and hyperdense area was seen which was suggestive of periosteal reaction from the inferior cortex resembling benign reactive response. Mandibular canal had deviated from the normal and was found following a different direction. The axial view of the multidetector computed tomography (MDCT) [Figure 2] revealed an expansile mass with apparent bone destruction of the cortex and radial spicules were seen with periosteal reaction on the left side of the mandible, which gave the appearance of a typical sunray spiculation. Coronal section and paraxial views of MDCT scan [Figures 3 and 4, respectively] revealed an expansile mass with widening of the periodontal ligament space (Garrington's sign) and apparent bone destruction of the cortex, These views

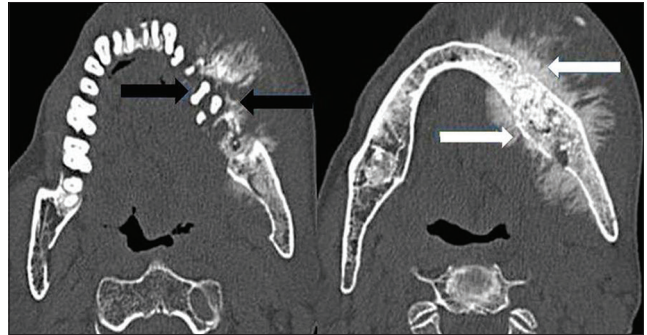


Figure 2: 72-year-old female with swelling on the right side of her mandible diagnosed as osteosarcoma of the mandible. MDCT images axial section show bone destruction of the cortex (black arrows) and apparent radial spicules similar to "sunrays," (white arrows) suggestive of periosteal reaction.

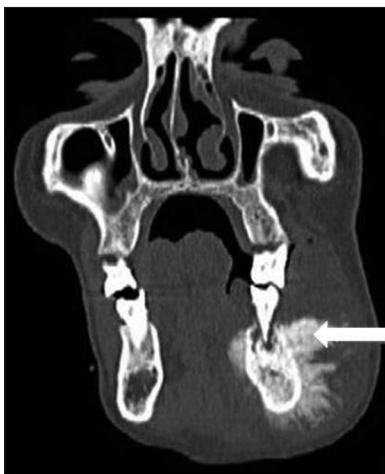

Figure 3: 72-year-old female with swelling on the right side of her mandible diagnosed as carcinoma of the mandible. MDCT image coronal section shows an expansile hyperdense mass with radial spicules resembling "sunrays" (arrow).

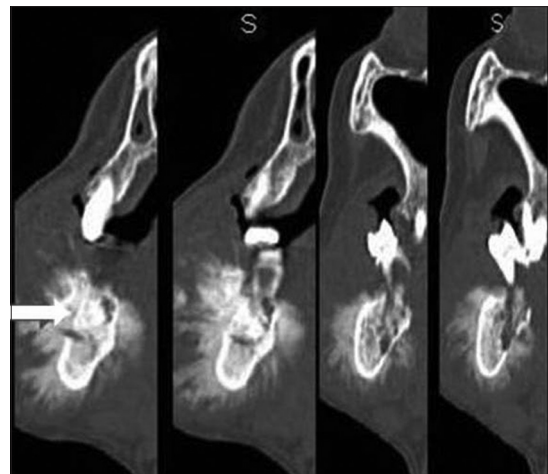


Figure 4: 72-year-old female with swelling on the right side of her mandible diagnosed as carcinoma of the mandible. MDCT image paraxial sections show an expansile hyperdense lesion with radial spicules resembling "sunrays" (arrow).

also showed radial spicules with periosteal reaction on the left side of the mandible. Three-dimensional CT reconstruction showed a buccal and lingual expansile lesion with periosteal reaction in the left hemiface [Figure 5]. Magnetic resonance imaging (MRI) was done in which T1 and T2 coronal and axial images [Figures 6 and 7] and T2 coronal views [Figure 8] revealed a mixed intensity lesion involving the left hemimandible showing hyper- and hypointense areas with destruction of the mandible and transcortical extension, indicating the neoplastic nature of the mass. Its plane with medial pterygoid was indistinct; however, its plane with the tongue appeared well defined. A radiographic diagnosis of intramedullary osteosarcoma was made. Other differential diagnosis considered were central squamous cell carcinoma and osteomyelitis. Squamous cell carcinoma leads to poorly defined lytic areas deep in the bone, rarely producing corticated margins. In osteomyelitis a moth-eaten appearance with sunray features are seen. The patient was advised an incisional biopsy.

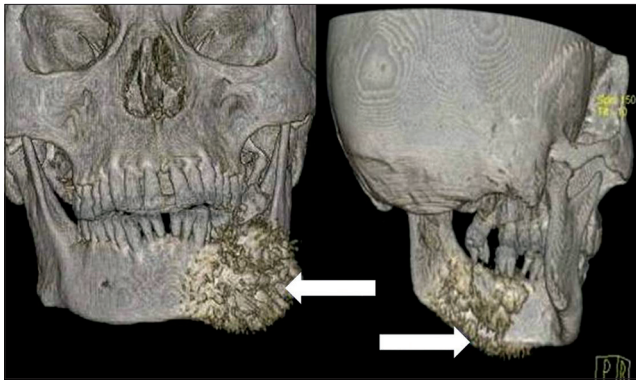


Figure 5: 72-year-old female with swelling on the right side of her mandible diagnosed as carcinoma of the mandible. Three-dimensional CT images show a buccal and lingual expansile lesion (arrow) with periosteal reaction.

PATHOLOGIC FEATURES

An incisional biopsy of the lesion was then performed under local anesthesia and was subjected to histopathologic analysis. Stained biopsy sample [Figures 9 and 10, respectively] showed atypical osteoblasts with new tumor osteoid and bone formation in an irregular pattern, which confirmed the radiographic suspicion of osteosarcoma. Similar histopathologic features can be seen in fibrous dysplasia lesion. Clinical and radiological assessment is necessary to arrive at the correct diagnosis. The patient was referred to a higher center for further treatment, where palliative chemotherapy was planned and treatment was started. Unfortunately, the patient died 4 months after the diagnosis of osteosarcoma was made.

DISCUSSION

Osteosarcoma accounts for 15–35% of all primary bone

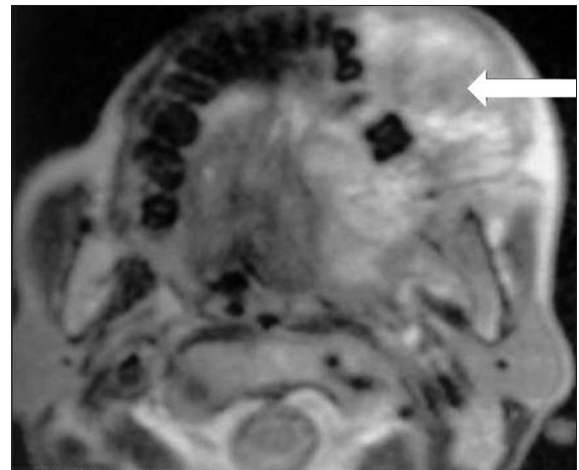


Figure 6: 72-year-old female with swelling on the right side of her mandible diagnosed as carcinoma of the mandible. Axial T1-weighted MRI shows mixed intensity lesion involving mainly the left hemimandible (arrow).

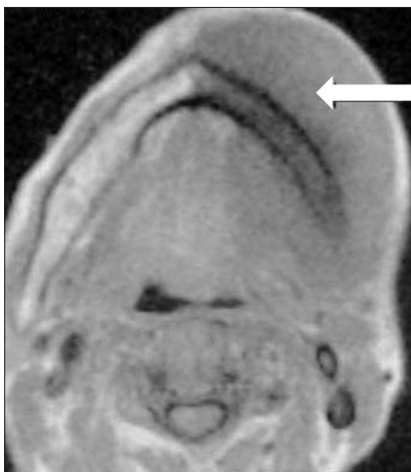

Figure 7: 72-year-old female with swelling on the right side of her mandible diagnosed as carcinoma of the mandible. Coronal T1-weighted MRI shows mixed intensity lesion involving mainly the left hemimandible (arrow).

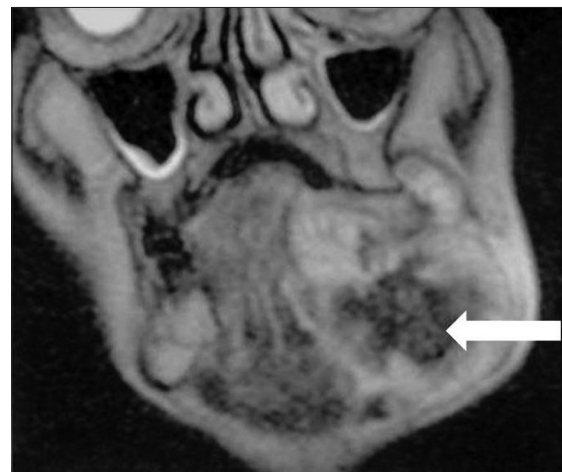

Figure 8: 72-year-old female with swelling on the right side of her mandible diagnosed as carcinoma of the mandible. Coronal T2-weighted MRI shows mass with heterogeneous signal intensity (arrow).

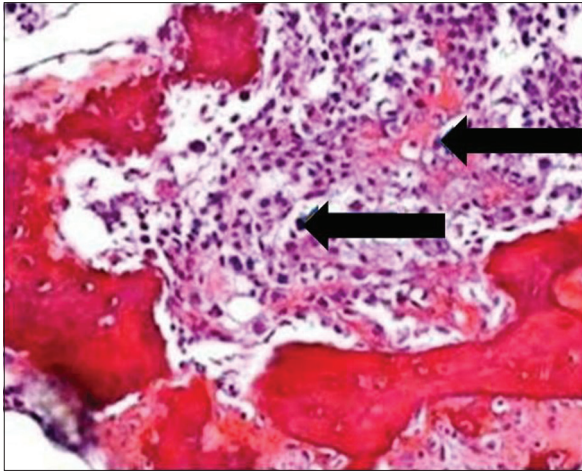


Figure 9: 72-year-old female with swelling on the right side of her mandible diagnosed as osteosarcoma of the mandible. Photomicrograph of hematoxylin and eosin stained biopsy sample ($\times 10$) shows atypical osteoblasts (arrows) seen with new tumor osteoid and bone formation in an irregular pattern.

tumors, followed by chondrosarcoma and Ewing's sarcoma. Despite the fact that osteosarcoma represents only 0.1% of all tumors, it is the second most common malignant bone tumor after multiple myeloma.^[1] Etiologic factors for osteosarcoma include: (1) Radiation therapy for fibrous dysplasia and (2) pre-existing benign bone disorders, especially fibrous dysplasia, cartilaginous lesions, and Paget's disease, and traumas such as automobile or bicycle accident or blow to the mandible.^[3] In the present case, there was a history of trauma to the affected site that happened long ago. The incidence has no gender- or race-based predilection and is estimated to be about 2 or 3 per 100,000 persons. More than 80% of all cases present between 5 and 25 years of age. A second lower peak of incidence occurs in the fifth and sixth decades. The most common presenting features are increase of tumor size, followed by pain, ulceration, and neurological disorders, and the average time between presenting of symptoms and diagnosis ranges from 3 to 5 months.^[4] Our patient was an elderly female 72 years of age and hence falls under the second peak of incidence.

The most common site in the mandible is the body, while maxillary lesions frequently affect the alveolar ridge and body. Maxillary lesions are about half as common as mandibular lesions. In the case reported here, the lesion was present in the body of the mandible. Symptoms seem to start with a firm swelling, with its growth increasing within a few months. This can be accompanied by pain or paresthesia, distortion of facial bones, and dental symptoms that include tooth mobility and toothache leading to ill-advised tooth extraction. Maxillary lesions often lead to epistaxis, nasal obstruction, and visual disturbances, including proptosis and partial blindness.^[5]

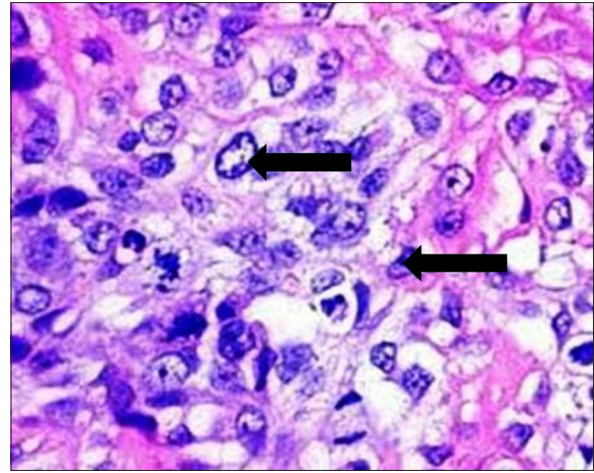


Figure 10: 72-year-old female with swelling on the right side of her mandible diagnosed as carcinoma of the mandible. Photomicrograph of hematoxylin and eosin stained biopsy sample ($\times 40$) shows atypical osteoblasts with new tumor osteoid and bone formation arranged in an irregular pattern (arrows).

In the present case, the patient presented with the following symptoms: Paresthesia of the lip, extra-oral swelling, and intra-oral growth which was firm in consistency. The teeth in the area of interest were mobile as there was less bone support to the teeth. There was no suppuration or exudation from the lesion. The appearance of the intra-oral growth on the floor of the mouth was similar to a squamous cell carcinoma of the mandible.

The diagnosis of osteosarcoma is typically suspected by the radiographic appearance of the affected bone. Ossification in the soft tissue component of the bone, manifesting as a "sunburst" pattern, is classical for osteosarcoma, but is not a sensitive or specific feature. Periosteal new formation with lifting of the cortex leads to the appearance of a Codman's triangle. Garrington et al.,^[2] mentioned in their study that early osteosarcoma of the jaws may show a symmetrically widened periodontal membrane space of about one or more teeth on a periapical dental radiograph, apparently before showing any other prominent radiographic evidence of its presence. In their study, while analyzing 56 patients of osteosarcoma, unfortunately, early dental radiographs were not available in the majority of cases, but 3 cases in which they could be obtained showed widened spaces. Gardner and Mill^[6] reported widened periodontal ligament space due to osteosarcoma with related histological appearance, although the reported widened periodontal ligament space was not symmetrical. Other authors also mentioned the presence of widened periodontal ligament space due to osteosarcoma of jaws, which was not always symmetrical. Other authors have reported the fact that widened periodontal ligament space was found in Ewing's sarcoma, and hence, widened periodontal ligament

space is considered to be a sign of malignancy seen in osteosarcoma, chondrosarcoma, and Ewing's sarcoma of the jaw.

The radiological appearances manifest as mixed, radiolucent/radiopaque lesions, periodontal ligament widening, radiopaque masses with a moth-eaten appearance, Codman's triangle, and sunburst appearance.^[7] The CT appearance of osteosarcoma has been reported as being a mass of mixed radiopacity with a predominant soft tissue component, central calcification/ossifications, and an aggressive destruction of the structures involved.^[2] CT gives images free of superimposition of the surrounding structures. Nonetheless, the dental radiographs, especially periapical views, give a more detailed and better defined image.^[7]

In the present case, CT and MRI scans were done to evaluate bone erosion, soft tissue infiltrations, size and extent of the tumor, and soft tissue ossification of the tumor. Periosteal bone reactions such as sunray appearance was seen. Symmetrical widening of the periodontal ligament space in the involved teeth (Garrington's sign) was also observed in the CT images. MRI showed better delineation of the extent of the lesion. T1-weighted and T2 images, showed hyper- and hypointense areas with destruction of the mandible and transcortical extension, revealing the neoplastic nature of the mass.

The cornerstone of primary jaw osteosarcoma treatment is adequate surgical resection. Radiotherapy or chemotherapy can be used in association with surgical resection or alone as a palliative treatment in advanced cases.^[8] Literature review has shown that patients treated initially by aggressive local or even radical procedures such as hemimandibulectomy fared better. The present case was referred to a higher medical center and palliative chemotherapy was planned and administered, as surgical resection was not feasible due to the extension of the lesion and the age of the patient. Unfortunately, the patient died 4 months after the diagnosis of osteosarcoma.

The prognosis of osteosarcoma was poor before the development of effective chemotherapy. Introduction of multi-agent chemotherapy has improved the survival rates,

with 60–70% patients surviving after treatment.^[9] Response to preoperative neoadjuvant chemotherapy is the most important prognostic factor in osteosarcoma because the degree of drug-induced tumor necrosis is highly correlated with disease-free survival after therapy.^[10] Four months after being referred from our center to the higher center for chemotherapy, our patient died. This may have been due to the age of the patient and her poor general physical condition or may have been due to metastasis to vital organs.

CONCLUSION

Osteosarcoma of the mandible can be diagnosed in imaging scans by its mixed radiolucent and radiopaque features with sunray appearance and Garrington sign. Although the lesion is reported in a 72-year-old female, this lesion rarely occurs in elderly patients. Although, histopathology can provide a confirmation of diagnosis, plain radiographs, CT and MRI scans are essential tools that help in the diagnosis of such lesions.

REFERENCES

1. Shafer WG, Hine MK, Levy BM. A Textbook of Oral Pathology, 4th ed. Philadelphia: WB Saunders; 1983. p. 180.
2. Garrington GE, Scofield HH, Cornyn J, Hooker SP. Osteosarcoma of the jaws: Analysis of 56 cases. *Cancer* 1967;20:377-91.
3. Langlais RP, Langland OE, Nortjé CJ. Diagnostic Imaging of the Jaws, 2nd ed. USA: Williams and Wilkins; 1995. Mirra JM. Osteosarcoma: Intramedullary variants. In: Mirra JM, editor. *Bone Tumors*. 2nd ed. Philadelphia, PA: Lea and Febiger; 1989. p. 249-389.
4. Clark JL, Unni KK, Dahlin DC, Devin KD. Osteosarcoma of the Jaw. *Cancer* 1983;51:2311-6.
5. Nakayama E, Sugiura K, Ishibashi H, Oobu K, Kobayashi I, Yoshiura K. The clinical and diagnostic imaging findings of osteosarcoma of the jaw. *Dentomaxillofac Radiol* 2005;34:182-8.
6. Khorate MM, Goel S, Singh MP, Ahmed J. Osteosarcoma of mandible: A case report and review of literature. *J Cancer Sci Ther* 2010;2:122-5.
7. August M, Magennis P, Dewitt D. Osteogenic sarcoma of the jaws: Factors influencing prognosis. *Int J Oral Maxillofac Surg* 1997;26:198-204.
8. Bruland OS, Pihl A. On the current management of osteosarcoma. A critical evaluation and a proposal for a modified treatment strategy. *Eur J Cancer* 1997;33:1725-31.
9. Davis AM, Bell RS, Goodwin PJ. Prognostic factors in osteosarcoma: A critical review. *J Clin Oncol* 1994;12:423-31.

Source of Support: Nil, **Conflict of Interest:** None declared.