



**Nuclear Medicine** Original Research

## Intracranial Metastasis from Prostate Cancer: Investigation, Incidence, and Imaging Findings in a Large Cohort of Australian Men

Rhiannon McBean<sup>1</sup>, Annaleis Tatkovic<sup>1</sup>, David Chee Wong<sup>1</sup>

<sup>1</sup>I-MED Radiology, The Wesley Hospital, Brisbane, Queensland, Australia.



**\*Corresponding author:**

Rhiannon McBean,  
I-MED Radiology, The  
Wesley Hospital, 87 Lang Pde,  
Brisbane - 4066, Queensland,  
Australia.

rhiannon.mcbean@i-med.  
com.au

Received : 09 March 2021

Accepted : 31 March 2021

Published : 24 April 2021

**DOI**

10.25259/JCIS\_52\_2021

**Quick Response Code:**



### ABSTRACT

**Objectives:** Prostate cancer metastasizing to the brain is remarkably uncommon, with the incidence never having been described in the modern setting. The objective of this study was to determine the incidence and imaging pattern of intracranial metastasis from prostate cancer in a large cohort of Australian men with prostate cancer.

**Material and Methods:** Retrospective review was undertaken of imaging reports for all known prostate cancer patients, who underwent an imaging examination inclusive of the brain, between July 1, 2014, and July 1, 2020. Once an intracranial lesion was identified, all available imaging and clinical notes were reviewed.

**Results:** A total of 5644 imaging examinations which included the brain were identified in 4341 prostate cancer patients. The majority (92.1%) of examinations were 68-Gallium-labeled prostate-specific membrane antigen (<sup>68</sup>Ga-PSMA) positron emission tomography/computed tomography (PET/CT). Eight patients were identified as having an intracranial metastasis from prostate cancer, yielding an incidence of 0.18%. All patients had a Gleason score of 9 (where known), and the majority of patients (5/8) had a non-acinar variant of prostate cancer. At the time of diagnosis of intracranial metastasis, all patients had extensive metastatic disease. Imaging characteristics of the intracranial lesions were highly variable.

**Conclusion:** The incidence of intracranial metastasis in prostate cancer patients has never been well-established. In this study, we determined the incidence as being 0.18%. Given the majority of metastasis constituted unexpected findings on routine restaging <sup>68</sup>Ga-PSMA PET/CT, the incidence determined in our study is arguably the most accurate and clinically relevant described to date.

**Keywords:** 68Ga-PSMA PET/CT, Brain metastasis, Intracranial metastasis, Prostate cancer, Uroradiology

### INTRODUCTION

Prostate cancer metastasizing to the brain is remarkably uncommon. The incidence of intracranial metastasis from prostate cancer is often referred to as being <1%. However in truth, the incidence is undetermined, as the literature is scarce and that which is available has limitations. The majority of the literature on intracranial metastasis from prostate cancer consists of autopsy series, hospital administrative database studies, case reports, or small case series.<sup>[1-8]</sup> To date, incidences of 0.5–4.4% have been determined in various autopsy studies, with the majority of metastasis being not

This is an open-access article distributed under the terms of the Creative Commons Attribution-Non Commercial-Share Alike 4.0 License, which allows others to remix, tweak, and build upon the work non-commercially, as long as the author is credited and the new creations are licensed under the identical terms.

©2021 Published by Scientific Scholar on behalf of Journal of Clinical Imaging Science

identified until after death.<sup>[9,10]</sup> It is, therefore, unsurprising that clinical studies have described the incidence as much lower, with Catane *et al.* identifying only four patients with intracranial metastasis among 3732 prostate cancer patients, giving an incidence of approximately 0.11%.<sup>[9]</sup> The administration database studies performed to date also have various limitations to their estimates, including, for example, being reliant on patients being hospitalized for their disease, or metastasis locations only being recorded at point of cancer diagnosis.<sup>[7,8]</sup> It is worth noting many of these studies are decades old, and it has been suggested that the incidence of intracranial metastasis is increasing and will continue to do so over time, as advances in treatments result in patients living longer.

Only one imaging-based study investigating intracranial metastasis from prostate cancer has been performed to date. This study, by Hatzoglou *et al.*, retrospectively reviewed 11 years' worth of brain magnetic resonance imaging (MRI) in patients with prostate cancer to report an incidence of 0.16%.<sup>[11]</sup> Given brain MRI is not routine in prostate cancer patients, unless relevant pathology is suspected, the incidence based on MRI is unlikely to reflect the true incidence.

68-Gallium-labeled prostate-specific membrane antigen (<sup>68</sup>Ga-PSMA) positron emission tomography/computed tomography (PET/CT) is emerging as the most utilized imaging modality to identify prostate cancer metastasis and monitor progression. In addition to its sensitivity and specificity for identifying sites of prostate cancer, <sup>68</sup>Ga-PSMA PET/CT also has the advantage of a greatly expanded field of view compared to traditional modalities. Typically, a <sup>68</sup>Ga-PSMA PET/CT scan will involve imaging from the calvarial vertex to proximal thighs. Studies have described the superiority of <sup>68</sup>Ga-PSMA PET/CT in characterizing visceral disease over traditional imaging such as CT and multiparametric MRI.<sup>[12,13]</sup> <sup>68</sup>Ga-PSMA PET/CT, therefore, presents an ideal imaging modality for the purposes of identification and understanding of manifestations of typical and atypical sites of disease. The incidence of intracranial metastasis from prostate cancer based on a whole-body imaging modality such as <sup>68</sup>Ga-PSMA PET/CT has never before been described. Therefore, the aim of this study was to determine the incidence and imaging pattern of intracranial metastasis from prostate cancer, in a large sample of men undergoing modern, standard care imaging at a tertiary center.

## MATERIAL AND METHODS

Retrospective review was undertaken of imaging reports for all known prostate cancer patients, who underwent an imaging examination inclusive of the brain at our center, between July 1, 2014, and July 1, 2020. Ethics approval for this study was obtained from the UnitingCare Health Human

Research Ethics Committee (reference number: 2019.31.309). Prostate cancer patients for inclusion in the study were identified in the following ways; any male patient who had a <sup>68</sup>Ga-PSMA PET/CT scan, any male patient who underwent an 18-fluoro-deoxyglucose (FDG) PET/CT where prostate cancer was mentioned on the referral, and any male patient who underwent a brain MRI where prostate cancer was mentioned on the referral. Reports were reviewed to identify those in which an intracranial lesion was identified by the reporting radiologist. If an intracranial lesion was present, all imaging conducted on the patient were reviewed, in addition to clinical notes and histopathology, where available. The information collected during this comprehensive review included imaging date, modality, number of lesions, lesion location, maximum standard uptake value (SUVmax), size, other imaging features, and clinical history (diagnosis, Gleason score, relevant symptoms, serum prostate-specific antigen [PSA] levels). Although all available imaging were reviewed, for the purposes of assessing imaging features of the intracranial metastasis between modalities, imaging was only directly compared if the scans were performed within 4 weeks of each other, and if no treatment had been performed in the interval. Patients were excluded from this study if they had multiple primary cancers.

The incidence of intracranial metastasis from prostate cancer was calculated by dividing the number of unique patients identified as having intracranial metastasis from prostate cancer by the total number of unique prostate cancer patients within this review.

## RESULTS

### Incidence of intracranial metastasis in patients with prostate cancer

This review identified a total of 5644 imaging examinations, inclusive of the brain, performed on 4341 unique prostate cancer patients. A total of eight prostate cancer patients were identified as having an intracranial metastasis from prostate cancer, yielding an incidence of 0.18%. Of the 5644 imaging examinations reviewed, the majority (92.1%) were <sup>68</sup>Ga-PSMA PET/CT scans followed by FDG PET/CT (6.9%) and brain MRI (1.0%) scans. Although <sup>68</sup>Ga-PSMA PET/CT scans are the standard method used at our center for prostate cancer staging/restaging, it is not uncommon for patients to undergo FDG PET/CT instead, reasons for this are typically either because of the presence of a prostate cancer variant with limited PSMA expression or because the patient has concurrent primary cancers and the FDG PET/CT scan is performed to monitor both cancers. Brain MRIs are largely performed to investigate spinal cord and cranial disease, new neurological symptoms, or new lesion/s observed on other imaging modalities.

**Table 1:** Characteristics of the eight patients with intracranial metastasis from prostate cancer.

Patient	Age at time of intracranial metastasis (years)	Time since prostate cancer diagnosis (years)	Histopathology	Treatment history	PSA at time of intracranial metastasis (ng/mL)	Neurological symptoms	Survival following intracranial metastasis (months)
1	78	1	Prostatic ductal adenocarcinoma, Gleason 4+5 = 9	ADT, chemotherapy, radiotherapy, brachytherapy, 177Lu-PSMA	27	No	12
2	63	4	Unknown	ADT, prostatectomy, radiotherapy	9	No	Unknown, patient lost to follow-up (at 3 years)
3	74	4	Small-cell neuroendocrine variant carcinoma of the prostate, Gleason 4+5 = 9	ADT, chemotherapy, radiotherapy, 177 Lu-PSMA	0.09 (non-PSA secreting)	No	3
4	59	7	Small-cell neuroendocrine variant carcinoma of the prostate, Gleason unknown	ADT, chemotherapy, radiotherapy	3.2 (non-PSA secreting)	No	Patient still living (at 3 months)
5	75	7	Prostatic adenocarcinoma, Gleason 4+5 = 9	ADT, prostatectomy, radiotherapy, 177Lu-PSMA	1160	Yes – agitated delirium, restless and confabulating, impulsive	8
6	75	9	Prostatic adenocarcinoma of mixed acinar (90%) and ductal (10%) types, Gleason 5+4 = 9	ADT, chemotherapy, radiotherapy, 177Lu-PSMA	16 (non-PSA secreting)	No	1
7	74	8	Prostatic adenocarcinoma, Gleason 4+5 = 9	ADT, chemotherapy, radiotherapy	46	Yes – specifics unknown “2-week history of worsening neurological symptoms”	15
8	73	1	Small-cell neuroendocrine variant carcinoma of the prostate, Gleason unknown	ADT, chemotherapy, radiotherapy	0.11 (non-PSA secreting)	Yes – 2-week history of headaches and vomiting	1

ADT: Androgen deprivation therapy, 177Lu-PSMA: Lutetium-177 prostate-specific membrane antigen, PSA: Prostate-specific antigen

### Patient characteristics

Characteristics of the eight prostate cancer patients with intracranial metastasis are summarized in Table 1. Details of histopathology conducted at the point of prostate cancer diagnosis were available for seven of eight patients to limited completeness. A Gleason score of 9 was observed in all patients ( $n = 5$ ) who had this data available. Additional information showed a spectrum of histopathological subtypes, inclusive of prostatic adenocarcinoma ( $n = 2$ ), small-cell neuroendocrine variant carcinoma of the prostate ( $n = 3$ ), prostatic ductal adenocarcinoma ( $n = 1$ ), and

prostatic adenocarcinoma of mixed acinar (90%) and ductal (10%) types ( $n = 1$ ).

A lapse of 1–9 years was observed between the original prostate cancer diagnosis and the identification of intracranial metastasis (mean: 5.1, median: 5.5). The mean age of the patients at the time of diagnosis of intracranial metastasis was 71 years (median: 74, range: 59–78). At the time of diagnosis of intracranial metastasis, the mean PSA level was 157.7 ng/mL (median: 12.5, range: 0.09–1160), noting four of the patients (50%) had non-PSA secreting tumors. All patients had been previously treated with androgen

deprivation therapy and radiotherapy. Other previous treatments were chemotherapy (6/8), lutetium-177 (<sup>177</sup>Lu)-PSMA (4/8), prostatectomy (2/8), and brachytherapy (1/8).

At the time of this retrospective review, six patients had died and one patient was known to be alive (3-month post-diagnosis of intracranial metastasis). The survival status of one patient was unknown, having been lost to follow-up 3 years post-diagnosis of intracranial metastasis. In the patients known to be deceased, the mean time of survival from diagnosis of an intracranial metastasis was 6.6 months (median: 5.5, range: 1–15).

### Radiological findings

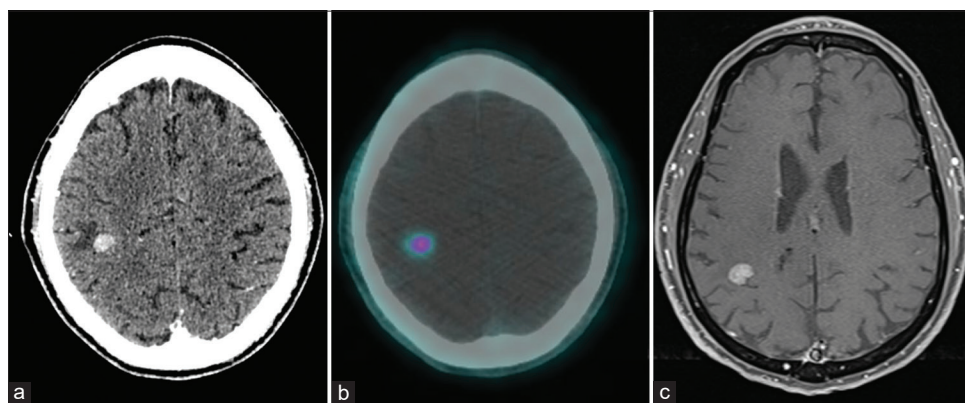
Radiological findings of the eight prostate cancer patients with intracranial metastasis are summarized in Table 2 and presented in Figures 1-5. In five patients, the diagnosis of an intracranial metastasis was an unexpected finding on a routine restaging <sup>68</sup>Ga-PSMA PET/CT scan (patients 1–4). Four of eight patients had both a <sup>68</sup>Ga-PSMA PET/CT and MRI scan performed within 4 weeks. Two patients had a <sup>68</sup>Ga-PSMA PET/CT only (patients 2 and 3) and two patients had a brain MRI only (patients 7 and 8). In three of the four patients with both imaging modalities performed, the brain MRI was performed following identification of an intracranial lesion on routine restaging <sup>68</sup>Ga-PSMA PET/CT (patients 1, 4, and 6). In the remaining patient [patient 5, Figure 3], no intracranial lesion was observed on the routine restaging <sup>68</sup>Ga-PSMA PET/CT, while brain MRI performed 18 days later to investigate new neurological symptoms showed diffuse leptomeningeal metastases in the supratentorial region. Imaging was also inconsistent between modalities in another patient [patient 6, Figure 4], in which one brain lesion was observed on the routine restaging <sup>68</sup>Ga-PSMA PET/CT, while MRI performed 7 days later demonstrated multiple very small metastases.

A hallmark imaging pattern was not observed across patients. Three patients in the study had one intracranial lesion (patients 1, 2 and 4), while the other five patients had multiple lesions. The size of lesions was highly variable, with the largest intracranial lesion in each patient ranging from 4.5 mm to 27 mm. In two patients (patients 2 and 4), the intracranial lesion originated from cranial lesion extension. On MRI or CT, lesion enhancement was observed in all patients, with surrounding edema also seen in three patients. Other imaging features such as hemorrhage and cystic/necrotic changes were not observed. Maximum SUV of the lesions ranged from 2.0 to 26 with avidity patterns varying between heterogeneous, mild, and intense avidity. As mentioned, in patient 5, the intracranial disease was diffuse leptomeningeal disease which was neither avid nor readily observed on <sup>68</sup>Ga-PSMA PET/CT imaging.

At the time of diagnosis of intracranial metastasis, all patients had extensive metastatic disease, inclusive of bone metastases in all patients (8/8), and lymph node metastases in most patients (6/8). Visceral disease was also common, being observed in four patients (4/8).

### DISCUSSION

In this study, we reviewed all prostate cancer patients at our center that underwent imaging inclusive of the brain over a 6-year period. The incidence of intracranial metastasis from prostate cancer observed in this study was 0.18%. The incidence of intracranial metastasis has never before been described based on routine imaging, inclusive of a whole-body imaging modality. Previously, only one imaging-based study has been undertaken, utilizing brain MRIs.<sup>[11]</sup> As highlighted by our findings, in which only 1% of imaging on prostate cancer patients was a brain MRI, a study based on MRI alone cannot accurately reflect the



**Figure 1:** A 78-year-old male (patient 1) with a 1 year history of prostatic ductal adenocarcinoma, Gleason 9. (a and b) Restaging <sup>68</sup>Ga-PSMA PET/CT imaging performed following lutetium-177-PSMA therapy identified a single lesion in the right parietal lobe. The lesion was 11.5 mm and intensively avid with a SUVmax of 3.6. (c) On a brain MRI performed 17 days later, the lesion was observed to be enhancing with surrounding edema.

**Table 2:** Imaging findings of the intracranial metastasis from prostate cancer.

Patient	Imaging performed, reason, interval	Number of lesions, location	PSMA avidity pattern, SUVmax	Size, of largest if multiple (mm)	Other features on MRI (or CT)	Other sites of disease
1 [Figure 1]	<sup>68</sup> Ga-PSMA PET/CT, re-staging following <sup>177</sup> Lu-PSMA Brain MRI, radiotherapy planning, 17 days later	One lesion, supratentorial in the right parietal lobe	Intense, 3.6	11.5	Enhancement, surrounding edema	Extensive bone metastases
2	<sup>68</sup> Ga-PSMA PET/CT, restaging following biochemical recurrence	One lesion, calvarial bone metastasis with supratentorial intracranial extension in the right parietal lobe	Intense, 21	27	Enhancement	Multiple bone, nodal, and visceral metastases (lung)
3	<sup>68</sup> Ga-PSMA PET/CT, restaging following <sup>177</sup> Lu-PSMA	Multiple, supratentorial, and infratentorial	Heterogeneous, 2.0	14.5	Enhancement, surrounding edema (on CT brain)	Multiple bone, nodal, and visceral metastases (lung, liver)
4 [Figure 2]	<sup>68</sup> Ga-PSMA PET/CT, restaging to assess suitability for <sup>177</sup> Lu-PSMA Brain MRI, radiotherapy planning, 1 day later	One lesion, left skull base in the occipital region with intracranial extension into the inferior aspect of the left posterior fossa compressing the cerebellum	Intense, 26	40 total, 25 intracranial	Enhancement	Extensive bone metastases
5 [Figure 3]	<sup>68</sup> Ga-PSMA PET/CT, restaging following <sup>177</sup> Lu-PSMA Brain MRI, investigate neurological symptoms, 18 days later	No disease readily visible on <sup>68</sup> Ga-PSMA PET/CT On MRI diffuse leptomeningeal disease, suspected to be infiltrating the cranium, supratentorial	Not avid	Not quantifiable	Enhancement	Extensive bone and nodal metastases
6 [Figure 4]	<sup>68</sup> Ga-PSMA PET/CT, re-staging following <sup>177</sup> Lu-PSMA Brain MRI, radiotherapy planning, 7 days later	One lesion observed on <sup>68</sup> Ga-PSMA PET/CT, left frontoparietal On MRI five lesions seen, supratentorial and infratentorial	Mild, 2.8	4.5	Enhancement	Extensive bone and nodal metastases
7	Brain MRI, investigate neurological symptoms	Multiple, supratentorial and infratentorial	N/A	19	Enhancement, surrounding edema	Extensive bone, nodal, and visceral metastases (adrenal, retroperitoneal)
8 [Figure 5]	Brain MRI, investigate neurological symptoms	Innumerable, supratentorial, and infratentorial	N/A	8	Enhancement, diffusion restriction	Extensive bone, nodal, and visceral metastases (lung)

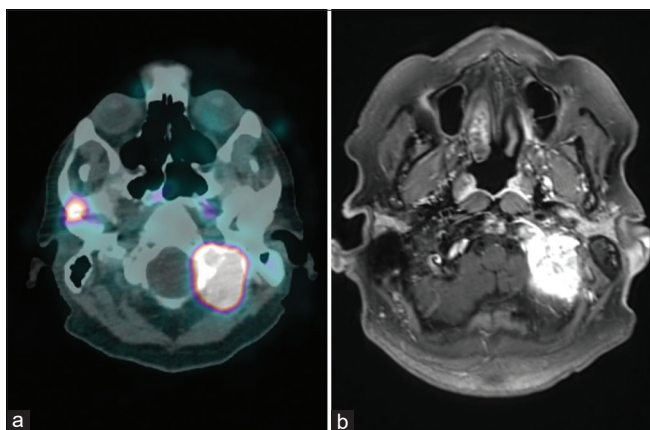
SUVmax: Maximum standard uptake value, <sup>177</sup>Lu-PSMA: Lutetium-177 prostate-specific membrane antigen, <sup>68</sup>Ga-PSMA PET/CT: <sup>68</sup>-Gallium-labeled prostate-specific membrane antigen positron emission tomography/computed tomography, MRI: Magnetic resonance imaging

incidence of intracranial metastasis. Further, with much of the literature regarding metastasis from prostate cancer being either case report, small case series, or decades old

autopsy studies, the incidence determined in our study is arguably the most accurate and clinically relevant described to date.



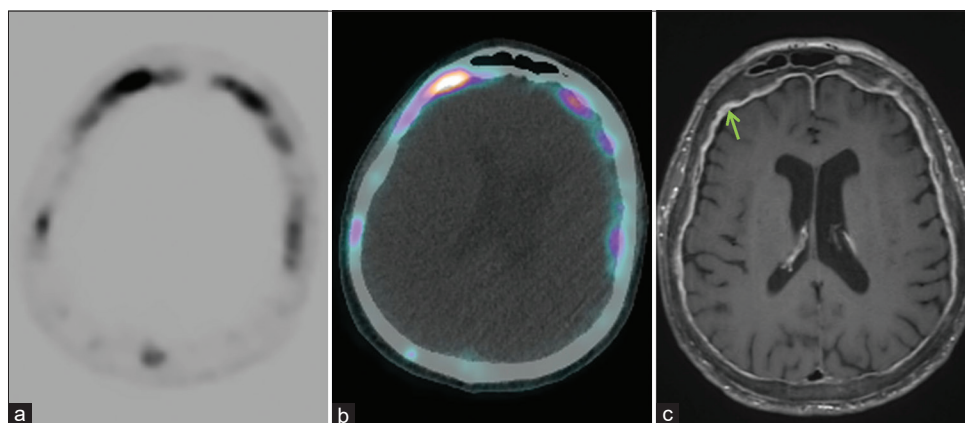
All patients in this study with a Gleason score available had a score of 9. This is unsurprising and supports the high risk and aggressiveness associated with high Gleason scores. Of interest, the majority of men identified in this study represented the less common prostate cancer patient; evidenced by only two patients having prostatic adenocarcinoma as their histopathological subtype. The remaining five patients (histopathological data missing for one patient) had a non-acinar variant of prostate cancer, which typically accounts for only 5–10% of primary prostate cancers.<sup>[14]</sup> Small-cell neuroendocrine variant carcinoma of the prostate, typically seen in 0.3–1% of the prostate cancer population was the most common variant



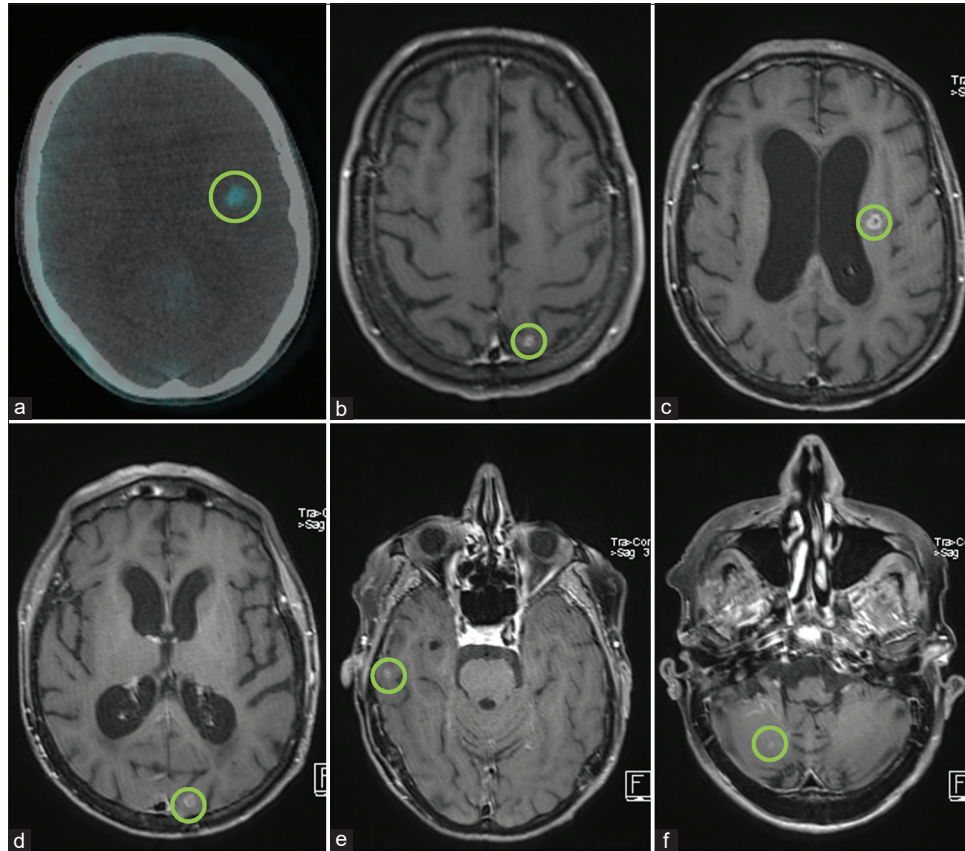
**Figure 2:** A 59-year-old male (patient 4) with a 7-year history of small-cell neuroendocrine variant carcinoma of the prostate. Restaging <sup>68</sup>Ga-PSMA PET/CT imaging performed following lutetium-177-PSMA therapy identified a lesion in the left skull base in the occipital region with intracranial extension into the left posterior fossa. The lesion was very large (25 mm intracranial component) and intensely avid with a SUVmax of 26.

in our study, being observed in three patients. Ductal adenocarcinoma variants, which have a typical incidence of 3%, were observed in two patients in this study. This suggests that these prostate cancer variants are more aggressive and may be better at overcoming the body's natural defenses, such as the blood brain barrier. This has been observed by others, with these subtypes of prostate cancer well known for being aggressive and generating metastases in atypical locations.<sup>[14,15]</sup> This is particularly true for small-cell neuroendocrine variants, which are known for a propensity for rapid and widespread disease, often without elevated serum PSA, as seen in our study. In the MRI-based incidence study on intracranial metastasis from prostate cancer, Hatzoglou *et al.* also found that patients with a variant subtype were particularly prone to metastasis to the brain.<sup>[11]</sup>

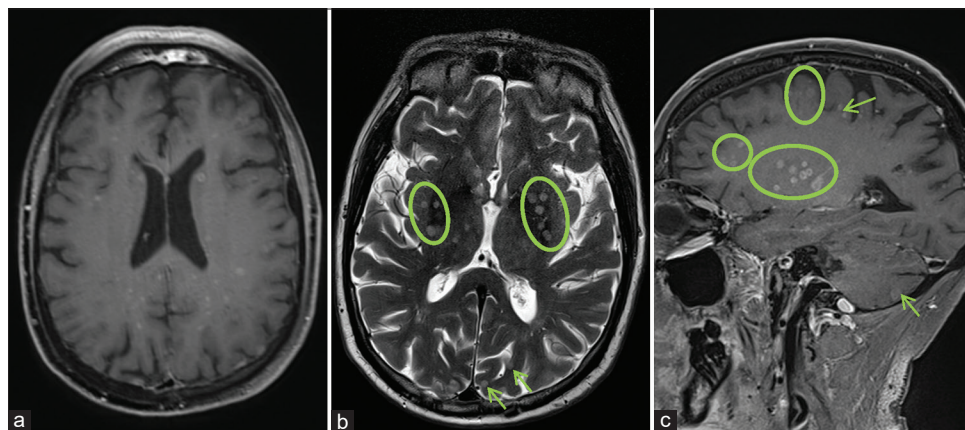
In this study, the majority of patients were asymptomatic, with the intracranial metastasis being an unexpected finding on routine <sup>68</sup>Ga-PSMA PET/CT scans performed for restaging. This scenario is likely to represent the “new normal” as <sup>68</sup>Ga-PSMA PET/CT scanning continues to become the routine imaging modality utilized and patients live longer with advances in therapies. Interestingly, in one patient, a routine <sup>68</sup>Ga-PSMA PET/CT failed to detect the patient's intracranial metastasis which was identified when a MRI brain was performed around 2 weeks later to investigate the onset of neurological symptoms. Further, in a second patient, <sup>68</sup>Ga-PSMA PET/CT identified one brain lesion, whereas an MRI performed 1 week later identified multiple lesions. In both cases, it is assumed the missed prostate cancer metastases were too small to be detected by <sup>68</sup>Ga-PSMA PET/CT and may also have had limited PSMA expression. These two cases demonstrate that MRI remains



**Figure 3:** A 75-year-old male (patient 5) with a 7-year history of prostate adenocarcinoma, Gleason 9. (a and b) Restaging <sup>68</sup>Ga-PSMA PET/CT imaging performed following lutetium-177-PSMA therapy showed no obvious intracranial disease; avidity observed was presumed to be cranial disease which was not readily visible. (c) A subsequent MRI confirmed the presence of diffuse frontal leptomeningeal disease (arrow) infiltrating the cranium.



**Figure 4:** A 75-year-old male (patient 6) with a 9-year history of prostate adenocarcinoma of mixed acinar and ductal subtypes, Gleason 9. (a) Restaging  $^{68}\text{Ga}$ -PSMA PET/CT imaging performed following lutetium-177-PSMA therapy identified one left frontoparietal lesion (circle) demonstrating mild avidity (SUVmax 2.8). (b-f) Multiple supratentorial and infratentorial lesions (circles) were observed on MRI imaging performed 7 days later.



**Figure 5:** A 73-year-old male (patient 8) with a 1-year history of small-cell neuroendocrine variant carcinoma of the prostate. MRI imaging performed to investigate neurological symptoms identified innumerable brain metastases (circles, arrows) including within the cerebral hemispheres, deep nuclei, brainstem, and cerebellum. These varied in size with the largest lesions measuring up to 8 mm. Many of the lesions were associated with diffusion restriction.

the gold standard for detection and characterization of intracranial lesions and should be performed when further investigation is warranted. Overall, there was no distinct

radiological pattern of intracranial metastasis observed, with large variability in number of lesions, distribution, avidity, and size. The literature describes there being no

characteristic appearance of intracranial metastasis from prostate cancer on MRI; our study supports this and adds that there also appears to be no distinct  $^{68}\text{Ga}$ -PSMA PET/CT imaging features.

It is well recognized that intracranial metastasis is a terminal event associated with poor prognosis.<sup>[1,11]</sup> As reported by Ferverza *et al.*, the 1-year survival rate is 18% with an average survival of 7.6 months.<sup>[1]</sup> The patients in our study were consistent with this, having a mean survival of 6.6 months. It has been suggested that the incidence of intracranial metastasis will increase over time, as advances in treatments lead to increased survival of prostate cancer patients. This suggestion is supported by a 18-year review performed by Caffo *et al.* in which the authors described an increase in incidence of brain metastasis at their institution from 0.8% to 3% in the pre- and post-docetaxel era, respectively.<sup>[16]</sup> In our study, 50% of the patients had undergone  $^{177}\text{Lu}$ -PSMA therapy, an emerging treatment for prostate cancer which has only become available in the last several years.<sup>[17]</sup> This high proportion of  $^{177}\text{Lu}$ -PSMA treated patients provides evidence our cohort represents modern-day prostate cancer patients being treated at tertiary centers.

A limitation of this study is that the histopathological basis of the intracranial lesions was assumed to be the same as the primary prostate cancer. Biopsy of the intracranial lesions had not been performed in any of the patients in this study, as this does not reflect routine practice. In an effort to ensure the intracranial metastasis observed was of prostatic origin, any patient with concurrent primaries was excluded. A further limitation of this study is that our findings describe those observed at a tertiary center with focuses on prostate cancer imaging and care. Thus, our results may not reflect the general prostate cancer population.

## CONCLUSION

With the advent of whole-body imaging for staging/restaging, combined with advances in therapies, the incidence of intracranial metastasis from prostate cancer in a modern, real-world setting was unknown. In this study, we determined the incidence as being 0.18%. Given the majority of intracranial metastasis identified here constituted unexpected findings on routine restaging  $^{68}\text{Ga}$ -PSMA PET/CT, the incidence determined in our study is arguably the most accurate and clinically relevant described to date. Although intracranial metastasis is a rarity, recognition is important given the implication on patient prognosis.

## Declaration of patient consent

Institutional Review Board (IRB) permission obtained for the study.

## Financial support and sponsorship

Nil.

## Conflicts of interest

There are no conflicts of interest.

## REFERENCES

1. Ferverza FC, Wolanskyj AP, Eklund HE, Richardson RL. Brain metastasis: An unusual complication from prostatic adenocarcinoma. *Mayo Clin Proc* 2000;75:79-82.
2. Gzell C, Kench J, Stockler M, Hruby G. Biopsy-proven brain metastases from prostate cancer: A series of four cases with review of the literature. *Int Urol and Nephrol* 2013;45:735-42.
3. Chakraborty PS, Kumar R, Tripathi M, Das CJ, Bal C. Detection of brain metastasis with  $^{68}\text{Ga}$ -labeled PSMA ligand PET/CT: A novel radiotracer for imaging of prostate carcinoma. *Clin Nucl Med* 2015;40:328-9.
4. Chan M, Hsiao E, Turner J. Cerebellar metastases from prostate cancer on  $^{68}\text{Ga}$ -PSMA PET/CT. *Clin Nucl Med* 2017;42:193-4.
5. Lam A, Gan PY. Metastatic prostate adenocarcinoma to the brain: Case reports and literature review. *J Neurol Surg Rep* 2017;78:e62.
6. Lodhia V, Puspanathan T. Insidious enemy: Downside to prolonged survival in prostate cancer. *BMJ Case Rep* 2017;2017:bcr2017220613.
7. Gandaglia G, Abdollah F, Schiffmann J, Trudeau V, Shariat SF, Kim SP, *et al.* Distribution of metastatic sites in patients with prostate cancer: A population-based analysis. *Prostate* 2014;74:210-6.
8. Shou J, Zhang Q, Wang S, Zhang D. The prognosis of different distant metastases pattern in prostate cancer: A population based retrospective study. *Prostate* 2018;78:491-7.
9. Catane R, Kaufman J, West C, Merrin C, Tsukada Y, Murphy GP. Brain metastasis from prostatic carcinoma. *Cancer* 1976;38:2583-7.
10. Saitoh H, Hida M, Shimbo T, Nakamura K, Yamagata J, Satoh T. Metastatic patterns of prostatic cancer: Correlation between sites and number of organs involved. *Cancer* 1984;54:3078-84.
11. Hatzoglou V, Patel GV, Morris MJ, Curtis K, Zhang Z, Shi W, *et al.* Brain metastases from prostate cancer: An 11-year analysis in the MRI era with emphasis on imaging characteristics, incidence, and prognosis. *J Neuroimaging* 2014;24:161-6.
12. Maurer T, Gschwend J, Rauscher I, Souvatzoglou M, Haller B, Weirich G, *et al.* Diagnostic efficacy of ( $^{68}\text{Ga}$ ) Gallium-PSMA-PET compared to conventional imaging in lymph node staging of 130 consecutive patients with intermediate to high-risk prostate cancer. *J Urol* 2015;195(14):36-43.
13. Tulsyan S, Das CJ, Tripathi M, Seth A, Kumar R, Bal C. Comparison of  $^{68}\text{Ga}$ -PSMA PET/CT and multiparametric MRI for staging of high-risk prostate cancer. *Nucl Med Commun* 2017;38:1094-102.
14. Humphrey PA. Histological variants of prostatic carcinoma and their significance. *Histopathology* 2012;60:59-74.



15. de Oliveira Barros EG, Da Costa NM, Palmero CY, Pinto LF, Nasciutti LE, Palumbo A Jr. Malignant invasion of the central nervous system: The hidden face of a poorly understood outcome of prostate cancer. *World J Urol* 2018;36:2009-19.
16. Caffo O, Veccia A, Fellin G, Mussari S, Russo L, Tomio L, *et al.* Frequency of brain metastases from prostate cancer: An 18-year single-institution experience. *J Neurooncol* 2013;111:163-7.
17. McBean R, O’Kane B, Parsons R, Wong D. Lu177-PSMA therapy for men with advanced prostate cancer: Initial 18 months experience at a single Australian tertiary institution. *J Med Imaging Radiat Oncol* 2019;63:538-45.

**How to cite this article:** McBean R, Tatkovic A, Wong DC. Intracranial metastasis from prostate cancer: Investigation, incidence, and imaging findings in a large cohort of Australian men. *J Clin Imaging Sci* 2021;11:24.