

CASE REPORT

# The Forgotten Guide Wire: A Rare Complication of Hemodialysis Catheter Insertion

Said Abuhasna, Dirar Abdallah, Masood ur Rahman

Department of Critical Care Medicine, Tawam Hospital, Al Ain, Abu Dhabi, United Arab Emirates

Address for correspondence:

Dr. Said Abuhasna,  
 Department of Critical Care  
 Medicine, Tawam Hospital, P.O. Box  
 15258, Al Ain, Abu Dhabi, UAE.  
 E-mail: [sabuhasna@tawamhospital.ae](mailto:sabuhasna@tawamhospital.ae)



Received : 24-05-2011  
 Accepted : 30-06-2011  
 Published : 30-07-2011

## ABSTRACT

A rare complication of a hemodialysis catheter insertion is the loss of the complete guide wire into the circulation. A complete guide wire in the circulation may not necessarily produce symptoms, and it may remain unnoticed for a significant period of time. We present a rare case where a complete guide wire was lost into the circulation during insertion of a hemodialysis catheter into the right femoral vein in a 19-year-old female with systemic lupus erythromatosis. The patient remained asymptomatic through two plasmapheresis treatments over a period of 2 days. The guide wire was eventually retrieved without complications. The factors leading to the wire being forgotten will be reviewed, and the measures initiated to prevent any future occurrence will be addressed.

**Key words:** Central venous catheter, hemodialysis, plasmapheresis

## INTRODUCTION

A rare complication of hemodialysis catheter insertion is migration of a guide wire into the circulation during the insertion by the operator.<sup>[1]</sup> Intravascular migration of a broken guide wire has the potential for inducing vascular/tissue damage, thromboses, embolism, and dysrhythmias.<sup>[2]</sup> However, a complete guide wire migration into the circulation may not induce symptoms and its loss into the circulation may remain unnoticed for a significant period

of time.<sup>[3]</sup> We present such a case in a 19-year-old female with systemic lupus erythromatosis (SLE), who underwent insertion of a hemodialysis catheter (Quinton, Covidien, Mansfield, MA, USA) for plasmapheresis. The authors analyze the reasons for forgetting the guide wire while inserting a central line catheter and suggest a method to prevent its recurrence.

## CASE REPORT

A 19-year-old female (weight 66 kg, height 155 cm) with SLE was admitted to the intensive care unit (ICU) with dyspnea and hypoxemia despite therapy with high dose steroids and cyclophosphamide for 5 days. The decision was made to initiate plasmapheresis after an informed consent was secured for a hemodialysis catheter insertion. A size 11-French (3.7 mm) 20 cm long hemodialysis catheter (Quinton, Covidien, Mansfield, MA, USA) was inserted into

Access this article online	
Quick Response Code:	Website: <a href="http://www.clinicalimaging-science.org">www.clinicalimaging-science.org</a>
	DOI: 10.4103/2156-7514.83397

Copyright: © 2011 Abuhasna S. This is an open-access article distributed under the terms of the Creative Commons Attribution License, which permits unrestricted use, distribution, and reproduction in any medium, provided the original author and source are credited.

This article may be cited as:  
 Abuhasna S, Abdallah D, ur Rahman M. The Forgotten Guide Wire: A Rare Complication of Hemodialysis Catheter Insertion. J Clin Imaging Sci 2011;1:40.  
 Available FREE in open access from: <http://www.clinicalimaging-science.org/text.asp?2011/1/1/40/83397>

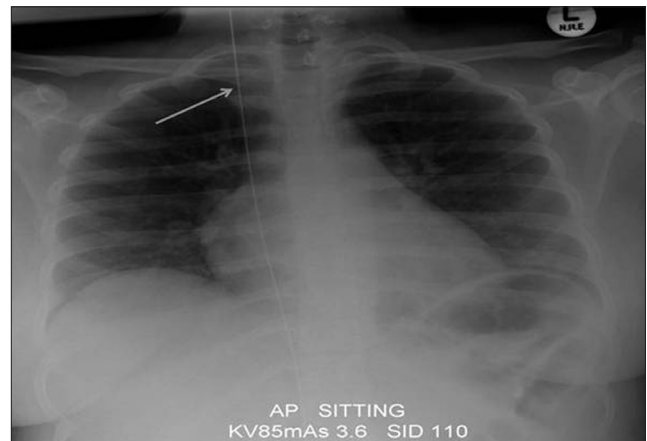
the right femoral vein by an ICU “specialist”. No abdominal radiographs were obtained to ascertain the location of the catheter; however, a chest radiograph obtained later that day for follow-up on pulmonary infiltrates was reported to show a possible guide wire in the right side of the chest. The ICU physicians dismissed the radiologist report considering that the patient had not undergone attempts at internal jugular or the subclavian veins cannulations. Meanwhile, the patient underwent two plasmapheresis therapies through the catheter over two consecutive days without any symptoms. Another chest radiograph performed on the second day was reported to show an intact guide wire in the right hemothorax. A review of the radiographs by the ICU team confirmed the presence of an intact guide wire in the chest [Figure 1]. An abdominal radiograph confirmed that the wire was originating from the hemodialysis catheter [Figure 2] inserted into the right femoral vein two days earlier for plasmapheresis. The guide wire was then extracted from the Quinton catheter by the intensivist. The patient underwent five additional plasmapheresis therapies uneventfully and was discharged home of the seventh day of hospitalization in good physical condition.

## DISCUSSION

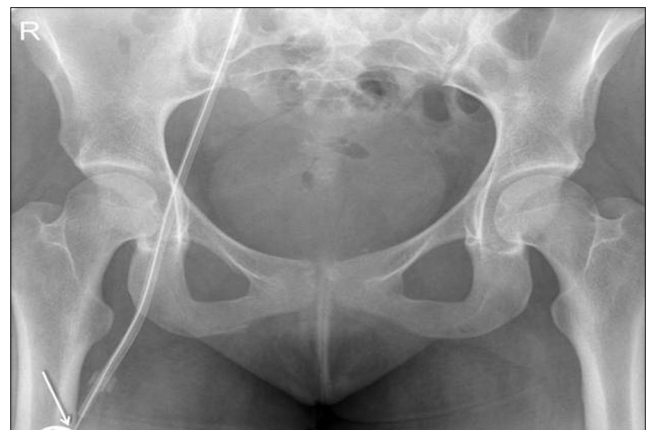Percutaneous insertion of a hemodialysis catheter requires attention to details including application of aseptic techniques, appropriate hemostasis, and strategies to prevent loss of a guide wire into the circulation.<sup>[1]</sup> We present a case of a “forgotten guide wire” in the circulation for 3 days, in a patient who underwent insertion of a hemodialysis catheter for plasmapheresis. Factors that contribute to a guide wire loss into the circulation include operator inexperience, lack of supervision, and inattention.<sup>[1-4]</sup> The operator in this case had eight years of experience in placing central venous catheter and hemodialysis catheters and therefore, he did not need supervision. However, the catheter was inserted in the early hours of morning and therefore, it is possible that fatigue played a role in the failure to remove the guide wire from the circulation. Establishing a protocol that every operator follows may prevent such a complication. Such protocols may include firmly holding to the tip of the guide wire during insertion of a catheter and counting needles and wires at the end of the procedure so that all of a components of a central venous catheter or a hemodialysis catheter set are accounted for.

A postprocedural chest radiograph is generally considered essential following cannulation of the internal jugular or subclavian veins, but is less frequently performed following cannulation of a femoral vein in adult patients in the ICU.<sup>[4]</sup>


In this case, the report by the radiologist of the presence of a guide wire was dismissed by the intensivists as an artifact since there were no attempts at vein cannulation in the neck or chest. The chest radiograph was obtained with the patient in the sitting position. The presence of the wire may have been missed had the chest radiograph not been taken in the sitting position considering the length of the wire [70 cm, Figure 3] in relation to the height of the patient (177 cm). Since the occurrence of this complication,



**Figure 1:** A chest radiograph taken with the patient in the sitting position shows the presence of the intact guide wire in the right hemothorax.



**Figure 2:** An abdominal radiograph shows the tip of the guide wire originating from the hemodialysis catheter inserted in the right femoral vein.



**Figure 3:** The guide wire shown coiled measures 70 cm.

we have introduced changes to our ICU policy for insertion of a hemodialysis catheter or a central venous catheter. Prior to the procedure, the operator must turn his pager and/or mobile telephone to an individual not involved with the procedure in order to avoid any distractions. At the end of the procedure, a "time out" is instituted during which the operator calls out loudly and clearly that "the guide wire is out of the patient" and this is confirmed by the bedside nurse. These findings are then documented in the patient's medical (electronic) records.

## REFERENCES

1. Schummer W, Schummer C, Gaser E, Bartunek R. Loss of the guide wire: Mishap or blunder? *Br J Anaesth* 2002;88:144-6.
2. Tong MKH. Misplacement of a right internal jugular vein hemodialysis catheter into the mediastinum. *Hong Kong Med J* 2004;10:135-8.
3. Wadehra A, Ganjoo P, Tandon MS. Guide wire loss during central venous cannulation. *Indian J Anaesth* 2010;54:587-8.
4. Gordon PC, Linton DM. The missing wire--a complication of central venous catheterization. *Anaesth Intensive Care* 1992;20:77-9.

**Source of Support:** Nil, **Conflict of Interest:** None declared.