

## CASE REPORT

# Asymptomatic Incidental Ductal Carcinoma *in situ* in a Male Breast Presenting with Contralateral Gynecomastia

Laura M. Isley, Rebecca J. Leddy, Tihana Rumboldt<sup>1</sup>, Jacqueline M. Bernard

Department of Radiology and <sup>1</sup>Pathology, Medical University of South Carolina, Charleston, SC, USA

## Address for correspondence:

Dr. Laura Isley,  
Department of Radiology, MSC 323,  
Medical University of South Carolina,  
96 Jonathan Lucas Street, Rm. 210 CSB,  
Charleston, SC 29425-3230, USA.  
E-mail: [laura.isley1@gmail.com](mailto:laura.isley1@gmail.com)



Received : 04-01-2012

Accepted : 20-02-2012

Published : 19-03-2012

## ABSTRACT

Ductal carcinoma *in situ* (DCIS) in males is rare and usually presents with symptoms on the affected side, such as, palpable mass or bloody nipple discharge. Even as DCIS has been reported in conjunction with gynecomastia in the same breast, we report an unusual case of a 62-year-old Caucasian male, with no family history of breast cancer, who presented with symptomatic side gynecomastia, and was incidentally found to have DCIS in a completely asymptomatic left breast. To the best of our knowledge, this case is the first report in literature of asymptomatic, incidentally discovered DCIS in a male patient.

**Key words:** Ductal carcinoma *in situ*, male DCIS, male breast cancer

## INTRODUCTION

Gynecomastia is an over-development of the glandular tissue of the breast region in males. This is different from fat deposits in the breast area seen in obese men. It occurs in young boys during puberty and in older men and results from an imbalance in the hormone levels. This is a benign condition. Breast cancer in men is uncommon. Coexistence

of gynecomastia and ductal carcinoma, though rare, has been reported in literature.

## CASE REPORT

A 62-year-old Caucasian male presented with a complaint of pain and swelling in the retroareolar right breast. The left breast was asymptomatic. The patient denied any family history of breast cancer and had no history of trauma to the breast. His only medication was Ritalin.

The patient underwent a bilateral digital diagnostic mammogram with *mediolateral oblique (MLO)* and *craniocaudal (CC)* views of both breasts (Hologic Lorad Selenia). The breasts showed scant fibroglandular tissue consistent with male breasts. There was a flame-shaped

## Access this article online

Quick Response Code:



Website:

[www.clinicalimagingscience.org](http://www.clinicalimagingscience.org)

DOI:

10.4103/2156-7514.94021

Copyright: © 2012 Isley LM. This is an open-access article distributed under the terms of the Creative Commons Attribution License, which permits unrestricted use, distribution, and reproduction in any medium, provided the original author and source are credited.

This article may be cited as:

Isley LM, Leddy RJ, Rumboldt T, Bernard JM. Asymptomatic Incidental Ductal Carcinoma *in situ* in a Male Breast Presenting with Contralateral Gynecomastia. J Clin Imaging Sci 2012;2:9. Available FREE in open access from: <http://www.clinicalimagingscience.org/text.asp?2012/2/1/9/94021>

density within the retroareolar right breast consistent with mammographic gynecomastia. There was no evidence of gynecomastia in the left breast [Figure 1]. Further evaluation with ultrasound was recommended for confirmation and to *evaluate for any underlying mass*. Additional magnification views of the left breast were performed for regional retroareolar pleomorphic and linear microcalcifications extending to the upper outer quadrant [Figure 2]. These microcalcifications were suspicious, and given the regional distribution, further evaluation with ultrasound was recommended to *evaluate for any associated mass*. There were no additional suspicious masses, microcalcifications, or areas of architectural distortion in either breast.

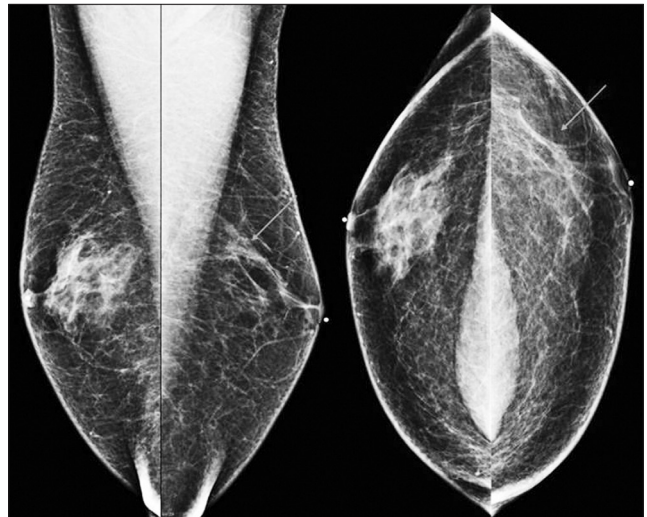
An ultrasound examination of both breasts was performed utilizing a 12 MHz transducer (Toshiba Alplio MX). The area of pain and retroareolar density in the right breast seen on mammogram corresponded to vague heterogeneous glandular tissue, consistent with gynecomastia, by ultrasound [Figure 3]. No sonographic abnormality was noted in the area of regional microcalcifications in the left breast. Normal left axillary lymph nodes were present.

The patient subsequently underwent stereotactic core biopsy (9 gauge Suros Eviva) of the suspicious microcalcifications in the left breast. Pathology results showed ductal carcinoma *in situ* grade II, with intermediate nuclear grade features in multiple core fragments [Figure 4]. Estrogen and progesterone receptors were positive. The patient was treated with left total mastectomy and sentinel lymph node biopsy, which was negative. Surgical pathology confirmed DCIS nuclear grade II (intermediate), with all surgical margins uninvolved by DCIS.

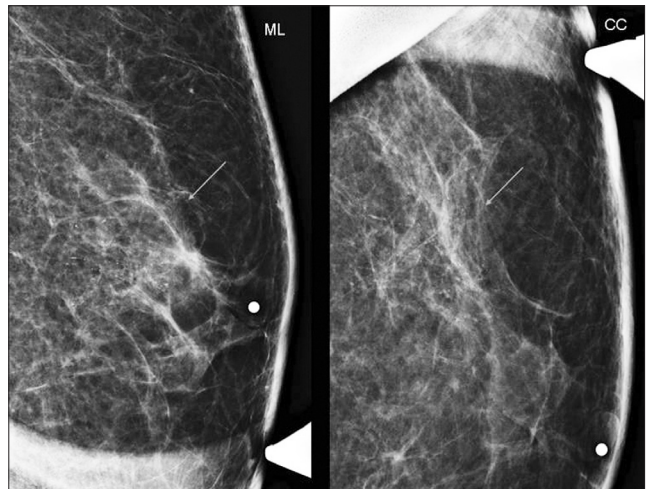
## DISCUSSION

Most cases of male DCIS present with symptoms on the affected side, such as, palpable mass or bloody nipple discharge.<sup>[1]</sup> Our case is unusual in that the patient presented with symptoms of gynecomastia in the right breast, and the cancer was an incidental finding in the asymptomatic left breast. The patient was completely asymptomatic on the left with no pain, palpable mass or nipple discharge. Other authors have reported cases of concurrent gynecomastia and DCIS in the same breast, in male patients.<sup>[2-6]</sup>

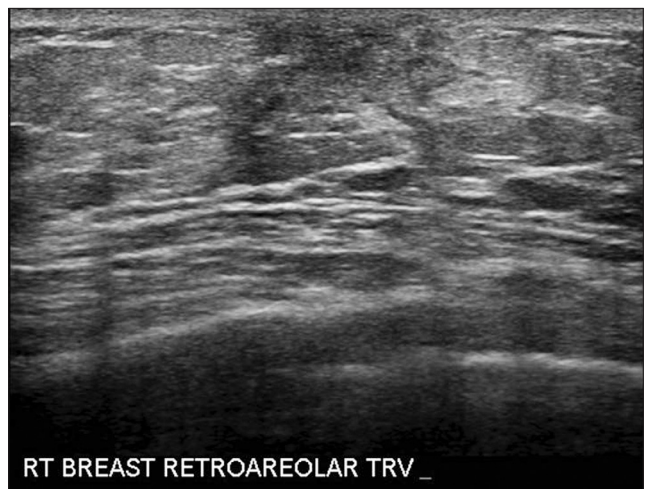Ductal carcinoma *in situ* of the male breast is rare, accounting for only about 7% of all male breast cancer cases.<sup>[1]</sup> Of all patients (male and female) with DCIS, 30 – 50% develop invasive cancer in the following 10 – 20 years, so the actual prevalence may be higher.<sup>[2]</sup> A vast majority of male



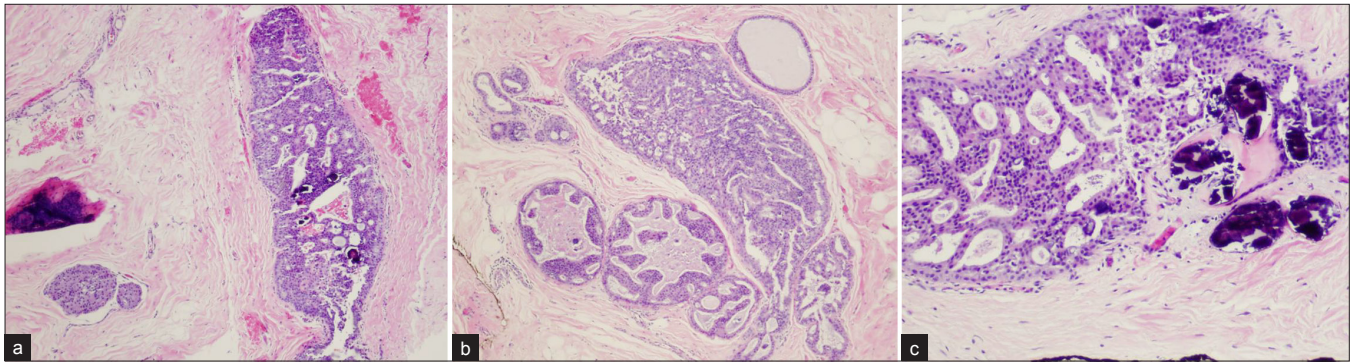
**Figure 1:** Medial lateral oblique and craniocaudal views of the bilateral breasts show flame-shaped gynecomastia of the right breast. The left breast shows microcalcifications (arrows) for which magnification views have been performed.



**Figure 2:** Medial lateral and craniocaudal magnification views of the left breast show suspicious microcalcifications in the retroareolar region extending to the upper outer quadrant (arrows).



**Figure 3:** Transverse ultrasound image of the right breast demonstrating retroareolar glandular tissue consistent with gynecomastia. No suspicious masses were identified in the right breast.



**Figure 4:** Microscopic findings. (a) Ductal carcinoma *in situ* with intraductal proliferation of small, monomorphic cells, forming secondary microlumina, with clustered microcalcifications (hematoxylin and eosin stain) (4x). (b) Punctate necrosis is present in some involved ducts (hematoxylin and eosin stain) (4x). (c) Microcalcifications are present within the ducts and stroma (hematoxylin and eosin stain) (10x).

breast cancers are ductal, and usually present late, with approximately 40% having stage III or IV disease.<sup>[4]</sup> Men are less likely than women to be diagnosed in the early stages, but diagnosis at the non-invasive stage has increased. This increase in early diagnosis may be due to improved awareness of male breast cancer. Factors that increase the risk of male breast cancer include high estrogen states, Klinefelter's syndrome, family history, *BRCA 2* gene, hyperprolactinemia, and prior radiation.<sup>[7,8]</sup> No increased breast cancer risk associated with gynecomastia in males has been found.<sup>[2,4]</sup>

The exact cause of DCIS in males is unknown, as they lack the terminal duct lobular units where DCIS often originates in women. It is hypothesized, however, that DCIS originates in the duct epithelium in men.<sup>[2]</sup> Mammography for male breast cancer has a reported sensitivity of 92% and specificity of 91%.<sup>[9]</sup> Calcifications are less frequently associated with male breast cancer than female breast cancer. Malignant calcifications in the male breast often have a more benign appearance and can be more scattered or round.<sup>[9,10]</sup>

Management of male breast cancer is largely based on studies that deal with female breast cancer. Typical treatment for males with DCIS is total mastectomy without axillary node dissection.<sup>[1,8]</sup> In a series of 31 cases of pure DCIS in men by Cutuli et al., 19 cases underwent axillary node dissection, with all sampled lymph nodes negative.<sup>[3]</sup> Recurrence of male DCIS following total mastectomy has yet to be described.<sup>[2]</sup> In the same series of 31 cases of male DCIS, Cutuli et al., described only four recurrences, none of which were in patients treated with total mastectomy.<sup>[3]</sup>

No further adjuvant therapy is necessary, and prognosis for DCIS in males is excellent.

Non-invasive breast cancers in men are symptomatic at presentation. For men, there is no standardized routine screening program for breast cancer. Our case emphasizes that the contralateral breast should also be imaged in males presenting with unilateral breast symptoms.

## REFERENCES

1. Camus MG, Joshi MG, Mackarem G, Lee AK, Rossi RL, Munson JL, et al. Ductal carcinoma in situ of the male breast. *Cancer* 1994;74:1289-93.
2. Coroneos CJ, Hamm C. Ductal carcinoma in situ in a 25-year-old man presenting with apparent unilateral gynecomastia. *Curr Oncol* 2010;17:133-7.
3. Cutuli B, Dilhuydy JM, De Lafontan B, Berlie J, Lacroze M, Lesaunier F, et al. Ductal carcinoma in situ of the male breast. Analysis of 31 cases. *Eur J Cancer* 1997; 33:35-8.
4. Fentiman I, Fourquet A, Hortobagyi GN. Male breast cancer. *Lancet* 2006;367:595-604.
5. Gunaydin G, Altundag K. Ductal carcinoma in situ and bilateral atypical ductal hyperplasia in a 23-year-old man with gynecomastia. *Am Surg* 2011;77:1272-3.
6. McCoubrey G, Fiddes R, Clarke PJ, Coleman DJ. Ductal carcinoma in situ of the male breast presenting as adolescent unilateral gynecomastia. *J Plast Reconstr Aesthet Surg* 2011;64:1684-6.
7. Niewoehner C, Schorer AB. Gynaecomastia and breast cancer in men. *BMJ* 2008;336:709-13.
8. Okada K, Kajiwara S, Tanaka H, Sakamoto G. Synchronous bilateral noninvasive ductal carcinoma of the male breast: A case report. *Breast Cancer* 2003;10:163-6.
9. Evans GF, Anthony T, Turnage RH, Schumpert TD, Levy KR, Amirkhan RH, et al. The diagnostic accuracy of mammography in the evaluation of male breast disease. *Am J Surg* 2001;181:96-100.
10. Doyle S, Steel J, Porter G. Imaging male breast cancer. *Clin Radiol* 2011;66:1079-85.

**Source of Support:** Nil, **Conflict of Interest:** None declared.