



## Cardiopulmonary Imaging Case Report

# Radiologically Occult Lung Cancer Curatively Treated with High-Dose Rate Endobronchial Brachytherapy

Deepinder Pal Singh<sup>1</sup>, Khush Aujla<sup>1</sup>, Michael Nead<sup>2</sup>, Kevin Bylund<sup>1</sup>

Departments of <sup>1</sup>Radiation Oncology, <sup>2</sup>Pulmonary Medicine, University of Rochester Medical Center, Rochester, New York, United States.



**\*Corresponding author:**  
Deepinder Pal Singh,  
Department of Radiation  
Oncology, University of  
Rochester Medical Center,  
Rochester, New York,  
United States.

deepinder\_singh@urmc.  
rochester.edu

Received : 01 July 2021  
Accepted : 07 August 2021  
Published : 23 August 2021

DOI  
10.25259/JCIS\_134\_2021

Quick Response Code:



## ABSTRACT

Most patients diagnosed with early-stage non-small cell lung cancer (NSCLC) can be easily cured with surgery or stereotactic body radiotherapy (SBRT). Modalities such as photodynamic therapy, cryotherapy, or laser therapy only offer temporary palliation. A 79-year-old gentleman with early-stage NSCLC who underwent a left lower lobe lobectomy in 2009 presented to us again in 2010 with hemoptysis. A friable ~5 cm tumor along the bifurcation of anterior and the posterior segment of the right upper lobe was noted on bronchoscopic examination, and biopsy confirmed this to be squamous cell carcinoma. Because of his previous surgery, the patient was not a candidate for another surgery. SBRT was not possible as the lesion could not be seen on radiologic imaging. The patient was, therefore, treated with curative intent high-dose rate endobronchial brachytherapy (HDR-EBBT) in 4 weekly sessions of 7 Gy per fraction delivered at a depth of 8 mm, covering ~5 cm tumor plus 1 cm margin proximally and distally. He tolerated the treatment well without any acute or late side effects and was followed every 3 months thereafter with bronchoscopy examinations for 6 months and subsequently with computerized tomography (CT) imaging. In July 2018, the patient started having episodes of hemoptysis and evaluation leads to diagnosis of a third primary lung cancer, which was successfully treated with SBRT with image-guided radiotherapy using a five-fraction regimen. The patient's most recent CT from July 2019 showed no evidence of disease. We conclude that in patients with early-stage NSCLC, when surgery or SBRT is not feasible due to radiologic occult nature, HDR-EBBT can yield excellent long-term outcome.

**Keywords:** Non-small cell lung cancer, High-dose rate endobronchial brachytherapy, Hemoptysis, Positron emission tomography nor contrast-enhanced computerized tomography, Stereotactic body radiotherapy

## INTRODUCTION

Surgical resection, when possible, is still the standard of care for early-stage non-small cell lung cancer (NSCLC), whereas stereotactic body radiotherapy (SBRT) plays a dominant role in medically inoperable patients with excellent cure rates. Invasive therapies such as radiofrequency ablation (RFA) or ablation with cryotherapy, photodynamic therapy (PDT), or laser therapy have less data supporting their use and may be more appropriate for palliative treatment.

A select subpopulation of patients with early-stage NSCLC with a purely endobronchial component may not be amenable to surgical resection, invasive ablative therapies, or SBRT.<sup>[1]</sup> Endobronchial involvement can also be seen in recurrent or metastatic lung cancers. There is some published literature discussing the use of high-dose rate endobronchial brachytherapy (HDR-EBBT) for palliation, especially when other modalities have been exhausted.<sup>[2]</sup> Utilization of HDR-EBBT for curative treatment is not universally accepted, although there are a few case

This is an open-access article distributed under the terms of the Creative Commons Attribution-Non Commercial-Share Alike 4.0 License, which allows others to remix, tweak, and build upon the work non-commercially, as long as the author is credited and the new creations are licensed under the identical terms.

©2021 Published by Scientific Scholar on behalf of Journal of Clinical Imaging Science

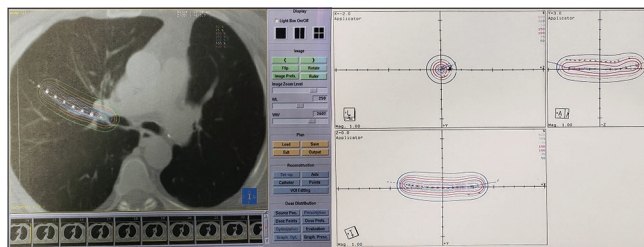
reports published using HDR-EBBT as a sole treatment for endobronchial NSCLC without nodal or visceral metastasis.<sup>[3]</sup>

We present a rare case of radiologically occult NSCLC that was not amenable to SBRT (by virtue of not being well-visualized on imaging) in a patient who was not a candidate for resection and was treated with curative intent HDR-EBBT.

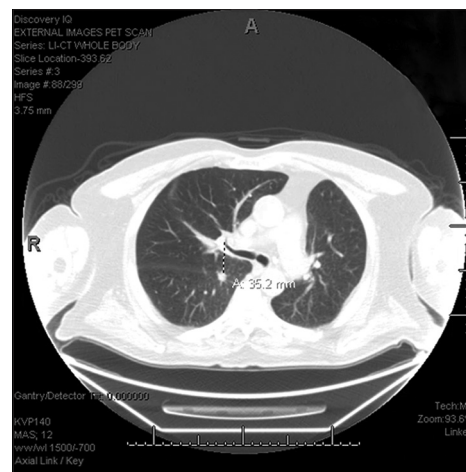
## CASE REPORT

A 79-year-old gentleman with Stage I NSCLC of the lower lobe of the left lung, who underwent lobectomy 12 months earlier, presented with new onset hemoptysis. A new friable ~5 cm tumor along the bifurcation of anterior and the posterior segments of the right upper lobe was noted on bronchoscopic examination, with features of squamous cell carcinoma (SCC) confirmed on biopsy. Positron emission tomography nor contrast-enhanced computerized tomography (PET/CT) imaging showed the newly diagnosed endobronchial cancer or any other sites of PET avid disease elsewhere. The patient now had a diffusing capacity of the lung for carbon monoxide of <40%, therefore, he was not considered a surgical candidate. SBRT was also not possible because of the radiologically occult nature of this new cancer that precluded accurate target delineation for radiotherapy.

The patient agreed to go forward with HDR-EBBT. He underwent planning CT simulation after placement of brachytherapy catheters by the pulmonologist. Dose calculation was based on the bronchoscopic evidence of extent of endobronchial disease that was ~5 cm, with 1 cm of additional length proximally and distally. After carefully evaluating the CT-based brachytherapy treatment plan, a dose of 7 Gy was prescribed at a depth of 0.8 cm from the source axis based on the adequate coverage of the mucosal lesion and without under dosing the endobronchial tumor. A total length of 7 cm was treated [Figure 1]. The patient received 4 weekly sessions, for a total of 28 Gy. CT-based planning was done for each brachytherapy session. He tolerated the treatment very well without any acute or late side effects and was followed every 3–4 months with bronchoscopy examinations for 6 months and subsequently with routine surveillance imaging. Seven and a half years later in July 2018, the patient again developed episodes of hemoptysis that warranted evaluation with EBUS which revealed no evidence of cancer or bleeding from the previously treated lesion but revealed a new 2.1 cm spiculated nodule (standard uptake value maximum of 19.3) in the right upper lobe of the lung (located in the peripheral, posterior segment close to the fissure) that was confirmed on PET/CT as well. This was located at least 3.5 cm away from the previous location of the treated endobronchial SCC [Figure 2]. Given its location, and long duration of time from his prior treatment, this was considered a third primary lung cancer, which was



**Figure 1:** Planning computerized tomography with endobronchial catheter in place with dummy seeds (right side) and the Plato dose plan in 3D showing dose distribution.



**Figure 2:** Diagnostic computerized tomography showing right lower lobe newly diagnosed non-small cell lung cancer.

successfully treated using SBRT in August 2018. His most recent CT scan in July 2019 shows no evidence of new or recurrent disease. An informed written consent was obtained from the patient for publication of his case.

## DISCUSSION

The term “radiologically occult carcinoma” has been defined by many authors in the literature as when patients with carcinoma of the bronchus have histological evidence of malignant cells in their sputum or brushing or biopsy, but demonstrate no tumor evidence on chest PET/CT imaging. Such lesions are often symptomatic. Localization of these malignancies can be challenging, though information obtained during bronchoscopy can often localize them. Surgery is often considered the standard benchmark (when comparing to other therapies) for lung cancer, including radiologically occult lung cancers. However, surgery may compromise pulmonary reserve in patients with severe COPD and/or prior lung resections.<sup>[4]</sup>

In a series by Kato *et al.*, 20 patients (for 30 lesions) out of a total of 40 patients with 45 occult carcinomas were amenable to treatment with PDT as a sole therapy. In this subgroup,

PDT resulted in 100% complete response, but recurrences developed in 3 patients (12%) with one dying of their original uncontrolled cancer (4%). Nine other patients (35%) died of unrelated causes.<sup>[5]</sup>

Sutedja *et al.* described the cases of two patients with early-stage NSCLC (cT1N0M0 SCC) treated with HDR-EBBT with a dose of 10 Gy at a 1 cm depth in three fractions (30 Gy). Both patients were alive without disease after follow-up at 54 and 25 months, respectively.<sup>[6]</sup> Tredaniel *et al.* treated 29 patients with carcinoma limited to the bronchus (radiographically occult) with HDR-EBBT; most had developed endobronchial recurrences following prior surgery, external radiation, and/or chemotherapy. A dose of 7 Gy was prescribed at a 1 cm depth for total of six fractions (total dose of 42 Gy). At the time of report writing, the median actuarial survival was not reached at 23 months of follow-up.<sup>[7]</sup> Similarly, Saito *et al.* treated 49 tumors in 41 patients who first received a dose of 40 Gy in 20 fractions using external beam radiotherapy, along with EBBT delivering a dose of 5 Gy in five fractions prescribed at 3–9 mm depth. Only 2 patients (5%) developed recurrence after a median follow-up of 24.5 months. Although the treatment was described as “low-dose rate,” it was low to intermediate range (2 Gy per hour at a 5 mm depth and >2 Gy per hour at <5 mm depths).<sup>[8]</sup> We decided to go with a dose of 7 Gy x 4 after careful evaluation of pros and cons of higher doses associated with complications.

The optimal prescribed dose of HDR-EBBT for endobronchial NSCLC is debatable. Doses that have seemed to be effective range from 10 Gy prescribed at a 1 cm depth for three fractions to a total dose of 30 Gy as used by Sutedja *et al.*<sup>[6]</sup> and Saito *et al.*,<sup>[8]</sup> to 7 Gy prescribed at 1 cm depth for six fractions to a total dose 42 Gy as used by Tredaniel *et al.*<sup>[7]</sup> Saito *et al.*<sup>[8]</sup> also used a dose of 7.5 Gy prescribed at 1 cm depth in three fractions to a total dose of 22.5 Gy. In a prospective study cohort of 320 patients who had locally advanced NSCLC with significant endobronchial involvement, Muto *et al.* compared three different HDR-EBBT regimens (10 Gy in one fraction, 14 Gy in two fractions, or 21 Gy in three fractions) that were delivered along with concomitant EBRT (60 Gy in 30 fractions). All three treatment groups achieved similar mean overall survival (11.1 months) with similar relief from symptoms, but the group experiencing the fewest number of side effects received three fractions of HDR-EBBT plus EBRT.<sup>[10]</sup> Based on our CT-based brachytherapy treatment plan, we prescribed a dose of 7 Gy x4 because of the location being a smaller caliber segmental bronchus and treating a larger length.

In the majority of the published studies, HDR-EBBT dose is prescribed at a fixed depth (1 cm from source axis or 0.5 mm from mucosa) regardless of the tumor site, as the intent is to direct the therapeutic dose to the bronchial mucosa. However, to prevent excessive dose to the mucosa and under-dosage to the endobronchial tumor, the prescription depth should be

calculated according to the diameter of the airways, using a dose point or geometric optimization. In our case, we decided to prescribe dose at 8 mm based on the isodose covering mucosal endobronchial lesion adequately and also keeping in mind that we were treating smaller caliber segmental bronchus and with 5 cm tumor length. In a series by Kawamura *et al.* who treated 16 endobronchial lesions with curative intent HDR-EBBT prescribing 5 Gy per fraction, 10 lesions received HDR-EBBT of 20 Gy along with conventionally fractionated radiation to a dose of 45 Gy, and six lesions received HDR-EBBT alone with 25 Gy prescribed at a depth of 1 cm for the trachea, 7 mm for the main stem bronchi, and 5 mm for the lobar and segmental bronchi. This study showed that 2-year local control and overall survival were 86% and 92%, respectively, with one occurrence of Grade 3 dyspnea.<sup>[9]</sup>

In an editorial, Spieser concluded that occult lung carcinomas are usually SCC histology found early as Tis or T1 disease, are less likely to occur in patients with factors considered unfavorable for NSCLC (>10% weight loss, poor performance status, and/or symptoms that predict for a lower cure/survival rate), and are often synchronous (1.2 lesions per patient) and/or metachronous (5% per year).<sup>[4]</sup> Spieser recommends preservation of pulmonary function and identification of synchronous and/or metachronous cancers. Provided that patients are treated in a prospective study, localized treatment such as PDT or EBBT is recommended for T1S, EBBT for T1/T2 disease while reserving, and surgery and/or external beam radiation for salvage.

## CONCLUSION

HDR-EBBT can be safely used for curative intent in patients not amenable for surgery or SBRT and can yield excellent long-term outcome.

## Acknowledgments

The authors thank Mrs. Laura Finger for editorial assistance. This case report was presented in abstract form at the American Brachytherapy Society Annual Meeting, June 13–15, 2019.

## Declaration of patient consent

The authors certify that they have obtained all appropriate patient consent.

## Financial support and sponsorship

Nil.

## Conflicts of interest

There are no conflicts of interest.

## REFERENCES

1. Celebioglu B, Gurkan OU, Erdogan S, Savas I, Köse K, Kurtman C, *et al.* High dose rate endobronchial brachytherapy effectively palliates symptoms due to inoperable lung cancer. *Jpn J Clin Oncol* 2002;32:443-8.
2. Reveiz L, Rueda JR, Cardona AF. Palliative endobronchial brachytherapy for non-small cell lung cancer. *Cochrane Database Syst Rev* 2012;12:CD004284.
3. Hennequin C, Bleichner O, Tredaniel J, Quero L, Sergent G, Zalcman G, *et al.* Long-term results of endobronchial brachytherapy: A curative treatment? *Int J Radiat Oncol Biol Phys* 2007;67:425-30.
4. Speiser BL. Management of occult carcinoma of lung. *Int J Radiat Oncol Biol Phys* 1996;34:1179-80.
5. Kato H, Kawate N, Kinoshita K, Yamamoto H, Furukawa K, Hayata Y. Photodynamic therapy of early-stage lung cancer. *Ciba Found Symp* 1989;146:183-94.
6. Sutedja G, Baris G, van Zandwijk N, Postmus P. High dose rate brachytherapy has a curative potential in patients with intraluminal squamous cell lung cancer. *Respiration* 1993;61:167-8.
7. Tredaniel J, Hennequin C, Zalcman G, Walter S, Homasson JP, Maylin C, *et al.* Prolonged survival after high-dose rate endobronchial radiation for malignant airway obstruction. *Chest* 1994;105:767-72.
8. Saito M, Yokoyama A, Kurita Y, Uematsu T, Miyao H, Fujimori K. Treatment of roentgenographically occult endobronchial carcinoma with external beam radiotherapy and intraluminal low-dose rate brachytherapy. *Int J Radiat Oncol Biol Phys* 1996;34:1029-35.
9. Kawamura H, Ebara T, Katoh H, Tamaki T, Ishikawa H, Sakurai H, *et al.* Long-term results of curative intraluminal high dose rate brachytherapy for endobronchial carcinoma. *Radiat Oncol* 2012;7:112.
10. Muto P, Ravo V, Panelli G, Liguori G, Fraioli G. High dose rate brachytherapy of bronchial cancer: Treatment optimization using three schemes of therapy. *Oncologist* 2000;5:209-14.

**How to cite this article:** Singh DP, Aujla K, Nead M, Bylund K. Radiologically occult lung cancer curatively treated with high-dose rate endobronchial brachytherapy. *J Clin Imaging Sci* 2021;11:45.