



Vascular and Interventional Radiology Case Report

# Percutaneous Transhepatic Holmium Laser Lithotripsy for Giant Biliary Stones

Nguyen Thai Binh<sup>1,2</sup>, Le Viet Dung<sup>1</sup>, Thieu-Thi Tra My<sup>2</sup>, Nguyen Minh Duc<sup>2,3,4</sup>

<sup>1</sup>Department of Radiology, Ha Noi Medical University Hospital, Ha Noi, Viet Nam, <sup>2</sup>Department of Radiology, Ha Noi Medical University, Ha Noi, Viet Nam, <sup>3</sup>Department of Radiology, Pham Ngoc Thach University of Medicine, Ho Chi Minh City, Viet Nam, <sup>4</sup>Department of Radiology, Children's Hospital 2, Ho Chi Minh City, Viet Nam.



**\*Corresponding author:**  
Nguyen Minh Duc,  
Department of Radiology,  
Pham Ngoc Thach University  
of Medicine, Ho Chi Minh,  
Vietnam.

[bsnguyenminhduc@pnt.edu.vn](mailto:bsnguyenminhduc@pnt.edu.vn)

Received : 19 September 2021  
Accepted : 12 October 2021  
Published : 27 October 2021

DOI  
10.25259/JCIS\_179\_2021

Quick Response Code:



## ABSTRACT

This case report describes a young female patient with a history of surgery to treat choledochal cyst since childhood who was admitted to our hospital with cholangitis. An imaging examination revealed giant stones that almost completely filled the intrahepatic biliary tract. The patient underwent percutaneous transhepatic lithotripsy using a holmium laser. After the lithotripsy, cholangiography showed no residual stones. The patient displayed clinical improvement and was discharged after 14 days in the hospital. This case serves as a reminder of gallstone complications that can occur subsequent to choledochal cyst surgery with biliary-enteric anastomosis and emphasizes many outstanding advantages of percutaneous transhepatic lithotripsy compared with classical surgery.

**Keywords:** Hepatolithiasis, Choledochal cyst, Percutaneous transhepatic lithotripsy, Holmium laser, Biliary stone

## INTRODUCTION

Cholelithiasis is relatively common,<sup>[1]</sup> and the development of hepatolithiasis following hepaticojejunostomy is not uncommon.<sup>[2,3]</sup> However, treatment can be challenging. Surgery is the classical treatment modality but has many disadvantages, including invasiveness, bleeding risk, and a relatively high rate of stone recurrence. In addition, surgery cannot be performed in some older patients or patients with contraindications to anesthesia.<sup>[4]</sup> Percutaneous transhepatic lithotripsy is a minimally invasive intervention with many advantages relative to surgery.<sup>[5-7]</sup> We report a patient with a history of choledochal cyst surgery who presented with hepatolithiasis and was successfully treated by lithotripsy.

## CASE REPORT

A 30-year-old woman was admitted to our hospital with symptoms of the right upper quadrant pain and fever. The patient had a history of choledochal cyst surgery at 4 years of age (cyst excision and hepaticojejunostomy) and was surgically treated for intrahepatic biliary stone at the age of 20. Clinical examination showed infection syndrome and emaciated body status. Blood tests showed infection status (white blood cells, 16 G/l; neutrophils, 91%; and C-reactive protein, 8.5 mg/dl), with a slight increase in serum transaminases (aspartate aminotransferase 64 U/l; and alanine aminotransferase 83 U/l), and total bilirubin of 17 μmol/l. The patient

This is an open-access article distributed under the terms of the Creative Commons Attribution-Non Commercial-Share Alike 4.0 License, which allows others to remix, tweak, and build upon the work non-commercially, as long as the author is credited and the new creations are licensed under the identical terms.

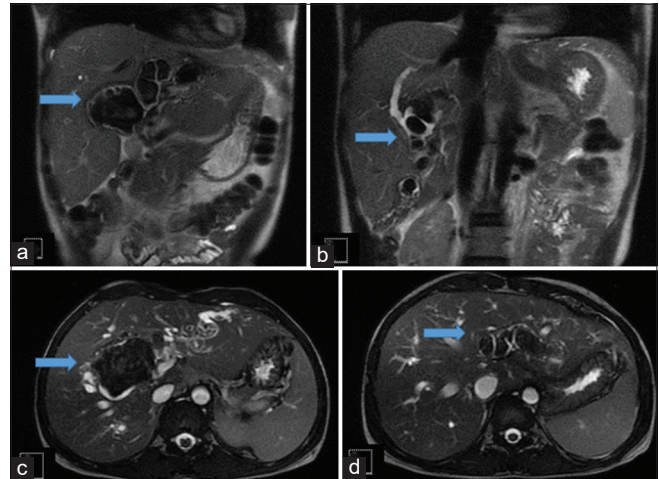
©2021 Published by Scientific Scholar on behalf of Journal of Clinical Imaging Science

was negative for hepatitis B and C viruses, with high cancer antigen 19-9 (CA 19-9; 185 U/l, reference threshold <35 U/l). Abdominal ultrasonography revealed multiple stones filling the intrahepatic biliary tract. Magnetic resonance cholangiopancreatography revealed hepatomegaly, mild cirrhosis, and bilateral, irregular intrahepatic biliary tract dilation resembling Type IVa choledochal cyst, with many framing stones filling the biliary branches [Figure 1]. The diameter of stones ranged from 3 to 60 mm. The biliary wall was mildly thickened, with enhancement in the form of cholangitis. No tumors or abscesses were found, and no peritoneal or pleural fluid was observed.

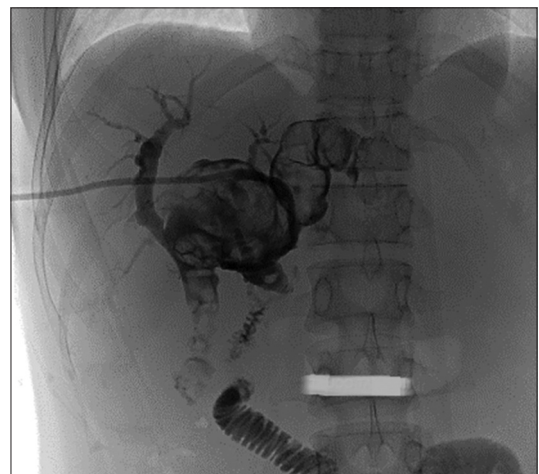
The diagnosis was cholangitis due to recurrent biliary stones and postsurgical choledochal cyst. A multi-specialty board consultation selected holmium laser percutaneous transhepatic lithotripsy as the preferred treatment. After 3 days of intravenous antibiotics to control infection, the patient underwent biliary drainage, guided by ultrasound and digital subtraction angiography. To release the biliary obstruction, a tunnel was created through the skin of the abdominal wall to the biliary tract. We placed an 8.5 Fr catheter (Bioteq, Taiwan) in the anterior segment of the right hepatic duct for drainage. Imaging revealed very large stones [Figure 2]. 3 days later, a lithotripsy procedure was performed. Our technique requires 16 Fr sheath passing to perform the procedure; therefore, we used an Amplatz dilater to stretch the biliary tract to allow the placement of the 16 Fr sheath (Terumo, Japan) entrance. Cholangioscopy revealed stones filling the intrahepatic bile ducts, and the biliary wall appeared mildly edematous due to inflammation. No biliary mucosal lesions were found suggestive of cholangiocarcinoma. The holmium laser tip (Accu Tech, USA) was guided to the stone position to conduct the lithotripsy [Figure 3]. During this procedure, the patient received intravenous analgesia and pre-anesthesia. After 3 h, approximately 80% of the gallstones had been removed. The remaining gallstones were in the VI segment, which was difficult to access using the selected entry path; therefore, we opted to stop the procedure. Two days later, the patient underwent a second lithotripsy, with direct access through an entrance placed on the biliary VI segment. The procedure was successful, and cholangiography verified the absence of residual stones [Figure 4]. Following the procedure, the patient remained stable, and the biliary drainage remained free of blood. The patient underwent cholangiography before discharge on day 10, which revealed no evidence of residual stones or blood in the biliary tract, no bile leak, and good transit via the hepaticojejunostomy.

## DISCUSSION

A choledochal cyst is an uncommon but not rare cystic dilatation of the intrahepatic or extrahepatic biliary tract,

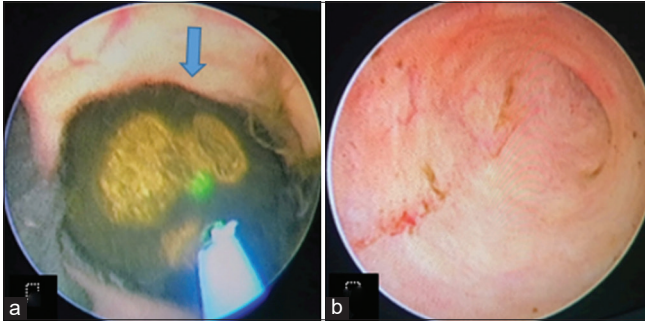


**Figure 1:** A 30-year-old woman with symptoms of the right upper quadrant pain and fever. The diagnosis was cholangitis due to recurrent biliary stones and postsurgical choledochal cyst. Coronal T2-weighted images show a large biliary stone (arrow) (a) and some small biliary stones (arrow) (b). Axial T2-weighted images show a large biliary stone (arrow) (c) and some small biliary stones (arrow) (d) which frame huge dilations of the intrahepatic biliary ducts.

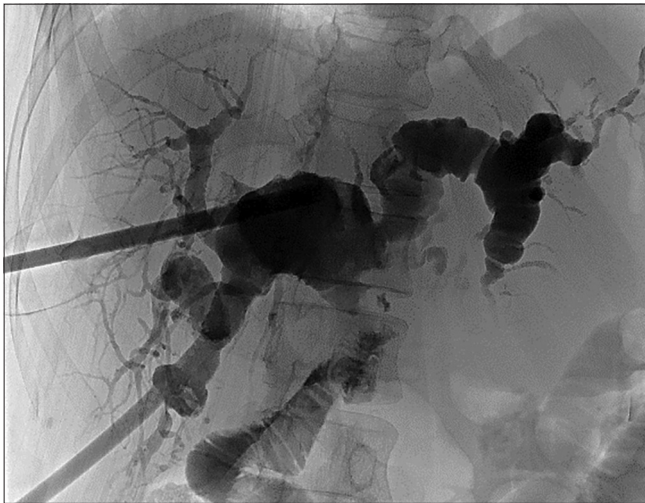


**Figure 2:** A 30-year-old woman with symptoms of the right upper quadrant pain and fever. The diagnosis was cholangitis due to recurrent biliary stones and postsurgical choledochal cyst. Single-shot digital subtraction angiography before lithotripsy reveals a giant hepatolithiasis. The patient underwent hepaticojejunostomy during a prior choledochal cyst surgery.

with an incidence of 1 in 100,000 population in Western countries; however, choledochal cysts are more common in Asian countries than in Western countries and occur more frequently in women than in men.<sup>[8]</sup> The underlying pathophysiology is not well understood, although several hypotheses have been proposed, including the narrowing of the lower segment of the common bile duct during fetal development, resulting in increased biliary pressure causing the dilatation of the upper bile duct. Another hypothesis is that



**Figure 3:** A 30-year-old woman with symptoms of the right upper quadrant pain and fever. The diagnosis was cholangitis due to recurrent biliary stones and postsurgical choledochal cyst. Image of cholangioscopy before (a) and after (b) lithotripsy (arrow in a: Biliary stone).



**Figure 4:** A 30-year-old woman with symptoms of the right upper quadrant pain and fever. The diagnosis was cholangitis due to recurrent biliary stones and postsurgical choledochal cyst. Single-shot digital subtraction angiography after lithotripsy confirmed the disappearance of the hepatolithiasis.

abnormalities of the pancreato-biliary common canal cause biliary reflux, resulting in increased pressure, inflammation, and the weakening of the biliary wall, leading to the gradual formation of cystic dilatation in the biliary tree.<sup>[9]</sup> The most common classification system for choledochal cyst was introduced by Todani *et al.* in 1979 as a modification of the system described by Alonso-Leij.<sup>[10]</sup> Type I is characterized by hepatic and common bile duct dilatation (40–85%). Type II is characterized by the formation of diverticula from the common bile duct (2–3%). Type III is characterized by the intraduodenal dilatation of the common bile duct (1.4–5.6%). Type IV, the second most common type (18–20%), is characterized by dilatation at many sites; Type IV B indicates extrahepatic biliary tract dilatation alone, whereas the presence of associated intrahepatic biliary dilatation is classified as

Type IV A.<sup>[8,10]</sup> Type V is characterized by intrahepatic bile duct dilatation (rare) and is also known as Caroli disease. Without treatment, 20–50% of patients with choledochal cysts will develop cholangiocarcinoma.<sup>[8,10]</sup>

Type I choledochal cysts with chronic cholangitis might lead to stricture and the formation of bile duct stones, causing intrahepatic biliary dilatation, which is difficult to distinguish from Type IVa choledochal cyst.<sup>[11]</sup> The most common treatment method is cyst resection and hepaticojejunostomy.<sup>[12]</sup> However, the cystic dilatation of intrahepatic bile ducts cannot be completely resolved without liver transplantation; therefore, complications can develop after surgery, including biliary stones, cholangitis recurrence, biliary cirrhosis, and cholangiocarcinoma,<sup>[2,12,13]</sup> in addition to other complications, such as bile leak, pancreatitis, or stricture of the biliary-enteric anastomosis.<sup>[12,13]</sup> Over a 13-year period, Lal *et al.* reviewed 105 surgically-treated choledochal cysts, of which Type I was the most common, representing 65% of all cases. Type IV accounted for 35% of cases, with Type IVa accounting for 33%.<sup>[11]</sup> In this study, 51% of Type IVa patients presented with biliary stones.<sup>[11]</sup> In another study from the Johns Hopkins Hospital, which followed 92 patients with choledochal cysts for 30 years, up to 58% of patients developed biliary stones.<sup>[9]</sup> According to Tsuchida *et al.*, intrahepatic biliary stones can occur in patients with choledochal cyst even without biliary stricture.<sup>[14]</sup> Studies report that intrahepatic biliary stones and hepaticojejunostomy stenosis most commonly develop in Type IVa cases.<sup>[2,3,12,15]</sup> Cho *et al.* studied 204 patients with surgically-treated choledochal cysts and reported that 174 patients experienced late complications after surgery; Type IVa cases experienced more complications, including intrahepatic biliary stones (20%) and recurrent cholangitis (21%) than other types.<sup>[16]</sup>

Biliary stones are common in Vietnam and other countries worldwide and are associated with many serious, life-threatening complications, such as biliary tract infection, acute pancreatitis, and cholangiocarcinoma.<sup>[1]</sup> Biliary stone formation is associated with infections and parasites in the biliary tract.<sup>[1]</sup> Based on the chemical composition, biliary stones can be divided into three types: Cholesterol, pigment, and mixed stones.<sup>[17]</sup> The stones are primarily composed of calcium bilirubinate.<sup>[17]</sup> Intrahepatic stones can present as clusters of stones or frame the base of the biliary tract, causing liver function decline and liver morphology changes, and can be difficult to treat.<sup>[17]</sup> The high rate of intrahepatic stone development can result in many difficulties during treatment, including a high rate of failure to remove all stones during surgery, leading to recurrence.<sup>[4]</sup> Many advances have been made in the treatment of biliary stones, including new techniques for treatment. Endoscopic retrograde cholangiopancreatography (ERCP) can be used to treat

cases associated with common bile duct stones; however, ERCP cannot be used to address large or intrahepatic stones or in patients with anatomical abnormalities in the Oddi region or who have undergone gastrectomy with Roux-en-Y anastomosis.<sup>[6,18]</sup> Liver resection is also limited to cases of bilateral intrahepatic stones or stones in many biliary branches in the right hepatic lobe.<sup>[4]</sup>

In 1985, Sauerbruch *et al.* performed the first extracorporeal lithotripsy.<sup>[19]</sup> Initially, lithotripsy was only indicated for gallstones but is now recommended for biliary tract stones.<sup>[19]</sup> Lithotripsy can use many types of energy, including ultrasonic, electro-hydraulic, piezoelectricity, and electromagnetic waves.<sup>[20]</sup> The holmium laser, which was first used in urology more than 30 years ago, is a small contact lithotrite (200–1000 mm) that effectively breaks up urinary stones with minimal stone retropulsion or subsequent collateral damage to the surrounding tissue.<sup>[6]</sup> This technique has several important advantages: Suitability for lithotripsy; flexibility due to the structures of thin and soft fibers, reduced energy loss; and favorable safety with minimal tissue damage due to the relatively high absorption coefficient of the holmium laser in water.<sup>[6]</sup> Lithotripsy is also suitable for patients who refuse or are unable to undergo general anesthesia. During lithotripsy, the laser can be used to fragment stones while minimizing both stone retropulsion and the surrounding soft-tissue damage.<sup>[5]</sup> Several studies have confirmed the usefulness, high efficiency, and safety of holmium laser lithotripsy for the treatment of difficult biliary calculi.<sup>[5-7,18]</sup> Patel *et al.* used a holmium laser in 69 patients with choledocholithiasis, and the biliary stones were successfully removed in 67 patients, with a complication rate of 4.1%.<sup>[5]</sup> Shamamian and Grasso reported a series of 36 patients with complex intrahepatic biliary calculi, including 22 treated with percutaneous endoscopic holmium laser lithotripsy.<sup>[7]</sup> Complete stone clearance was accomplished in all patients, with no major complications, and no patient required open bile duct exploration or hepatic resection.<sup>[7]</sup>

Ieradi performed lithotripsy on the same day as drainage positioning.<sup>[6]</sup> In our procedure, the maturation of the tract is not mandatory (we can perform lithotripsy on the same day or after 3 days of biliary drainage, depending on each case), in contrast with the recommendation of Shamamian and Grasso, who advised waiting 4–6 weeks between the biliary drainage procedure and lithotripsy.<sup>[7]</sup>

In our clinical case, the lithotripsy procedure was favorable, and the intrahepatic stones were completely and successfully removed, despite the presence of enormous stones. The patient was discharged under stable condition. However, in this patient, continued follow-up remains necessary due to the risk of recurrent biliary stone formation and cholangiocarcinoma.

## CONCLUSION

Hepatoolithiasis complications after choledochal cyst surgery are quite common and tend to recur. Percutaneous transhepatic holmium laser lithotripsy, in our experience, represents a minimally invasive and safe approach, accompanied by a high success rate, minimal morbidity, and a short hospital stay. Holmium laser lithotripsy can be a reasonable and safe alternative for many patients, and the interventional radiologist plays an active role in determining how to treat these cases.

## Author's contributions

Nguyen TB and Le VD contributed equally to this article as co-first authors. Nguyen TB and Le VD: Case file retrieval and case summary preparation. Le VD and Nguyen MD: Case summary preparation and preparation of manuscript and editing. All authors read and approved the final manuscript.

## Availability of data and materials

Data and materials used and/or analyzed during the current study is available from the corresponding author on reasonable request.

## Ethics approval and consent to participate

Our institution does not require ethical approval for reporting individual cases or case series.

## Declaration of patient consent

Patient's consent not required as patients identity is not disclosed or compromised.

## Financial support and sponsorship

Nil.

## Conflicts of interest

There are no conflicts of interest.

## REFERENCES

1. Sherlock S, Dooley J. Diseases of the Liver and Biliary System. Hoboken, New Jersey: John Wiley and Sons; 2008. p. 725.
2. Kassem MI, El-Haddad HM, Elriwini MT. Surgical outcome of choledochal cysts in adults: A prospective cohort study. *Egypt J Surg* 2017;36:274.
3. Koshinaga T, Inoue M, Ohashi K, Sugito K, Ikeda T, Hagiwara N, *et al.* Persistent biliary dilatation and stenosis in postoperative congenital choledochal cyst. *J Hepatobiliary Pancreat Sci* 2011;18:47-52.
4. Lorio E, Patel P, Rosenkranz L, Patel S, Sayana H. Management

- of hepatolithiasis: Review of the literature. *Curr Gastroenterol Rep* 2020;22:30.
5. Patel SN, Rosenkranz L, Hooks B, Tarnasky PR, Raijman I, Fishman DS, *et al.* Holmium-yttrium aluminum garnet laser lithotripsy in the treatment of biliary calculi using single-operator cholangioscopy: A multicenter experience (with video). *Gastrointest Endosc* 2014;79:344-8.
  6. Ierardi AM, Fontana F, Petrillo M, Floridi C, Coccozza E, Segato S, *et al.* Percutaneous transhepatic endoscopic holmium laser lithotripsy for intrahepatic and choledochal biliary stones. *Int J Surg* 2013;11 Suppl 1:S36-9.
  7. Shamamian P, Grasso M. Management of complex biliary tract calculi with a holmium laser. *J Gastrointest Surg* 2004;8:191-9.
  8. de Vries JS, de Vries S, Aronson DC, Bosman DK, Rauws EA, Bosma A, *et al.* Choledochal cysts: Age of presentation, symptoms, and late complications related to Todani's classification. *J Pediatr Surg* 2002;37:1568-73.
  9. Edil BH, Cameron JL, Reddy S, Lum Y, Lipsett PA, Nathan H, *et al.* Choledochal cyst disease in children and adults: A 30-year single-institution experience. *J Am Coll Surg* 2008;206:1000-5.
  10. Todani T, Watanabe Y, Narusue M, Tabuchi K, Okajima K. Congenital bile duct cysts: Classification, operative procedures, and review of thirty-seven cases including cancer arising from choledochal cyst. *Am J Surg* 1977;134:263-9.
  11. Lal R, Agarwal S, Shivhare R, Kumar A, Sikora SS, Saxena R, *et al.* Type IV-A choledochal cysts: A challenge. *J Hepatobiliary Pancreat Surg* 2005;12:129-34.
  12. She WH, Chung HY, Lan LC, Wong KK, Saing H, Tam PK. Management of choledochal cyst: 30 years of experience and results in a single center. *J Pediatr Surg* 2009;44:2307-11.
  13. Soares KC, Arnaoutakis DJ, Kamel I, Rastegar N, Anders R, Maithel S, *et al.* Choledochal cysts: Presentation, clinical differentiation, and management. *J Am Coll Surg* 2014;219:1167-80.
  14. Tsuchida Y, Takahashi A, Suzuki N, Kuroiwa M, Murai H, Toki F, *et al.* Development of intrahepatic biliary stones after excision of choledochal cysts. *J Pediatr Surg* 2002;37:165-7.
  15. Urushihara N, Fukumoto K, Fukuzawa H, Tani M, Matsuoka T, Suzuki K, *et al.* Hepaticojejunostomy and intrahepatic cystojejunostomy for type IV-A choledochal cyst. *J Pediatr Surg* 2007;42:1753-6.
  16. Cho MJ, Hwang S, Lee YJ, Kim KH, Ahn CS, Moon DB, *et al.* Surgical experience of 204 cases of adult choledochal cyst disease over 14 years. *World J Surg* 2011;35:1094-02.
  17. Tazuma S. Gallstone disease: Epidemiology, pathogenesis, and classification of biliary stones (common bile duct and intrahepatic). *Best Pract Res Clin Gastroenterol* 2006;20:1075-83.
  18. Deal AK, Murthy S, Wason S, Vingan H, Fabrizio M. Percutaneous transhepatic holmium laser lithotripsy of a large common bile duct stone. *Radiol Case Rep* 2016;11:361-4.
  19. Sauerbruch T, Holl J, Sackmann M, Paumgartner G. Fragmentation of bile duct stones by extracorporeal shock-wave lithotripsy: A five-year experience. *Hepatology* 1992;15:208-14.
  20. Wess OJ. Physics and technique of shock wave lithotripsy (SWL). In: Talati JJ, Tiselius HG, Albala DM, Ye Z, editors. *Urolithiasis: Basic Science and Clinical Practice*. London: Springer; 2012. p. 301-11.

**How to cite this article:** Binh NT, Dung LV, My TTT, Duc NM. Percutaneous Transhepatic Holmium Laser Lithotripsy for Giant Biliary Stones. *J Clin Imaging Sci* 2021;11:55.